Domoic Acid Toxicity in California Sea Lions (*Zalophus californianus*) Stranded Along the Central California Coast, May-October 1998

Report to the National Marine Fisheries Service Working Group on Unusual Marine Mammal Mortality Events

Frances Gulland

U.S. Department of Commerce
National Oceanic and Atmospheric Administration
National Marine Fisheries Service

NOAA Technical Memorandum NMFS-OPR-17A
Participant copy with appendices
December 2000

This technical memorandum series is used for documentation and timely communication of preliminary results, interim reports, or similar special-purpose information. Although the memoranda are not subject to complete formal review, editorial control, or detailed editing, they are expected to reflect sound professional work. The views and conclusions expressed by the authors are not necessarily those of the National Marine Fisheries Service. In addition, the mention of trade names or commercial firms is for information only and does not imply endorsement by the National Marine Fisheries Service.

In response to large numbers of California sea lions washing ashore dead and in obvious physical distress, individuals from the Marine Mammal Center, other stranding network participants, National Marine Fisheries Service, as well as numerous other State and Federal partners, were called into action to give aid to the animals and determine the cause of the event. In the course of this mortality event, many individuals with expertise in various disciplines contributed their efforts and insight into the initial response, sample collection, and final analyses. The results of their investigations are in this report. This report was prepared by the Marine Mammal Center under contract 40AAND801390.

Suggested citation:

Gulland, F. 2000. Domoic acid toxicity in California sea lions (*Zalophus californianus*) stranded along the central California coast, May–October 1998. Report to the National Marine Fisheries Service Working Group on Unusual Marine Mammal Mortality Events. U.S. Dep. Commer., NOAA Tech. Memo. NMFS-OPR-17, 45 p.

Domoic Acid Toxicity in California Sea Lions (*Zalophus californianus*) Stranded Along the Central California Coast, May-October 1998

Report to the National Marine Fisheries Service Working Group on Unusual Marine Mammal Mortality Events

Frances Gulland
The Marine Mammal Center
1065 Ft Cronkhite
Sausalito, CA 94965

NOAA Technical Memorandum
NMFS-OPR-17A
Participant copy with appendices
December 2000

U.S. Department of Commerce
Norman Y. Mineta, Secretary

National Oceanic and Atmospheric Administration
D. James Baker, Under Secretary for Oceans and Atmosphere

National Marine Fisheries Service
Penelope D. Dalton, Assistant Administrator for Fisheries

TABLE OF CONTENTS

Expert Team of Investigators	1
Abstract	3
Introduction	5
Epidemiology	5
Clinical Signs	12
Clinical Pathology	13
Treatment	14
Gross *Post Mortem* Findings	14
Microbiology	15
Histopathology	16
Toxicology	19
Plankton Bloom	24
Diagnosis	28
Post Release Monitoring	28
Discussion	30
Acknowledgments	31
References	32
List of terms	35

APPENDICES

Appendix 1. Accession numbers, names, stranding site and date, age and disposition of animals stranding during the unusual mortality event.	
1a Animals that died during the event	37
1b Animals that survived and were released	39
Appendix 2. Clinical hematology and chemistries of stranded animals	
2a. Hematology	40
2b Hematology	41
2c Blood chemistries	42
Appendix 3. Hematology and chemistries, pre-release	43
Appendix 4. Neuroclinical examination sheet	45
Appendix 5. Gross necropsy reports	47
Appendix 6. Histopathology reports	123
Appendix 7. Location of Frozen Samples	299

EXPERT TEAM OF INVESTIGATORS

A multi-disciplinary team of experts participated in response, data collection, and analyses of this mortality event. They are listed by their area of expertise.

Veterinary Medicine and Pathology

Frances Gulland
The Marine Mammal Center
Marin Headlands
Sausalito, CA 94965

Marty Haulena
The Marine Mammal Center
Marin Headlands
Sausalito, CA 94965

Tom Lipscomb
Armed Forces Institute of Pathology
Veterinary Pathology
Washington DC 20306-6000

Linda J. Lowenstine
Department of Veterinary Pathology,
Microbiology and Immunology
University of California at Davis
Davis, CA 95616

Teri Rowles
National Marine Fisheries Service
1315 East West Highway
Silver Spring, MD 20910

Terry Spraker
Colorado State University
College of Veterinary Medicine
Fort Collins, CO 80523

Toxicology

Mark Busman
Marine Biotoxins Program
NOAA/National Oceanic Service
Center for Coastal Environmental Health and
Biomolecular Research
219 Fort Johnson Road
Charleston, SC 29412

Greg Doucette
Marine Biotoxins Program
NOAA/National Oceanic Service
Center for Coastal Environmental Health and
Biomolecular Research
219 Ft Johnson Road
Charleston, SC 29412

Greg Langlois
California Department of Health Services
2151 Berkeley Way
Berkeley, CA 94704-1011

Christine Powell
Marine Biotoxins Program/
NOAA/National Oceanic Service
Center for Coastal Environmental Health and
Biomolecular Research
219 Fort Johnson Road
Charleston, SC 29412

Chris Scholin
Monterey Bay Aquarium Research Institute
P.O. Box 628
Moss Landing
Monterey, CA 95039

Vera Trainer
Marine Biotoxin Group
NOAA/NMFS/ECD
2725 Montlake Blvd.
Seattle, WA 98112

Fran Van Dolah
Marine Biotoxins Program
NOAA/National Ocenaic Service
Center for Coastal Environmental Health and
Biomolecular Research
219 Fort Johnson Road
Charleston, SC 29412

Kathy Lefebvre
Institute of Marine Science
University of Santa Cruz
Santa Cruz, CA 95064

Pinniped Biology and Management

Joe Cordaro
National Marine Fisheries Service
Southwest Region
501 West Ocean Boulevard, Suite 4200
Long Beach, CA 90802-4213

Robert DeLong
National Marine Mammal Laboratory
7600 Sand Point Way
Seattle, WA 98115-0070

Jim Harvey
Moss Landing Marine Laboratories
P.O. Box 450
Moss Landing, CA 95039

William McLellan
Biological Sciences
University of North Caroline, Wilmington
Wilmington, NC 28403

Teri Rowles
National Marine Fisheries Service
1315 East West Highway
Silver Spring, MD 20910

Epidemiology

Scott Benson
Moss Landing Marine Laboratories
P. 0. Box 450
Moss Landing, CA 95039

Andrew DeVogelaere
Monterey Bay National Marine Sanctuary
299 Foam St.
Monterey, CA 93940

L. Grella
Gulf of the Farallones National Marine Sanctuary
San Francisco, CA 94123

Jan Mortenson
Farallones Marine Sanctuary Association
P.O. Box 29386
San Francisco, CA 94129

Jan Roletto
Farallon Islands National Marine Sanctuary
Ft Mason Bldg. 201
San Francisco, CA 94123

ABSTRACT

Between May 15 and June 19, 1998, 70 California sea lions (*Zalophus californianus*) and one northern fur seal (*Callorhinus ursinus*) stranded along the central California coast from San Luis Obispo to San Mateo County. Of these 70 animals, 54 were adult females, with 27 (50 %) pregnant; three were subadult females; two were juvenile females; one was a yearling female; six were subadult males and four were juvenile males (Appendix 1). All animals were in good nutritional condition and displayed similar clinical signs that were predominantly neurological. The animals had severe seizures that either became increasingly frequent, resulting in opisthotonus, then death, or became less frequent with the animals showing ataxia and decreased responsiveness to stimuli between seizures and eventually becoming clinically normal. Forty-eight of the 70 animals (69 %) died despite treatment.

Treatment consisted of supportive care with oral and subcutaneous fluids, antibiotic cover with penicillin, control of seizures using diazepam, lorazepam, and phenobarbitone, and reduction of cerebral edema using dexamethasone. Induction of parturition using dexamethasone and prostaglandin F2α was attempted in adult females with open cervices and dead intrauterine fetuses.

Hematological parameters in these stranded sea lions were within normal limits, as were serum biochemical profiles other than creatine kinase levels. The creatine kinase levels were elevated in most animals, presumably as a consequence of muscular damage during seizures. Levels of blood lead were normal in the eight affected animals tested, and brain cholinesterase levels were normal in the five affected animals tested.

Virus neutralization (VN) tests for phocine distemper virus (PDV) detected low levels of antibody in 10 of 34 animals (29 %). After two weeks, four of these 10 animals showed low positive, but rising, titers on VN. No signs of respiratory disease or novel neurologic signs were detected. After a further month, these four animals were seronegative to PDV. Three animals that had been in contact with seropositive animals remained seronegative. A retrospective survey of banked sera from 100 adult California sea lions that had stranded previously revealed that 20 % had low titers to PDV.

A variety of non-specific lesions were observed on gross *post mortem* examination. These included gastric ulceration and erosion with associated lymphadenopathy, bile stasis, pulmonary congestion and occasional subcutaneous hemorrhages. Sea lions that died within the first two days of stranding had diffusely pale myocardium with occasional focal areas of severe pallor. All pregnant females had necrotic placentae and dead fetuses.

Bacteria isolated from tissues at *post mortem* were typical of those isolated from stranded California sea lions in recent years. A novel calicivirus was isolated from myocardium of one animal (#3709).

The predominant histologic lesion in affected animals was neuronal necrosis, that was most severe in zones CA3 and CA4 of the hippocampi and the dentate gyri. There were also intramyelinic and neuropil edema and occasional foci of gliosis. In some animals that died within 48 hours of stranding, there was multifocal myocardial necrosis and inflammation.

Domoic acid, a biotoxin produced by a diatom, was detected in serum of 3 of 7 animals, urine 7 of 14 animals, and feces of 3 of 9 animals. Two of the positive fecal samples were examined by electron microscopy, and frustules of *Pseudo-nitzschia australis* were observed. No domoic acid was found in kidney, stomach washings, cerebrospinal fluid, or brain samples from affected animals. Analyses were carried out using a receptor binding assay (RBA) and High Performance Liquid Chromatography with Ultraviolet detection (HPLC/UV). HPLC / mass spectrometry (HPLC/MS and HPLC/MS/MS) carried out on a subset of samples from each tissue type provided independent confirmation of the chemical identity of the biotoxin.

A bloom of *Pseudo-nitzschia australis*

(*P.australis*) occurred in Monterey Bay during the latter half of May 1998, reaching its peak on or about May 22. The greatest concentration of *P. australis* recorded was ~200,000 cells per liter. Cells were concentrated near shore, possibly in response to nutrients of terrestrial origin brought to coastal waters by enhanced river outflow. Plankton samples were also analyzed for domoic acid using a receptor binding assay. The rise and fall of domoic acid in these samples corresponded to the rise and fall of *P. australis* observed in the plankton. Anchovies collected from the bay on May 22, 1998 had levels of domoic acid of 105.6 μg domoic acid/g tissue, whereas fish collected on June 10, 1998 had no detectable levels of domoic acid. Anchovies collected during the peak of the *P. australis* bloom that contained high amounts of domoic acid had *P. australis* frustules within their stomachs. In Monterey Bay, the bloom of *P. australis* was followed by a bloom of *P. pseudodelicatissima*. Anchovies collected from Monterey Bay reflected this change in species abundance in their stomach contents. No *P. australis* frustules or domoic acid were detected in stomach contents of these fish, and no domoic acid was detected in plankton during the *P. pseudodelicatissima* bloom.

Three of the 23 sea lions (#3815, #3822 and #3815) that survived treatment during the event in May and June 1998 were equipped with satellite and radio-transmitters prior to their release on November 15, 1998. Battery life of the satellite transmitters was three months. Satellite and re-sight data indicated that sea lions survived for at least 48, 64 and 94 days, respectively. Two sea lions traveled as far south as the Channel Islands, whereas the third sea lion remained in the vicinity of Año Nuevo Island. All three sea lions that were sighted during the three-month telemetry period appeared healthy and displayed normal behavior.

During routine surveys around the Monterey Bay during the months of May and June 1998, a 3.5 fold increase in numbers of dead beach-cast birds and pinnipeds was detected compare to the same months of the previous year. The majority of the dead birds were Common Murres, Surf Scoters and Sooty Shearwaters. Large numbers of stranded sea lions were also detected along other central California beaches at the time. The extent to which these mortalities was due to domoic acid toxicity rather than as a consequence of starvation due to El Niño conditions is unclear, since most animals were not examined.

From July 2 to October 17, 1998, an additional 11 California sea lions stranded displaying similar clinical signs to those that stranded during late May and early June. Nine of these animals stranded between October 3 and October 17. Four animals survived and seven died. The dead animals had histologic lesions similar to those in the earlier cases. Domoic acid was detected in urine of two of these animals by the microplate assay. At the same time (early October), cells of *P. australis* were observed in Monterey Bay around the Santa Cruz and Capitola piers, but were at relatively low concentrations (<10,000 cells per liter). However, further offshore (outside of Monterey Bay), concentrations of *P. australis* were in excess of 100,000 cells per liter. It is likely that the source of domoic acid affecting sea lions during October was a bloom outside of Monterey Bay.

In summary, the combination of clinical signs, histopathological, toxicological, epidemiological and oceanographic changes led to the conclusion that domoic acid toxicity was the cause of this Marine Mammal Unusual Mortality Event. Domoic acid was first reported as a cause of toxicity in humans in 1987, when four people died and approximately one hundred were clinically ill following ingestion ofcontaminated mussels on Prince Edward Island, Canada. This event is the first documented occurrence of domoic acid toxicity in marine mammals.

INTRODUCTION

Within the California Marine Mammal Stranding Network, response to stranded marine mammals is shared between a number of organizations under the direction of the NMFS Southwest Regional Stranding Coordinator, Joe Cordaro. The Marine Mammal Center (TMMC) responds to calls on live animals from San Luis Obispo County in the south to Mendocino County in the north. Calls on dead marine mammals in the same range are responded to by a number of organizations, usually a different one in each county. The type of response and extent of sampling beyond the collection of level A data varies between agencies within the California Marine Mammal Stranding Network, due to different interests of volunteer members. In El Niño years, there is typically an increase in the number of pinnipeds, especially California sea lion (*Zalophus californianus*) pups and yearlings, stranding along the central California coast (Cordaro, 1997). In late 1997 and early 1998, strandings of emaciated animals increased as predicted in association with changes in sea surface temperature and decreasing food availability. The majority of these animals were emaciated, heavily parasitized California sea lions. In May and June 1998, 334 yearling sea lions were admitted to TMMC, compared to 92 in the same months of 1997. Strandings of adults are rare, and usually a consequence of human interactions or neoplasia (Gulland *et al.*, 1996). Thus, although TMMC admitted 334 yearling California sea lions in May and June 1998, the stranding of 70 adults and subadults in good nutritional condition showing severe neurologic signs was an unusual occurrence.

EPIDEMIOLOGY

Live stranded sea lions

From May 18 to June 19, 1998, 70 California sea lions (*Zalophus californianus*) and one northern fur seal (*Callorhinus ursinus*) stranded live along the central California coast between Oceano Dunes, San Luis Obispo County in the south and Half Moon Bay, San Mateo County, in the north. This unusual mortality event has been defined by these dates. A second event of 11 sea lions showing similar signs stranded between July 12 and October 17, with nine of them stranding in the two weeks from October 3, 1998. This second mortality event will be described in the discussion section of this document.

Criteria for inclusion in this unusual mortality event were as follows. All live animals included in this study displayed severe neurologic signs, were in good nutritional condition, and showed no other clinical signs of primary traumatic diseases or chronic infectious diseases. Dead animals were included if they showed good nutritional condition and severe neurologic signs prior to death or consistent pathologic findings of neurologic lesions like those described in the following pathology section. Evidence of tumors or "normal" parasitic diseases did not exclude animals in this study if the above criteria were met. Dead animals for which there was minimal diagnostic information were not included, therefore the 70 animals identified are likely to be an underestimate of the actual numbers of animals involved.

Figure 1 shows the spatial and temporal assessment of the strandings of the animals included in this event. The majority of the animals that stranded in the first week of the mortality event stranded along Oceano Dunes. In the second week of the mortality event, animals stranded in both Monterey Bay and Oceano Dunes, and on June 14 one animal stranded north of Monterey Bay, in San Mateo County.
All live animals admitted were transported to TMMC by volunteers following calls from thepublic about animals observed in distress. No surveys for affected animals were undertaken. The distribution of stranding sites was therefore affected by the intensity of public visitation to beaches along the coast. The area between the south end of Monterey Bay and Oceano Dunes, Big Sur, is inaccessible to the public due to lack of roads along the beach, so it is unclear whether or not clinically affected sea lions stranded along this stretch of coastline.

The majority of clinically affected animals were adult females, 50% of which were pregnant (Table 1). Although juvenile animalswere of both sexes, there were no adult male sea lions affected. This may be due to sex differences in dispersal along the California coast. The majority of the other 334 California sea lions that were admitted to TMMC in May and June 1998 were emaciated yearlings of both sexes.

Sea lions (other than yearlings) were aged by counting the number of dentine annuli in longitudinal sections of the upper left canine by Dr. Sue Chivers at the South West Fisheries Science Center, La Jolla California and Dr. R. DeLong, at the National Marine Mammal Laboratory (NMML) in Seattle, Washington. Ages of tooth-aged animals are listed in Appendix 1, and ranged from 3 to 13 years.

Table 1. Age structure of total affected and number of California sea lions which stranded or survived from May 16 to June 14, 1998.

Age Class	Females, affected	Females, survived	Males, affected	Males, survived
Adult	54	12		
Subadult	3	1	6	4
Juvenile	2	2	4	2
Weanling	1			

Figure 1. Stranding sites for sea lions stranding during the Unusual Mortality event in successive time periods in 1998. Numbers of animals stranding in each time period at each site are given within the circles.

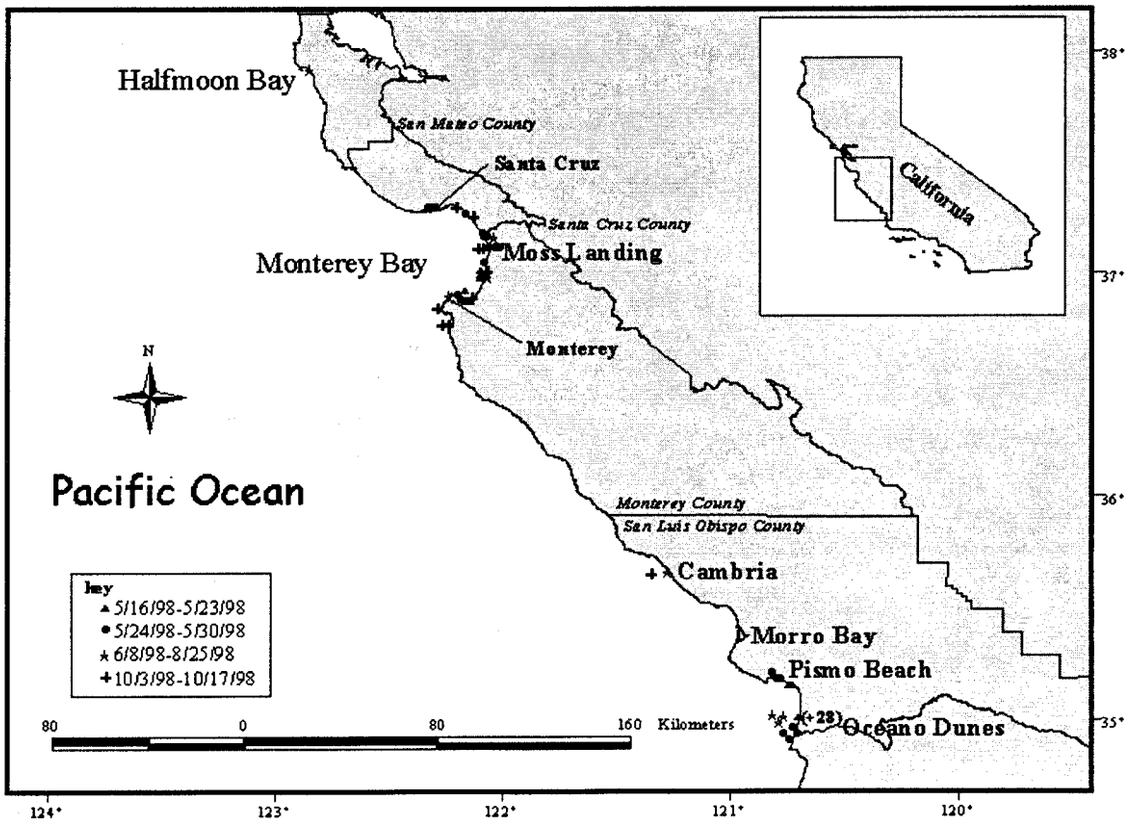

Dead stranded marine mammals and mortality of other species

Data on stranded marine birds and dead marine mammals in the Monterey Bay were collected by the Monterey Bay National Marine Sanctuary BeachCOMBER program. The monitoring plan examines the sandy beaches within Monterey Bay and Carmel Bay, divided into 10 roughly equal-length segments for sampling. Data on beach-cast birds and mammals along the sandy beaches north of Año Nuevo Island to Bodega Head, Sonoma County, were collected by the Gulf of the Farallones National Marine Sanctuary (GFNMS) Beach Watch program. Pairs of volunteers survey these pre-defined segments on a monthly basis. Surveys are conducted during the first week of each month at low tide; therefore, encountered beach-cast animals represent those deposited during the previous month. For each encountered carcass, the following information is recorded: species, stage of decomposition, age, sex, evidence of scavenging, evidence for the cause of death, the presence of oil, and whether or not a photograph was obtained. A comments section is provided for documentation of any tags present on the carcass, length measurements, photograph roll and frame numbers, or any notes that would aid in post-identification of the encountered carcass. For seabirds, a toe is clipped each month in which the carcass is encountered, allowing determination of residence times and of the number of newly deposited birds. Prior to clipping a toe, the volunteer documents the number of toes previously removed. Beach-cast marine mammals are not marked.

The results of surveys in May and June 1997 and 1998 are shown in Table 2. They refer only to newly deposited birds, defined as birds with no previously clipped toes. Total beach-cast deposition of marine birds during May and June 1998 was greater at all beaches throughout the study area compared to the same period in 1997. In GFNMS, numbers of encountered carcasses were higher than the mean for these months over the previous three years (1994-1997). The causes of this elevated deposition are not clear. Many foraging guilds seem to have been affected, and overall species diversity was greater in 1998. In particular, overwintering seabirds were more frequently found beach-cast during the May and June 1998 surveys compared to the same period in 1997 (even though May 1997 was the first survey and therefore would be expected to have higher counts because it includes deposition for >1 month). Although no comparable data exist for April 1997, deposition rates of overwintering birds for April 1998 were also high. This indicates that resource limitations (perhaps caused by El Niño) during the winter months may have been a factor contributing to elevated seabird mortality from March through early June.

Table 2. Number of Dead Marine Birds and Mammals Reported by BeachCOMBER in Monterey Bay

	May 1997		June 1997		April 1998		May 1998		June 1998	
Marine Birds	**Total**	**%**	**Total**	**%**	**Total**	**%**	**Total**	**%**	**Total**	**%**
Common Murre	83	51.2	46	32.2	83	13.3	149	26.2	239	44.2
Sooty Shearwater	12	7.4	41	28.7	15	2.4	69	12.1	110	20.3
Unidentified gull	10	6.2	10	7.0	2	0.3	5	0.9	7	1.3
Western Grebe	9	5.6	11	7.7	46	7.4	12	2.1	1	0.2
Pacific Loon	9	5.6	5	3.5	45	7.2	46	8.1	29	5.4

Marine Birds	Total	%	Total	%	Total	%	Total	%	Total	%
Western Gull	7	4.3	8	5.6	1	0.2			2	0.4
California Gull	7	4.3			1	0.2				
Brandt's Cormorant	3	1.9	3	2.1	30	4.8	13	2.3	7	1.3
Brown Pelican	2	1.2			7	1.1	1	0.2	1	0.2
Glaucous-winged Gull	2	1.2								
Heermann's Gull	2	1.2							3	0.6
Unidentified marine bird	2	1.2			1	0.2	2	0.4		
Pigeon Guillemot	1	0.6			1	0.2	18	3.2	12	2.2
Rhinoceros Auklet	1	0.6			40	6.4	16	2.8	7	1.3
Unidentified Alcid	1	0.6	1	0.7	6	1.0	3	0.5	1	0.2
Flesh-footed Shearwater	1	0.6								
Northern Fulmar	1	0.6	4	2.8	43	6.9	34	6.0	9	1.7
Unidentified Grebe	1	0.6	2	1.4	1	0.2	4	0.7	1	0.2
Arctic Loon	1	0.6								
Unidentified Loon	1	0.6	1	0.7					1	0.2
Cassin's Auklet			2	1.4	79	12.7	51	9.0	18	3.3
Double-crested Cormorant	1	0.6	1	0.7	3	0.5	1	0.2		
Brandt's/Double-breasted Cormorant	1	0.6								
unidentified Cormorant	1	0.6	1	0.7	4	0.6	2	0.4		
Surf Scoter		0.6			150	24.1	1	0.2	59	10.9
Mew Gull	1	0.6								

Marine Birds	Total	%	Total	%	Total	%	Total	%	Total	%
Red-breasted Merganser	1	0.6								
Horned Puffin			1	0.7						
Clark's/Western Grebe			1	0.7	7	1.1	12	2.1	2	0.4
California Gull			1	0.7			1	0.2	1	0.2
Common Loon					20	3.2	19	3.3	18	3.3
Unidentified Scoter					19	3.0	11	1.9	6	1.1
Herring Gull					2	0.3				
Red-throated Loon					3	0.5	1	0.2	1	0.2
Unidentified Shearwater			1	0.7	1	0.2	1	0.2	2	0.4
Pelagic Cormorant			1	0.7	4	0.6	4	0.7	1	0.2
Ancient Murrelet					1	0.2				
Clark's Grebe					1	0.2	1	0.2	1	0.2
Red-necked Grebe					1	0.2				
Bonaparte's Gull					1	0.2				
Black-legged Kittiwake					1	0.2	1	0.2		
Pomarine Jaeger					1	0.2				
Fork-tailed Storm-Petrel					1	0.2	1	0.2		
Unidentified Storm-Petrel					1	0.2	1	0.2		
Red Phalarope					1	0.2	1	0.2		
Black-footed Albatross			2	1.4						
Pink-footed Shearwater									1	0.2
Black Scoter							1	0.2		
Ashy Storm-Petrel							1	0.2		
Laysan Albatross									1	0.2

Marine Mammals	Total	%	Total	%	Total	%	Total	%	Total	%
California sea lion	19	55.9	31	59.6	16	59.3	12	36.4	83	59.7
Unidentified otariid	3	8.8	3	5.8	3	11.1	3	9.1	23	15.8
Northern elephant seal	1	2.9	0	0	0	0	2	6.1	9	6.5
Harbor seal	3	8.8	11	21.2	2	7.4	5	15.2.	12	8.6
Unidentified phocid	2	5.9	1	1.9	0	0	2	6.1	0	0
Unidentified pinniped	3	8.8	4	7.7	2	7.4	1	3.0	9	6.5
Pinniped total	31	91.2	50	96.2	23	85.2	25	75.8	136	93.8
Odontocete	1	2.9	1	1.9	1	3.7	5	15.2	4	2.9
Sea otter	2	5.9	1	1.9	3	11.1	3	9.1	5	3.6

There was a notable increase in beach-cast Common Murre (*Uria aalge*), Sooty Shearwater (*Puffinus griseus*), Surf Scoter (*Melanitta perspicillata*), Pacific Loon (*Gavia pacifica*), Common Loon (*Gavia immer*) and Cassin's Auklet (*Ptychoramphus aleuticus*) in May and June 1998 compared to the previous year. The causes for these differences are not known; however, several necropsied Surf Scotersexhibited large parasite loads (acanthocephalans). Cassin's Auklet, a small planktivore, may have been more susceptible than other species to the combination of resource limitation and severe winter storms caused by El Niño conditions. Increases in beach-cast marine birds have occurred in this area in previous El Niño events (Bodkin and Jameson 1991). However, it is possible that piscivorous Common Murre, Sooty Shearwater, Pacific Loon and Common Loon were impacted by domoic acid in sardines. By comparing live bird counts in Monterey Bay to beach-cast birdcounts, it is clear that the increased deposition was not simply an artifact of a greater number of birds in the Bay (Figure 2).

In contrast with seabirds, marine mammal carcasses could not reliably be marked at each survey, therefore, the results outlined in Table 2 and 3 include all carcasses found, regardless of residence time. Marine mammal deposition was relatively constant from March through early May of 1998, and the May 1998 count was nearly identical to the number encountered during May 1997. This pattern contrasts sharply with the results described above for seabirds. A large (4-fold) increase in the deposition of marine mammals occurred between the May 1998 and June 1998 samples, with the June 1998 sample being nearly three times higher than the June 1997 sample. The most frequently encountered species was the California sea lion(*Zalophus californianus*), comprising about 60% of all marine mammals in both years. The increase in marine mammal deposition between the months of June 1997 and June 1998 may have been caused by the unusual presence of female California sea lions in Monterey Bay during late spring/early summer. Previous studies have found a general migration northward from southern California breeding grounds during periods of resource limitation associated with El Niño (Trillmich and Ono 1991).

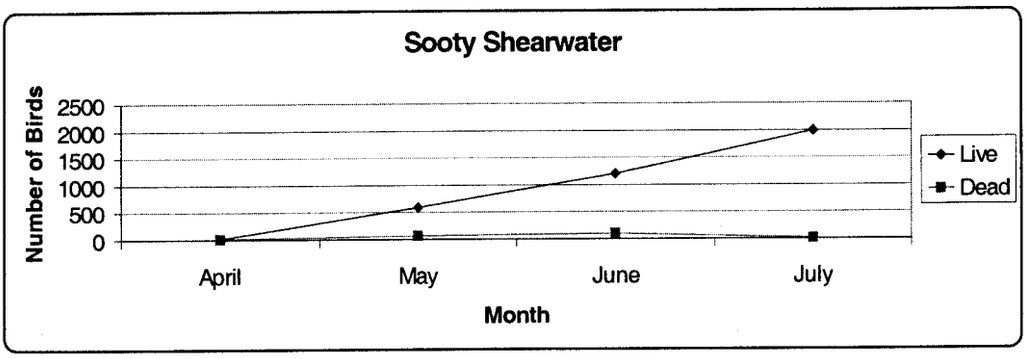

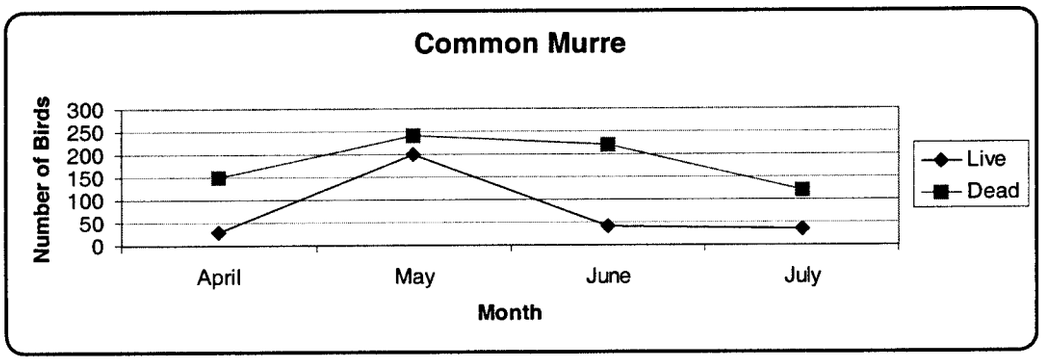

Figure 2. Counts of live and beachcast Common Murres and Sooty Shearwaters in Monterey Bay during 1998.

Table 3. Number of dead California sea lions reported to the California Marine Mammal Stranding Network in May and June 1998.

MAY 1998							
County	**Condition**	**Pup**	**Yearling**	**Subadult**	**Adult**	**Unknown**	**Total**
San Luis Obispo	Dead	0	0	0	2	6	8
	Alive	11	25	24	30	0	79
Monterey	Dead	1	3	2	1	2	9
	Alive	9	31	7	17	0	64
Santa Cruz	Dead	0	0	0	0	0	0
	Alive	0	13	4	8	0	25
San Mateo	Dead	3	6	1	3	2	15
	Alive	3	10	1	0	0	14
Total		27	88	39	61	10	214
JUNE 1998							
County	**Condition**	**Pup**	**Yearling**	**Subadult**	**Adult**	**Unknown**	**Total**
San Luis Obispo	Dead	0	0	0	2	13	15
	Alive	4	20	8	1	0	33
Monterey	Dead	12	8	12	11	3	47
	Alive	6	3[illegible]	14		0	56
Santa Cruz	Dead	-	-	-	-	-	-
	Alive	0	31	4	2	0	37
San Mateo	Dead	3	24	5	4	4	40
	Alive	3	7	3	0	0	13
Total		28	126	46	20	20	241

CLINICAL SIGNS

The characteristic clinical signs in affected sea lions were ataxia, head weaving, muscle tremors, tetanic convulsions, rubbing and lethargy. Forty-eight (69 %) of the initial 70 affected California sea lions died or were euthanized. In animals that died, seizures became increasingly frequent, often progressing to *status epilepticus* before the animal died. If animals were repeatedly in *status epilepticus* for over an hour and showed no improvement in clinical signs over subsequent days, or were comatose, they were euthanized (n=22). The seizures varied from a few minutes in duration, to over 30 minutes. The seizure duration was often affected by treatment, as seizuring sea lions were treated with diazepam, lorazepam and phenobarbitone symptomatically to alleviate tetany. Frequency of seizures varied from one to 30 in 24 hours. In animals that survived, the frequency of seizures gradually decreased over a one month period. Seizures were usually bilateral, but two animals repeatedly had unilateral seizures. Between seizures, sea lions showed varying degrees of lethargy and occasionally a characteristic rubbing behavior, in which the animals would rub the back of their necks and dorsum by rolling repeatedly on the pen floor. As assessment of the lethargy was subjective, a neurologic examination sheet (Appendix 4) was developed that could be used to give animals a numeric score. This could be evaluated daily by different personnel, and scores compared between days to determine an animal's clinical progress. A higher score would equate with a worse neurologic condition. In the first days after stranding, most animals had scores above 20. Apparently healthy animals prior to release had scores of between 7

and 10.

Other clinical signs observed included retching blood-tinged mucus, diarrhea, moist cough, and blepharospasm. Although animals retched mucus, no vomitus was observed, and on *post mortem* examination of animals that died, stomachs were empty.

Electrocardiograms were performed on three clinically affected animals both during seizures and between seizures. No abnormalities were detected.

Pathologic examination of animals that died or were euthanized during the event suggested that fetuses had died *in utero* sometimes days prior to the female's death. Ultrasonography was used to examine five animals that had distended abdomens. Of the five animals examined, all were diagnosed as pregnant, with no detectable fetal heart beat.

Magnetic resonance imagery (MRI) was used to examine the brain of one affected animal under anesthesia (# 3768) and one control animal. Although examination of histologic sections of the brain(#3768) after death revealed characteristic lesions of neuronal necrosis in the hippocampus, no lesions were detected by MRI when compared to the control animal.

CLINICAL PATHOLOGY

Blood analyses

Hematological results from affected sea lions at admission are shown in Appendix 2a. Hematocrits were elevated in many individuals, presumably as a consequence of dehydration. Three individuals (#4209, #4024 and #4220) had elevated leukocyte counts due to neutrophilia. These three animals stranded after the initial event, and all three had chronic abrasions.

The most consistent serum biochemical abnormality was an increase in creatine kinase ranging from 169 to 6,288 IU/L in animals tested (Appendix 2b). This elevation was believed to be a consequence of muscle damage during seizures and transport. Thirteen of 41 animals tested (32%) on admission had gamma-glutamyl transferase levels over 100 mg/dl. This elevation may have been due to bile stasis, as many animals on necropsy had distended gall bladders. Both hypo- (#3734) andhypernatremia (# 3901, #4217, #3719, #3815) were observed. Hyperphosphatemia was also observed in three animals (# 3734, #3806, and #3812). Two of the sea lions with hyperphosphatemia, # 3734 and # 3806, also had increased blood urea nitrogen, suggesting some of these biochemical changes could have resulted from impaired renal function. Both these animals were female and #3806 was euthanized; whereas #3734 died. Histologic examination of kidney tissue from # 3806 revealed interstitial nephritis, indicating that this clinical pathologic change was indeed a consequence of renal damage. However, no abnormalities were reported in kidney tissue from #3734.

Neurologic analyses

To rule out chemical pollutant exposure as a cause of the seizures, brain cholinesterase levels were assayed in five affected animals and control animals at California Veterinary Diagnostic Laboratory Systems (CVDLS) and were found to be normal (> 1.5 M/g/min) as compared to normal mammalian ranges. In addition, blood lead levels were examined in eight affected and control animals and were found to be below detectable limits.

Cerebrospinal fluid samples from four animals (#3837, #3794, # 3746, #3796) were spun and smears were examined after staining with Wright's stain. No inflammatory cells were observed.

Fecal analyses

Fecal samples from 18 animals were examined by Dr. R. DeLong at the National Marine Mammal Laboratory (NMML) for presence of prey species, but fish bones were only detected in samples from three sea lions. Vertebrae from anchovies (*Engraulis* spp.) were identified in 2 samples (#3801 and #3796) and probable sardine (*Sardinops sagax*) otoliths in one sample (#3760). These are common prey species of California sea lions in spring and summer (Antonelis *et al.*, 1984).

TREATMENT

Seizures were controlled symptomatically with diazepam (0.1 - 0.2 mg/kg intramuscularly (IM) or intravenously (IV) up to four times daily), or lorazepam (0.03 - 0.04 mg/kg IM up to twice a day). The latter was found to be more effective at controlling seizures. Long term control was achieved with phenobarbitone at 2 mg/kg IM initially, then orally once the sea lions recovered sufficiently to eat. Dexamethasone at 0.5 mg/kg IM was also given to reduce cerebral edema following seizures. Supportive care was achieved with subcutaneous fluids (either Ringer's or 0.9% NaCl at 60 ml/kg subcutaneously) until the animals were eating consistently. Parturition was induced in the five pregnant animals in which no fetal heart beat could be detected. Induction was performed in four animals by intramuscular injection of 500 g prostaglandin F2 (Estrumate), and in one animal by intravaginal administration of prostaglandin E (Misoprostol). The four given prostaglandin F2 gave birth to dead fetuses after 36 hours, while the one that received the drug intravaginally died within 12 hours. Post mortem examination revealed that this animal had a uterine rupture, an intra-abdominal fetus, and peritonitis of several days duration.

Two of the seizuring animals gave birth to live pups. One of the pups died within 48 hours of birth, the other did not nurse and the female showed no interest in it, so it was removed for hand-rearing. This pup did not survive.

GROSS *POST MORTEM* FINDINGS

All animals that died or were euthanized were in good nutritional condition with blubber layers over the sternum between 20 and 50 mm. The most common gross lesions observed that were considered features of the toxicity eventwere pallor of the myocardium (16/48), fibrinous plaques on the epicardium (5/48), and, more rarely, fibrinous fluid in the pericardial sac (2/48) (Table 4). These lesions were not observed in all cases, but were more frequent in sea lions that died within 48 hrs of stranding. Four animals with pallor of the myocardium had friable livers with a nutmeg pattern on the surface. Congestion of the meningeal blood vessels was observed in two cases, cerebral edema in one. Twenty three of the forty five females that died or were euthanized (51%) were peri-parturient. Placental necrosis was observed in five peri-parturient female sea lions that had not delivered a fetus prior to death. Uterine pathologies were observed in five sea lions. Two animals had uterine ruptures with intra-abdominal delivery of the fetuses, two had uterine torsions and one had a uterine prolapse that had become necrotic. Other gross lesions were those associated with parasitism - gastric ulceration and erosion and enlargement of the gastric lymph nodes (associated with *Anisakid* nematodes), cholecystitis (associated with *Zalophatrema hepaticum*) and pulmonary congestion (associated with *Parafilaroides* spp.) (Table 4). These lesions are common in animals normally stranded in this region. Enlarged tonsils were observed in 10 cases, and pus within the laryngeal pouches in two cases. Abscesses within the skeletal muscle and fascia were observed in three cases, one of which was gun-shot.

Five female sea lions had neoplasms. Two had leiomyomas of the uterus, and three had rough plaques of the vaginal mucosa that were found to be early epithelial carcinoma when examined histologically.

Table 4. Frequency of gross post mortem findings in 48 California sea lions.

Lesion	# animals
Pallor of the myocardium	16
Fibrinous fluid in the pericardial sac	2
Epicardial fibrinous plaques	5
Left atrial endocardial fibrosis	1
Friable liver, nutmeg pattern	4
Thickening of gall bladder wall	6
Atresia of common bile duct	1
Swelling of the kidneys	13
Placental necrosis	5
Uterine rupture	2
Uterine torsion	2
Prolapsed uterus	1
Uterine/vaginal neoplasia	5
Congestion of meningeal blood vessels	2
Cerebral edema	1
Keratitis/uveitis	5
Oral ulcers	6
Gastric erosions and ulcers	22
Enlarged gastric lymph nodes	5
Swollen gastric rugae	9
Blood tinged mucus in oropharynx	7
Pulmonary congestion	14
Pulmonary interstitial edema	6
Blood tinged froth in trachea and bronchi	3
Pus in laryngeal pouches	2
Abscess within muscle fascia	3 (gunshot 1)

MICROBIOLOGY

Bacteriology

A variety of bacteria were isolated from tissues of the sea lions after routine culture of swabs taken at post mortem examination (summarized in Table 5.). These bacteria species are not atypical from bacteria found in sea lions that strand along the California coast at other times (Thornton *et al.*, 1998). Uterine mucosa samples from 25 animals were submitted to National Veterinary Services Laboratory in Ames, Iowa, for Brucella isolation. All cultures were negative.

Virology

Swabs from pericardium, lung, liver and whole blood were submitted to Dr. Carol House, USDA, Plum Island, for viral isolation. A new calicivirus, designated San Miguel Sea Lion virus 18, was isolated from a pericardial swab from sea lion "Dean", #3709. This virus was identified using electron microscopy.

Virus neutralization (VN) tests for phocine distemper virus (PDV) detected low levels of antibody in sera from 10 of 34 animals (29 %). After two weeks, four of these 10 animals showed low positive, but rising, titers on VN. No signs of respiratory disease or novel neurologic signs were detected. After a further month, these four animals were seronegative to PDV. Three animals that they had been in contact with were also seronegative. A retrospective survey of banked sera from 100 adult California sea lions that had stranded previously revealed a seroprevalence of 20 % of low titers to PDV. The significance of these findings is under investigation by Drs. Carol House, USDA, Plum Island and Don King, University of California at Davis.

Table 5. Number of bacterial isolates from tissues of California sea lions at post mortem examination

Isolate	Tonsil n = 3	Laryngeal pouch n = 4	Lung n = 5	Liver n = 5	Brain n = 5	Uterus n = 3	Peri-cardium n = 2	Sub-lumbar lymph node	Gastric lymph node n = 2
Enterobacter cloacae	-	-	1	-	1	-	1	-	2
E. coli	3	4	2	2	3	1	2	-	1
Klebsiella pneumoniae	2	2	1	-	-	-	-	-	-
Aeromonas spp.	-	2	-	-	-	-	-	-	-
Proteus mirabilis	-	-	1	2	1	-	-	-	-
Edwardsiella tarda	-	-	-	2	-	-	-	-	-
Enterococcus spp.	-	-	-	2	-	1	-	-	-
Staphylococcus aureus	-	-	-	-	-	-	-	-	-
Corynebacterium spp.	-	2	-	-	-	-	-	-	-
Listeria ivanovii	-	-	1	-	-	-	-	-	1
Streptococcus viridans	1	1	-	-	-	1	-	-	-
Moraxella sp.	-	1	-	-	-	-	-	-	-
Fusobacterium sp.	-	-	-	-	-	-	-	1	
Clostridium perfringens	-	-	-	-	-	-	-	1	-
Plesiomonas shigelloides	-	-	1	1	1	-	-	-	-

HISTOPATHOLOGY

Tissues from 48 California sea lions, 4 California sea lion fetuses and one northern fur seal were examined microscopically with special emphasis on the central nervous system. Histopathology was performed at the University of California, Davis, Veterinary Medical Teaching Hospital (Dr. Linda Lowenstine and Dr. Paul Silvagni, pathology resident) (n =20 + 3 fetuses), the Armed Forces Institute of Pathology (under the direction of Dr. Tom Lipscomb) (n = 9 + one fetus), and at Colorado State University (Dr. Terry Spraker) (n = 19).

Brain

The most significant lesions were in the brain, and these varied with duration post stranding. Acute: All animals that died within the first 2 days (acute cases, n = 27) had vacuolation (presumed edema) in both the gray and white matter in many morphologic areas of the brain. There was always a striking laminar pattern of micro-vesicular vacuolation in the stratum radiatum of the anterior ventral hippocampus along with marked edema in the pyramidal cell layer of the dentate gyrus and the

hippocampus. In addition, 15 of these animals had severe acute neuronal necrosis involving most of the neurons of the dentate gyrus and many pyramidal cells in sectors CA3, CA4, CA1 and CA2 (in descending order of frequency). In another six animals there was minimal to mild necrosis in these same areas. All the hippocampal changes were segmental, involving almost exclusively the most ventral and anterior portions of "Ammond's horn". Sometimes the necrosis extended into the laminar cortex of theadjacent pyriform lobe and amygdala, or rostrally to involve the ventral rhinencephalon. In seven animals, no acute neuronal necrosis was observed in sections examined. In addition to the hippocampal and rhinencephalic lesions, which appeared to be contiguous, there was also necrosis of thalamic nuclei in two animals, and in the cuneate nucleus of the medulla in a further two animals.

Subacute

In animals that survived more than four days (short-term survivors, n = 21), edema and acute neuronal necrosis were much less apparent in the hippocampus, but there was obvious loss of neurons in dentate gyrus and hippocampal sectors as evidence of past necrosis. As survival time increased, reactive lesions such as capillary proliferation, mild diffuse gliosis, and mild perivascular lymphocyte accumulation became more apparent although ongoing acute necrosis of individual neurons could sometimes be appreciated. In some animals there was grossly apparent post necrotic hippocampal atrophy. Overt malacia (necrosis of large areas) with phagocytic glial cell ("gitter" cell) response was noted in the amygdala and pyriform lobes in nine animals and in midbrain (inferior colliculus/ lateral geniculate region) in one animal. The lesions in the amygdala and pyriform lobes were often grossly evident in fixed brain sections. In one animal that survived for six days, there was severe sub-acute asymmetrical edema causing a mass-like lesion and midline shift.

An additional finding in both groups of animals (rapid death and short-term survivors) was non-suppurative meningoencephalitis and choroiditis that varied from minimal to florid. In some of the short-term survivors, this was clearlya response to neuronal damage, but in others and in the acute death group, the lesion may have been preexisting. Non-suppurative encephalitis is a common finding in both California sea lions and southern sea otters stranding on the California coast. Chronic viral or protozoal infections are suspected, but not proven. One of the animals from this event did have protozoal tissue cysts in the brain and another one had possible endothelial tachyzooites, butinflammation did not appear to be directed toward them. Two additional animals had neuronal inclusions suggestive of a viral etiology, but electron microscopy, immunohistochemical stains and Reverse Transcriptase- Polymerase Chain Reaction (RT-PCR) were negative for morbillivirus (AFIP).

Cardiac

The heart was the second most frequently affected organ in terms of lesions that could not be attributed to known etiologic agents. Areas of myocardial pallor thought to represent necrosis and edema were grossly evident in several animals. Acute myofiber necrosis and edema were confirmed histologically in 21 of the animals that died early in the event. These varied from scattered areas of individual fiber necrosis to regionally extensive myocardial damage in two animals. In the short-term survivors, small areas of myocardial fibrosis, nuclear hyperplasia and hypertrophy, and mild non-suppurative myocarditis were noted. In one animal, small tachyzooite-like structures were associated with inflammation and in another animal *Sarcocystis*-like tissue cysts were seen. Rhabdomyolysis (muscle necrosis) was also seen in skeletal muscle of diaphragm and elsewhere in many of the animals and was thought to be secondary to the abnormal exertion of seizure activity.

Other

Other lesions identified histologically confirmed the gross diagnoses. These included cholecystitis and dochitis secondary to *Zalophatrema*, parasite-induced ulcers and stress-type acute gastric erosions and hemorrhages, pulmonary nematodiasis and verminous pneumonia. Additional common histologic lesions included: enteritis associated with trematodes or acanthocephlans, parasitic granulomas in liver and regional lymph nodes,lymphocytic interstitial nephritis, microfilaremia, vaginitis and cervicitis, cystitis, pharyngitis associated with acariasis, larval cestodiasis in colon, superficial colitis and acute enteritis.

Neoplasias

Interesting incidental findings were several neoplasms including: three cases of very early genital epithelial carcinoma; two uterine leiomyomas (one of which was external and pedunculated); one epithelium-predominant teratoma associated with the surface of the right kidney; one pharyngeal cleft cyst associated with the pineal gland; and one islet cell tumor of the pancreas. The prevalence of genital epithelial neoplasia in California sea lions in this group was 6.3% and the over-all prevalence of tumors (pharyngeal cyst excluded) was 14.6%. Another interesting case was a very old female with systemic amyloidosis.

Ocular lesions

The eyes from 12 animals (including one fetus) were examined. No lesions were noted in three animals and mild to moderate lesions noted in nine animals. The most common lesion (n = 7, including the fetus) was vacuolation (presumed edema) in the ganglion cell layer of the retina. Two animals had retinal hemorrhage, one animal had ophthalmitis, onehad bilateral corneal ulceration, one had degeneration of the outer molecular layer, and one had degeneration of the internal molecular layer. Four animals had more than one lesion. In none of the animals did the pattern of lesions mimic those described in rats with experimental domoic acid intoxication.

Reproductive lesions

Most of the females (51%) were either pregnant or recently post partum at the time of necropsy. Placentitis was apparent is five animals. Tissues from only four fetuses were examined histologically, due to the advanced autolysis of most of the fetuses recovered at gross examination. Of these four fetuses, one was severely autolyzed. One had a bacterial infection acquired *in utero* that had causedomphalophlebitis and pneumonia. The other two had large numbers of amniotic squames filling the bronchioles of the lungs. This is suggestive of fetal distress. In none of the fetuses were severe brain lesions noted (although domoic acid has been demonstrated to cross the placenta in rats).

In summary, the principal lesions that were unique to this unusual stranding event were in the brain and heart. The acute cerebral edema and neuronal necrosis were most severe in the dentate gyrus and pyramidal layers of the hippocampus in the anterior ventral region, with other areas of the brain less severely or consistently affected. Extent of lesions in these areas, especially pyriform lobe and amygdala, rhinencephalon, thallamic nuclei and lateral geniculate body and inferior colliculus of the midbrain may have been underestimated due to sectioning. In about 20% of the animals, only edema without necrosis was detected in sections of brain examined including hippocampus. Short term survivors had evidence of neuronal loss and gliosis (scarring) in the same regions as the acute cases with more evidence of extension into the pyriform lobe and amygdala in which overt malacia were often seen. The acute lesions in the hippocampus were compatible with exposure to an excitotoxin such as domoic acid as described in human cases and in experimental rats and macaques. Myocardial edema and necrosis were also features in animals that died rapidly during this event, and there was evidence of repair of

previous lesions in the short-term survivors. Myocardial necrosis has been reported in rats exposed to excitotoxins (kanic acid and N-methyl-D-aspartic acid), although it has not been previously described in domoic acid toxicosis (Rockhold *et al.*, 1989). Cardiac arrhythmia have been noted in humans exposed to domoic acid (Perl *et al.*, 1990).

TOXICOLOGY

Sea lion serum, urine, kidney, fecal samples, and stomach washings were analyzed by the Northwest Fisheries Science Center (NWFSC) Marine Biotoxin group (Trainer), the National Ocean Service (NOS) Marine Biotoxins Program (Van Dolah, Powell, Doucette and Busman), and the University of California at Santa Cruz (UCSC) (Lefebvre) for domoic acid.

Four analytical techniques were used to detect the presence of domoic acid in either tissues or fluids. These methods were: receptor binding assay (Van Dolah et al, 1997), high performance liquid chromatography-with standard ultraviolet absorptance (HPLC-UV), high performance liquid chromatography with mass spectroscopy (HPLC-MS), and high performance liquid chromatography with tandem mass spectroscopy (HPLC-MS/MS). The limit of detection for domoic acid in serum using the receptor binding assay is approximately 50 ng/mL. The limit of detection of the HPLC-UV method is approximately 0.5 ug/ml with a spiked serum recovery of 98.7%. All samples were tested in NWFSC and NOS labs by receptor binding assay. All samples were analyzed by a receptor binding assay (Van Dolah *et al.*, 1997) which uses a cloned glutamate receptor and dilutions of a domoic acid standard of known concentration. A competitive displacement curve is generated and sample results are compared to controls. Glutamate dehydrogenase is incubated with all samples prior to analysis toeliminate endogenous glutamate activity. Samples with high levels of domoic acid on receptor binding assay were confirmed using high performance liquid chromatography with MS/MS at the NOS laboratory.

Serum

Serum from fourteen clinically affected animals were analyzed by the NWFSC lab, and serum from fourteen clinically affected animals (five of which were the same as that tested by NWFSC lab) and three negative controls were analyzed by the NOS laboratory using the same microplate receptor binding assay for domoic acid (Van Dolah *et al.*, 1997). At the NWFSC lab, domoic acid was detected in the serum of one (#3806) of 14 clinically affected sea lions (Table 6). At the NOS lab, two serum samples (CSL# 3734 and #3724) were positive with low levels of domoic acid (Table 6). Because high levels of glutamic acid may cause false positives in the receptor binding assay, the presence of domoic acid was further investigated at the NOS lab using the HPLC-UV method of Quilliam (1989), and by HPLC/MS. A total of 23 clinical samples and three control sera were analyzed by the HPLC-UV method. All were negative for domoic acid. The two serum samples positive by receptor assay (#3724 and #3734) also showed low levels of domoic acid by HPLC/MS.

Urine

At the NWFSC lab, urine samples from four animals were tested (two affected animals and two control animals). Domoic acid was detected in the urine of two affected sea lions (# 3807 and #3794) as compared to urine from two control animals using the receptor binding assay. One of these urine samples from the affected animals (#3807) also had weakly positive levels of domoic acid as detected by high performance liquid chromatography (HPLC) using standard UV absorbance at 242 nm. At the NOS lab, urine from eight clinically affected animals and three control animals were tested by both thereceptor binding assay and HPLC-UV. Four of these were positive by both methods (Table 6), and three additional samples were positive by receptor assay at levels below the detection limit

of the HPLC method. Urine from one animal (#3707) was also analyzed by HPLC/MS and confirmed positive for domoic acid.

Feces

Feces from seven clinically affected animals and two control samples were analyzed at the NOS lab by receptor assay and HPLC-UV. Fecal samples were extracted using a mussel extraction and SAX clean-up method of Quilliam *et al.,* (1995) before analysis by HPLC with spiked extraction recovery of 88.4 $\pm$ 8.4%, n = 3. Three samples were positive for domoic acid (Table7) and good quantitative agreement was seen between the receptor binding assay and HPLC analyses (Table 7).

Feces from eleven clinically affected sea lions were also analyzed at UCSC for the presence of domoic acid by HPLC using the extraction method of Quilliam *et al.*, (1989). Domoic acid was detected in samples from the same three animals as at the NOS lab (Table 7). In addition, fecal samples from seven control sea lions were analyzed. These animals were three captive sea lions from Long Marine Laboratory (LML # 1, 2, 3), three captive sea lions from MarineWorld in Vallejo, CA, and one sea lion from Maverick's Beach, CA (Clutch) that was euthanized at TMMC due to severe gunshot injury two months after the event (August 1998). Domoic acid was not detected in any of these samples.

Kidney, Liver, Muscle, Brain

Five kidney samples were analyzed at the NOS lab by HPLC-UV and were negative for domoic acid (Table 7). Samples were extracted and cleaned using the same procedure as described for feces, with a spiked kidney extraction recovery of 24.6%, n = 1. Liver, muscle, brain, intestinal mucosa and kidney samples from two animals (#3765 and # 3824)analyzed by HPLC at UCSC were also negative for domoic acid.

Stomach washings

A single stomach washing sample from a clinically affected animal (CSL 3708) analyzed by receptor assay at the NOS lab was negative for domoic acid.

Confirmation of domoic acid in fluids by mass spectrometry

Serum and urine samples with the highest concentrations of domoic acid, as determined by HPLC-UV, were subjected to HPLC/MS and HPLC-MS/MS analysis at the NOS lab for confirmation of the identity of the HPLC peak in question. For both methods, sample extracts were fractionated on a C18 column eluted with a gradient of 1-95% methanol in 0.1% TFA. A PE SCIEX API-III triple quadrupole mass spectrometer was used. The ionspray source was operated in positive ion mode utilizing nitrogen for the nebulization gas. The first quadrupole was used to pass only ions of nominal 312 m/z. The conditions in the second quadrupole were adjusted to allow a substantial amount of collisionally-induced dissociation. The third quadrupole was operated in multiple ion monitoring mode, where fragments ions of 161 and 266 m/z, as well as the residual parent ions at 312 m/z were allowed to pass to the mass spectrometer ion detector. The presence of domoic acid was confirmed in urine from # 3707 and #3758 and feces from # 3783 (Table 7).

Pseudo-nizchtia frustules

Ten of the eleven fecal samples analyzed at UCSC were also examined for the presence of diatom frustules (glass skeletons) using a compound microscope, (there was insufficient sample from CSL #3734 after HPLC analyses). Diatom frustules were only found in fecal samples that had tested positive for domoic acid (#3758 and #3783). Using scanning electron microscopy, frustules were identified as *Pseudo-nitzschia australis.*

Anchovies

Domoic acid was detected in anchovies (*Engraulis mordax*) collected from Monterey Bay and Morro Bay by HPLC-UV at the NOS

lab. Two samples of anchovies collected from Monterey Bay on May 22, 1998 had detectable levels of domoic acid, while fish collected on June 10, 1998 had no detectable levels (Table 8). Two samples of anchovies from Morro Bay on June 4 also had detectable levels of domoic acid (Table 8). Domoic acid was confirmed in two anchovy samples by HPLC/MS and one by HPLC/MS/MS (Table 8)

Summary of Toxicology

These results indicate that there is consistency between domoic acid assays performed at NOS, NWFSC and UCSC labs. The NOS and NWFSC labs run the same microplate receptor binding assay as a rapid screening method for domoic acid. Although highly effective as a screening method, positive results should be confirmed by analytical methods when testing novel tissue matrices. The HPLC-UV method is suitable only when tissue concentrations are sufficiently high, because the detection limit is poorer than that of the receptor assay. HPLC/MS or HPLC/MS/MS provides the most rigorous analytical confirmation, but are expensive and time-consuming to run. In the current study HPLC/MS/MS provided the necessary independent confirmation of the chemical identity of the toxin to unambiguously conclude the involvement of domoic acid in this event. The greater detection rate in feces and urine than serum (Table 9) suggests feces and urine should be routinely collected for detection of domoic acid in marine mammal die-offs. The low detection rate in serum is probably due to the rapid clearance of this water soluble toxin from blood. Clearance in rodents and primates following intravenous inoculation is under four hours (Truelove and Iverson 1994). Although stomach contents might be valuable for analysis,the stomachs of clinically affected sea lions in this event were empty, presumably due to vomiting and the time elapsed between ingestion and *post mortem* examination. Feces, thus, proved to be the most valuable sample fortoxicological analyses, as well as for determining diet.

Table 6. Presence of Domoic Acid in Serum from California Sea Lions

Animal ID	NWFSC Receptor assay	NOS Receptor assay	NWFSC HPLC/UV	NOS HPLC/UV	NOS HPLC/MS	NOS HPLC/MS/MS
CSL 3299 C		N/D		negative	N/D	
CSL 3451 C	Negative					
CSL 3489 C		negative		N/D	N/D	N/D
CSL 3510 C		negative		negative	N/D	N/D
CSL 3512 C		negative		negative	negative	N/D
CSL 3670	Negative					
CSL 3699	Negative	negative		negative	N/D	N/D
CSL 3700	Negative	negative		negative	N/D	N/D
CSL 3707		negative		negative	N/D	N/D
CSL 3708		N/D		negative	N/D	N/D
CSL 3719		negative		negative	N/D	N/D
CSL 3720	Negative					

CSL 3724		0.17 µg eq./mL		negative	positive	N/D
CSL 3727	Negative					
CSL 3731		negative		negative	N/D	N/D
CSL 3732		negative		negative	N/D	N/D
CSL 3733		negative		negative	N/D	N/D
CSL 3734		0.2 µg eq./mL		negative	positive	N/D
CSL 3735	Negative					
CSL 3744		N/D		negative	N/D	N/D
CSL 3744		N/D		negative	N/D	N/D
CSL 3746	Negative	N/D		negative	N/D	N/D
CSL 3747	Negative	negative		N/D	N/D	N/D
CSL 3748		N/D		negative	N/D	N/D
CSL 3749		negative		negative	N/D	N/D
CSL 3752		N/D		negative	N/D	N/D
CSL 3755		N/D		negative	N/D	N/D
CSL 3757		N/D		negative	N/D	N/D
CSL 3767						
CSL 3775	Negative					
CSL 3791	negative	N/D		negative	N/D	N/D
CSL 3793	negative					
CSL 3795	negative					
CSL 3796	negative					
CSL 3806	positive					
NFS 123		negative		negative	N/D	N/D

Table 7 Presence of Domoic Acid in Urine, Feces and Tissues from California Sea Lions

	NWFSC	**NOS**	**NWFSC**	**NOS**	**NOS**	**NOS**	**UC Santa Cruz**
Animal ID	**Receptor assay**	**Receptor assay**	**HPLC/ UV**	**HPLC/UV**	**HPLC/ MS**	**HPLC/MS/MS**	**HPLC/UV**
URINE		g eq./mL		g/mL			
CSL 3451 C	negative						
CSL 3707		3.72		14.05	positive	positive	
CSL 3726		0.12		2.68	N/D	N/D	
CSL 3741		0.03		negative	N/D	N/D	
CSL 3742		N/D		negative	N/D	N/D	
CSL 3749		0.72		2.38	N/D	positive	

CSL 3767 C	negative						
CSL 3794		3.72		14.05	positive	positive	
CSL 3800		0.12	positive	2.68	N/D	N/D	
CSL 3807		0.03		negative	N/D	N/D	
CSL 3841 C		N/D		negative	N/D	N/D	
CSL 3882 C		0.72		2.38	N/D	positive	
CSL 3883 C		N/D		negative	N/D	N/D	
NFS 123		0.12		negative	N/D	N/D	
FECES							
CSL 3734		1.31		5.23	N/D	N/D	2.79
CSL 3741		N/D		negative	N/D	N/D	negative
CSL 3747		N/D		negative	N/D	N/D	negative
CSL 3758		96.08		46.89	positive	N/D	45.26
CSL 3783		182.01		167.53	positive	positive	114.39
CSL 3806		N/D		negative	N/D	N/D	negative
CSL 3807		N/D		negative	N/D	N/D	negative
fc1a C		negative		negative	N/D	N/D	negative
fc4aC		negative		negative	positive	N/D	negative
KIDNEY							
CSL 3685		N/D		negative	N/D	N/D	negative
CSL3691		N/D		negative	N/D	N/D	negative
CSL3692		N/D		negative	N/D	N/D	negative
CSL3707		N/D		negative	N/D	N/D	negative
CSL3724		N/D		negative	N/D	N/D	negative

Table 8. Domoic acid levels in Anchovies from the Central California Coast

Sample site & Date	**Receptor Assay NOS**	**HPLC/UV**	**HPLC/MS**	**HPLC/MS/MS**
	g equiv/g	g/g		
5/22/98a Monterey Bay	71.30	100.35	N/D	Positive
5/22/98b Monterey Bay	69.67	123.04	Positive	N/D
6/4/98a Morro Bay	2.53	4.05	Positive	N/D
6/4/98b Morro Bay	0.27	0.82	N/D	N/D
6/10/98a Monterey Bay	N/D	Negative	N/D	N/D
6/10/98b Monterey Bay	N/D	Negative	N/D	N/D

Table 9. Samples positive for Domoid Acid by different laboratory analyses

	Receptor binding assay		HPLC/UV		HPLC/MS/MS	
	Positives	Number tested	Positives	Number tested	Positives	Number tested
Serum	3	26	1	21	2	2
Urine	11	14	9	15	2	2
Feces	0	0	3	13	1	1
Cerebrospinal fluid	0	3	0	1	0	0
Stomach washing	0	0	0	1	0	0
Gastric mucosa	0	0	0	1	0	0
Kidney	0	0	0	5	0	0

PLANKTON BLOOM

Within Monterey Bay, plankton samples are routinely collected several times per week from the Santa Cruz wharf and Monterey Coast Guard pier. Samples are also collected along several sites running due west of Moss Landing as part of the Monterey Bar Aquarium Research Institute (MBARI) upper water column time series project. Samples are subjected to DNA probe-based tests as a means of identifying and quantifying a variety of toxic and non-toxic *Pseudo-nitzschia* species as well as the toxigenic dinoflagellate *Alexandrium tamarense* (e.g., Scholin *et al.* 1996, 1997, submitted;). An example of the time series data collected from the Santa Cruz wharf is shown in Figure 3. During thespring bloom of diatoms, toxigenic *Pseudo-nitzschia* species were largely absent and no domoic acid was detected in plankton samples (Fig. 3, arrow #1). As the spring bloom progressed, *A. tamarense* was detected, and shellfish samples collected from the same area tested positive for paralytic shellfish poisons (Fig. 3, arrow #2). As the bloom of *Alexandrium* declined, the number of *Pseudo-nitzschia australis* increased sharply (arrow #3). The amount of domoic acid (= bars) in water samples rose in concert with increasing numbers of *P. australis* (arrow #4). As the bloom of *P. australis* reached its maximum, toxigenic cells were concentrated in a narrow band near shore. It is possible, although in no way proven, that the cells responded to nutrient enrichment of near shore waters as a result of enhanced river flows following late spring rains.

Anchovies collected from Monterey Bay during the height of the *P. australis* bloom contained high levels of domoic acid and high numbers of *P. australis* in their stomachs (Fig. 4). The *P. australis* bloom was replaced by a large *P. pseudodelicatissima* bloom (not shown on Fig. 3). Some *P. pungens* and *P. multiseries* were also present, but at relatively low levels. During this transition in species abundance, the concentration of domoic acid declined rapidly and precipitously in the upper water column (Fig. 3, arrow #5). Gut contents of anchovies collected at this time reflected this change in species abundance as well (Fig. 5), as they did not contain detectable levels of domoic acid. Reports of sickened sea lions fromMonterey Bay decreased in concert with the loss of *P. australis* from the upper water column and the rise in dominance of *P. pseudodelicatissima.* Notably, cultures of *P. australis* isolated from Monterey Bay produce domoic acid whereas isolates of *P. pseudodelicatissima* from the same area do not.

During the *P. pseudodelicatissima* bloom inside Monterey Bay, high concentrations of toxigenic *P. multiseries* were found south and especially north of that region. Thus, species composition of *Pseudo-nitzschia* populations found within Monterey Bay and contiguous waters of the central California coast can differ substantially.
Throughout the remainder of the year *P. australis* was not abundant in Monterey Bay.

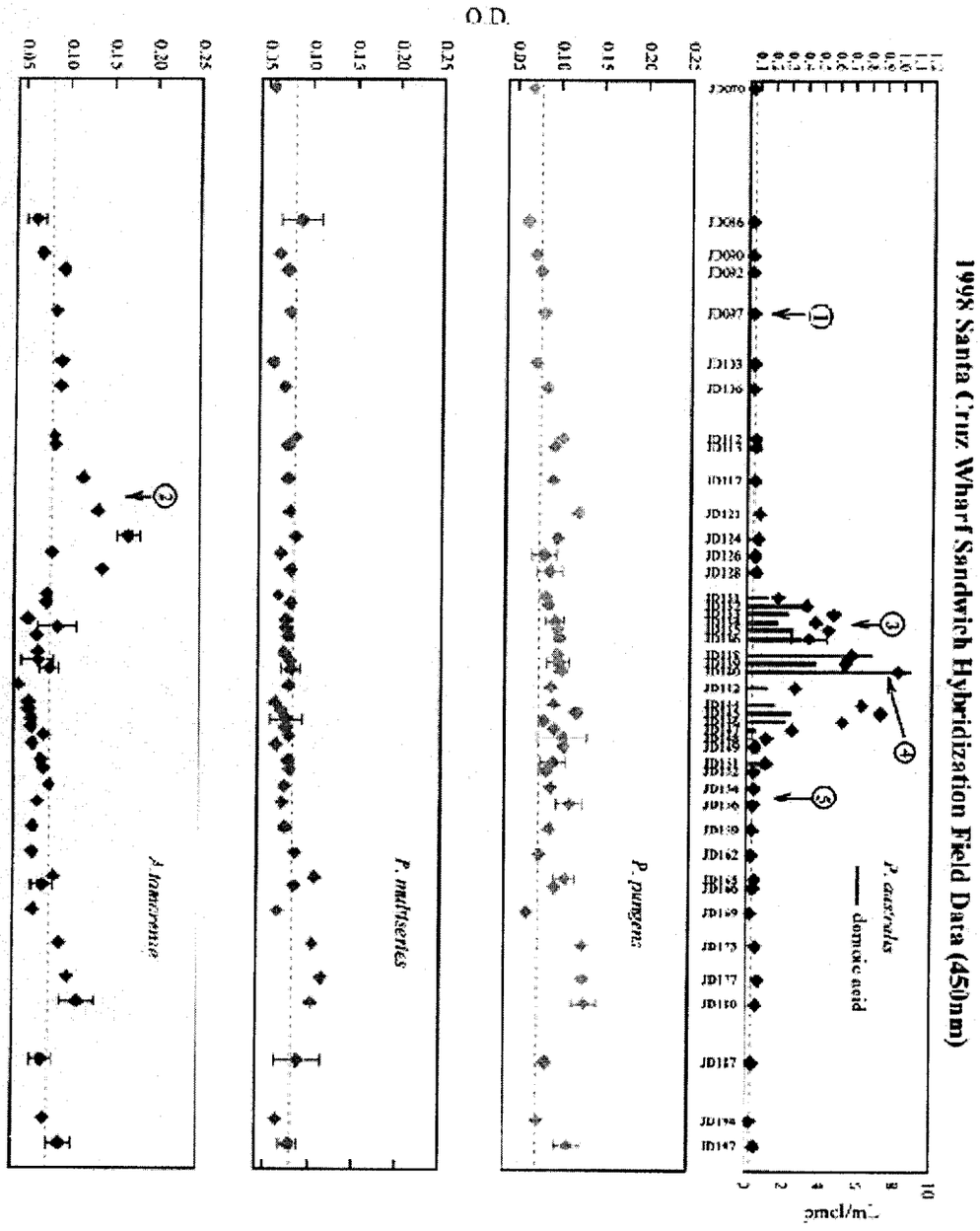

Figure 3. 1998 time series data collected at the Santa Cruz wharf station showing results of sandwich hybridization assays (optical density, O.D.) for *Pseudonizchtia australis, P. pungens, P. multiseries* and North American strains of *Alexandrium tamarense/catanella* plotted as a function of time (Julian day). Increasing O.D. indicates a rise in species abundance; the dashed line indicates lower limit of detection. Corresponding amounts of domoic acid associated with a particulate fraction of plankton are given as pmol toxin per mL water filtered (top panel, bars). Arrows refer to particular events described in the text.

Anchovy gut contents containing *Pseudo-nitzschia australis*, May 29, 1998.



Figure 4.
Scanning electron micrographs of anchovy stomach contents at the height of the *P. australis* bloom. Anchovies caught in the Monterey Bay area had stomachs packed with *P. australis* frustules (A = overview, B and C = close-up showing frustules are *P. australis*).

Anchovy gut contents 6/10/98



Figure 5.
Scanning electron micrographs of anchovy stomach contents after the *P. australis* bloom. Overview micrograph shows that anchovies caught in the Monterey Bay area had stomachs packed primarily with *P. delicatissima* (C), the dominant Pseudonizchtia in the water column at the time. Fragments of *P. australis* were also found (B), as well as frustules of *P. multiseries* (D), but the latter two species were not abundant.

DIAGNOSIS

The combination of clinical signs (scratching, seizuring, anchovies in fecal matter), histopathological (hippocampal necrosis), toxicological (domoic acid in serum, urine, feces, anchovies) and epidemiological findings (simultaneous mortality in sea lions and the presence of toxin-producing blooms) led to the diagnosis of domoic acid toxicity in the sea lions. This intoxication was due to blooms of Pseudonizchtia australis that were ingested by anchovies that in turn were eaten by California sea lions. Although a variety of incidental histopathologic and serologic changes were detected in the sea lions examined, they were not considered to be the cause of the mortality event. However, virus neutralization titers to phocine distemper virus, presence of protozoa in the brain and early neoplastic lesions warrant further investigation to determine their role in health of the California sea lion population.

POST RELEASE MONITORING

Three sea lions that survived the event were released with telemetry devices to monitor movements and survival after release. Adult females were selected, as animals of this sex and age are currently being tagged and monitored off San Miguel Island by Dr. Robert De Long and Sharon Melin from the National Marine Mammal Laboratory, and could be used as normal controls. The three animals selected had all shown typical clinical signs during the "event". One had seizures for only 48 hrs, one had repeated seizures for up to a week, and the third had seizures for up to one month post stranding. They were thus classed as mild, moderate and severe cases. None of the animals had been pregnant when stranded. As the tags are fixed to the animals using glue on the hair, the animals were not released until after the annual molt in September.

The three sea lions (CSL #3812, #3815 and #3822) were sedated with midazolam intramuscularly at 0.02 mg/kg (mixed with atropine at 0.02 mg/kg), then masked with isoflurane until relaxed but with intact gag reflex. Satellite-linked transmitters or platform transmitter terminals (ST-10 Argos PTT model; Telonics, Mesa, AZ) were glued to the dorsum between the scapulae using 5-minute epoxy. These tags were approximately 14 x 5 x 1 cm and weighed 0.2 kg. To conserve battery power and prolong the life of the PTTs, the duty cycle was set to transmit for 24 hrs every other day. Location data were collected by Service Argos. Radio transmitters (Advanced Telemetry Systems, Isanti, MN) were attached to the heads of each sea lion. These transmitters weighed 0.05 kg each and had 30 cm long whip antennae.

The sea lions were tagged on November 4 and released on November 6 at Weston Beach, Point Lobos State Reserve, Carmel, California (Fig. 6). This site was chosen as it was within the Monterey Bay, the area in which the sea lions stranded during the event, and is a protected area frequented by this species.

Two of these three sea lions were resighted. One animal was observed on December 10 1998 with a satellite transmitter and a VHF transmitter on Año Nuevo Island (Morris, pers. comm.), although its ID number was not determined. #3812 and #3815 were sighted on December 23 1998, 48 days after release. On this day, #3815 had a radio transmitter, but had lost the satellite transmitter. Satellite data indicate that the transmitter detached from the sea lion while on shore. Transmissions were received from the transmitter until February 7 1999. Sea lion #3812 was also sighted on January 8 1999 at Año Nuevo Island, with both transmitters attached.

Sea lion #3822 swam as far south as Point Benett, San Miguel Island (~325 km), where it remained for five days, before traveling north again to areas off the Big Sur Coast. Sea lion #3822 also made a second trip down to San Miguel Island, and returned north again (Figure 6a). A total of 170 positions was received for 64 days, until transmissions ceased on January 8 1999 off Point Lobos (36.519N, 121.954W). It is unclear whether signal cessation was a result of mortality, tag malfunction or tag loss. A total of 333 positions was received for sea lion #3812, which traveled as far north as the Farallon Islands, and as far south as the Channel Islands. Sea lion #3812 remained near the Channel Islands for one week, but returned to areas around Año Nuevo Island (Figure 6b). The last transmission from #3812 was 94 days post release on February 7 1999 off Pescadero Point, California (37.241N, 122.488W). Sea lion #3815 primarily remained within and around areas adjacent to Monterey Bay while the satellite tag was attached. Although the date of tag detachment from this animal is unclear, transmissions ceased on February 7, 1999. The failure of transmissions from two tags within a day of each other suggests that this was due to battery expiration rather than death of the sea lions.

At least two of the three satellite-tagged sea lions survived up to three months post release and data indicated they were using areas where wild sea lions could be found. Melin *et al.* (1993) found that female California sea lions from San Miguel Island, which were tagged with satellite-linked time depth recorders, foraged northwest of San Miguel Island during winter and spring months. Furthermore, tagged sea lions from San Miguel Island traveled as far as 460 km north along the mainland coast of California (Melin *et al.* 1993). Thus, movements of the three rehabilitated sea lions may have been typical.

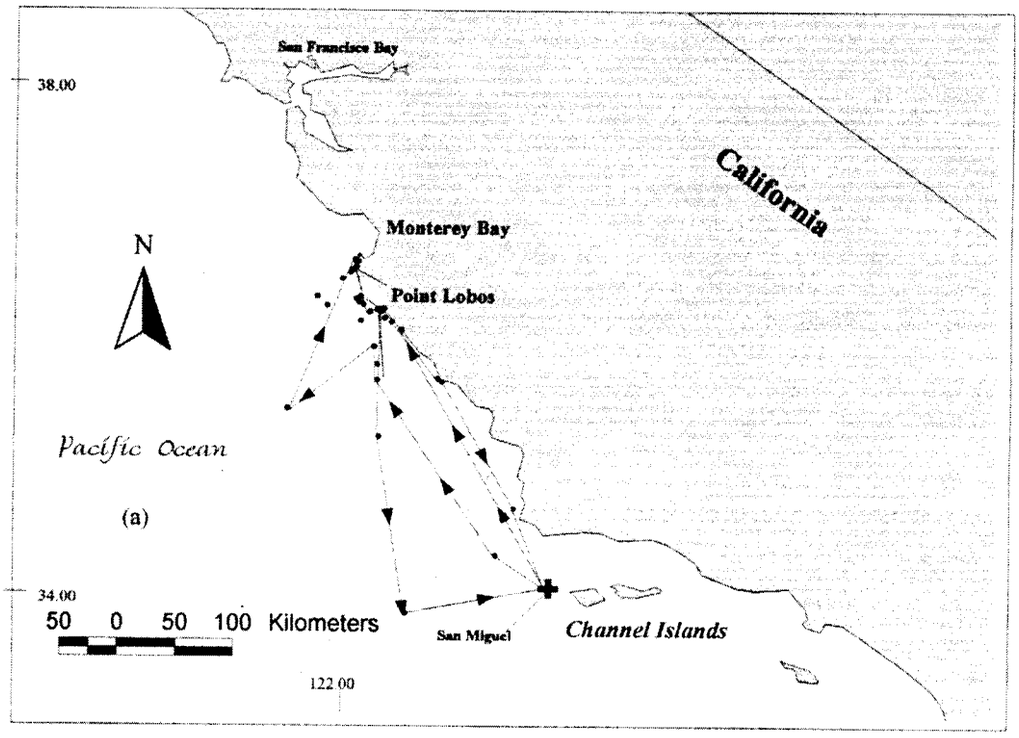

Figure 6. Locations of rehabilitated sea lions #3822 (a) and #3812 (b), that were satellite-tagged and released at Point Lobos. Location of greatest accuracy per day was plotted. Arrows represent direction of travel for sea lion #3822, which made two trips to San Miguel.

DISCUSSION

This is the first report of domoic acid toxicity in marine mammals. However, as algal blooms producing domoic acid have been observed previously along the California coast (Walz *et al.*, 1994), and domoic acid toxicity was reported in brown pelicans off Monterey in 1991 (Work *et al.*, 1993), it is likely that this toxicosis has occurred previously in marine mammals. Clusters of stranded adult sea lions that showed similar neurologic signs to those in the animals in this 1998 event have been observed at other times along the California coast, although no cause was determined. In July 1978, 40 animals stranded in Ventura County displaying neurologic signs (Gilmartin *et al.*, 1979); in 1986, 11 sea lions showing opisthotonus and convulsions were admitted to TMMC (Vandenbroek *et al.*, 1987); in 1988, 38 sea lions and ten northern fur seals (*Callorhinus ursinus*) with similar signs were admitted to TMMC (Gage *et al.*, 1989) and in 1992 18 sea lions stranded in San Luis Obispo County displaying similar signs (Beckmen *et al.*, 1995). Similar histological changes in the hippocampus to those in sea lions from this 1998 event were observed by Dr. Linda Lowenstine in animals that died in the 1992 event. Two stomachs from seizuring sea lions during the 1992 seizure event were submitted for domoic acid analysis with negative results. However, the stomachs were devoid of contents. No suitable samples,i.e. serum, urine or feces, are available from earlier animals for retrospective analysis. As there was a bloom of *P. australis* in Monterey Bay in 1992 (Walz *et al.*, 1994), it is likely that domoic acid toxicity affected sea lions off California earlier than 1998. In addition, since this event there has been another similar occurrence in October 1998.

From July 12 to October 17, 1998 an additional eleven California sea lions stranded with similar clinical signs to the animals described in this report. Nine of the animals stranded from October 3 to October 17. Six animals were euthanized or died, and four animals recovered and were released. Four of six urine samples from sea lions in the October event analyzed for domoic acid by HPLC-UV were positive (Table 6), while one CSF sample was negative. Serum, urine, and cerebrospinal fluid (CSF) were tested by receptor binding assay only. Domoic acid was detected by RBA in three out of six urine samples from clinically affected animals. All serum and CSF samples tested were negative for domoic acid. During this time period, cells of *P. australis* did reach ~10,000 cells per liter at the Santa Cruz pier, however, much higher cell concentrations were observed outside of Monterey Bay, again highlighting the difference between water masses within and outside of the Bay. In this case, it is likely that the bloom of *P. australis* was fueled by upwelling and that cells and their associated toxin did not penetrate Monterey Bay to any great extent. This recent episode illustrates the quick response that stranding rates and pinnipeds may have to toxic blooms of *P. australis*.

The combination of oceanographic data, evidence of domoic acid in the prey eaten by the sea lions, clinical signs and histopathology are important in making a diagnosis of domoic acid toxicity, as detection of domoic acid in sea lion tissues is limited. The detection of domoic acid in only three serum samples by receptor binding assay is not surprising, as the plasma half-life is short in other species (21.6 minutes in rats, 114 minutes in monkeys; (Truelove and Iverson, 1994). Blood samples were not collected from sea lions until they arrived at TMMC after initial stranding, detection of the animal by the public and transport by road up to 200 miles. It is therefore likely that the domoic acid had been cleared from plasma by the time blood was collected in most cases. As domoic acid is water soluble and excreted in urine, it is also not surprising that it was detected in urine rather than plasma in some animals.

The even higher detection rate in feces may reflect poor absorption from the gastro-intestinal tract due to poor lipid solubility. After oral administration of domoic acid to rats, recovery from feces was complete (Iverson *et al.*, 1989).

In contrast to the toxicologic results, both clinical signs and histopathologic changes were characteristic of domoic acid toxicity as reported in other species, although a variety of incidental signs and lesions were detected. The seizures were dramatic, and presumably a consequence of domoic acid binding in the brain. Domoic acid is an excitatory neurotoxin that binds to neurones via high-affinity AMPA- and kainate-sensitive glutamate receptors to produce excitotoxic cell death (Iverson and Truelove, 1994; Larm *et al.*, 1997). In between seizures, the scratching behavior was reminiscent of the hallmark scratching syndrome documented in mice that distinguishes paralytic shellfish poisoning from domoic acid toxicity (Todd, 1993). Similar behavior was also described in pelicans intoxicated with domoic acid (Work *et al.*, 1993). The ability of animals to survive exposure, as demonstrated by the satellite-tracking data, is also consistent with the survival of exposed humans in the Canadian outbreak in people who ate contaminated mussels (Perl *et al.* 1990).

The significance of the virus neutralization titers to phocine distemper virus (PDV) in a few animals is unclear. However, the lack of accompanying histopathological changes consistent with morbillivirus infection, negative RT-PCR for morbillivirus on brain tissue, and the similar seroprevalence of PDV antibodies in banked sea lion sera suggest the presence of antibodies in sea lions dying during the event did not play a role in this event. In contrast, in the recent Mediterranean monk seal die-off, a controversy as to the cause of the die-off occurred, due to the isolation of a morbillivirus from tissue of affected animals, in addition to detection of saxitoxin (Osterhaus *et al.*, 1997; Costas and Lopez-Rodas, 1998).

Over the time frame of the "seizuring sea lion" event, large numbers of dead pinnipeds and sea birds were observed on the beaches around Monterey Bay. The causes of death of these animals were not determined. However, many were severely emaciated. Based on gross appearance and predictions of species likely to be affected by changes in food availability during El Niño events (Bodkin and Jameson 1991, Trillmich and Ono 1991), it is likely that many of these mortalities were a consequence of starvation due to food shortage. It is thus unclear how many sea lions in total were affected by domoic acid. The overall mortality due to domoic acid is likely to be more than 57 individuals, but is unknown. As the overall California sea lion population is estimated at 167,000 individuals, an event causing mortality in 0.00004 % does not constitute a threat to the population. However, the rapid and dramatic nature of the event suggests the potential for similar harmful algal blooms to impact endangered species, such as the Steller's sea lion or Hawaiian monk seal, before control measures can be implemented. In addition, the susceptibility of humans to domoic acid suggests that outbreaks of toxicity in marine mammals should be fully investigated and measures taken to prevent human morbidity and mortality.

Acknowledgments.

This investigation would not have been possible without the willing collaboration and enthusiasm of each of the organizations involved. Special thanks are due to Diane Paschall for assistance in putting this report together, the Monterey Bay Aquarium Research Institute for funding a workshop in the wake of the event to bring investigators together and facilitate exchange of data, Wanda Dietrich for editing and formatting this document, and the staff and volunteers of TMMC for their hard work caring for the sea lions during the event.

REFERENCES

Antonelis, G. A., Fiscus, C. H. and R. L. DeLong. 1984. Spring and summer prey of California sea lions, *Zalophus californianus*, at San Miguel Island, California, 1978-1979. ***Fishery Bulletin*** 82: 67-76.

Beckmen, K., Lowenstine, L. J. and F. Galey. 1995. Epizootic seizures in California sea lions (*Zalophus californianus*). ***11th Biennial Conference of the Marine Mammal Society, Orlando, Florida.*** (Abstract) p. 10.

Bodkin, J. L. and R. J. Jameson. 1991. Patterns of seabird and marine mammal carcass deposition along the central California coast, 1980 - 1986. ***Canadian Journal of Zoology*** 69: 1149-1155.

Cordaro, J. 1997. Pinniped strandings in California: Analysis and Trends. In "Pinnipeds Populations, Eastern North Pacific: Status, Trends and Issues." Eds. G. Stone, J. Goebel and S. Webster. ***127th Annual Meeting of the American Fisheries Society***, Monterey, California, August 28, 1997. pp. 40-45.

Costas, E. and Lopez-Rodas, V. 1998. Paralytic phycotoxins in monk seal mass mortality. ***Veterinary Record*** 142: 643-644.

Gage, L. J. and D. Smith. 1989. Convulsing sea lions at the California Marine Mammal Center, ***20th Annual International Association for Aquatic Animal Medicine Conference***, 1989 May 14-18, San Antonio, Texas (Abstract).

Gilmartin, W. G. 1979. Fatal hepatoencephalopathy in a group of California sea lions. ***10th Annual International Association for Aquatic Animal Medicine Conference***, 1979 April 22-26, St. Augustine, Florida (Abstract)

Gulland, F. M. D., Trupkiewicz, J. G., Spraker, T. R. and L. J. Lowenstine. 1996. Metastatic carcinoma of probable transitional cell origin in 66 free-living California sea lions (*Zalophus californianus*), 1979-1994. ***Journal of Wildlife Diseases*** 32: 250-258.

Iverson F. and J. Truelove. 1994. Toxicology and seafood toxins: domoic acid. ***Natural Toxins*** 2: 334-339.

Iverson, F., Truelove, J., Nera, E., Tryphonas L., Campbell, J. and E. Lok. 1989. Domoic acid poisoning and mussel-associated intoxication: Preliminary investigations into the response of mice and rats to toxic mussel extract. ***Food and Chemistry Toxicology*** 27: 377-384.

Larm, J. A., Beart, P. M. and N. S. Cheung. 1997. Neurotoxin domoic acid produces cytotoxicity via kainate and AMPA- sensitive receptors in cultured cortical neurones. ***Neurochemistry International*** 31: 677-682.

Melin, S.R., R.L. DeLong, J.R. Thomason, and D.E. Valesquez. 1993. Foraging behavior of female California sea lions at San Miguel Island, California: winter 1992 and 1993. ***Tenth Biennial Conference on the Biology of Marine Mammals***. 11-15 November. Galveston, Texas.

Osterhaus, A. D. M. E., Groen, J., Niesters, H., van de Bildt, M., Martina, B., Vedder, L., Vos, J., van Egmond, H., Abou Sidi, B. and M. E. O. Barham. 1997. Morbillivirus in monk seal mass mortality. ***Nature*** 388: 838-839.

Perl, T. M., Bedard, L., Kosatsky, T., Hockin, J. C., Todd, E. C. and R. C. Remis. 1990. An outbreak of toxic encephalopathy caused by eating mussels contaminated with domoic acid. ***New England Journal of Medicine*** 322: 1775-1780.

Quilliam, M. A., Sim, P. G., McCulloch, A, W. and A. G. McInnes. 1989. High performance liquid chromatography of domoic acid, a marine neurotoxin, with application to shellfish and plankton. ***International Journal of Environmental and Analytical Chemistry*** 36:139-154.

Quilliam, M. A., Xie, M. And W. R. Hardstuff. 1995. Rapid extraction and cleanup for liquid chromatographic determination of domoic acid in unsalted seafood. ***Journal AOAC International*** 78: 543-554.

Rockhold, R. W., Acuff, C. G. and B. R. Clower. 1989. Excitotoxin-induced myocardial necrosis. ***European Journal of Pharmacology*** 166: 571-576.

Schmued, L. C., Scallet, A. C. and W. Slikker. 1995. Domoic acid induced neuronal degeneration in the primate forebrain revealed by degeneration specific histochemistry. ***Brain Research*** 695: 64-70.

Scholin, C. A., Buck, K.R., Britschgi, T., Cangelosi, G. & Chavez, F.P. 1996. Identification of Pseudo-nitzschia australis using rRNA-targeted probes in whole cell and sandwich hybridization formats. ***Phycologia*** 35: 190-197.

Scholin, C. A., Miller, P.E., Buck, K.R. & Chavez F.P. 1997. Detection and quantification of *Pseudo-nitzschia australis* in cultured and natural populations using LSUrRNA-targeted probes. ***Limnology and Oceanography*** 42(5, part 2): 1265-72.

Scholin, C.A., Marin, R. III, Miller, P.E., Doucette, G.J., Powell, C.L., Howard, J., Haydock, P., Ray, J. Application of DNA Probes and a Receptor Binding Assay for Detection *of pseudo-nitzschia* (Bacillariophyceae) Species and Domoic Acid in Cultured and Natural Samples. ***Journal of Phycology*** (in review).

Teitelbaum, J. S., Zatorre, R. J., Carpenter, S., Gendron, D., Evans, A. C., Gjedde, A. and N. R. Cashman. 1990. Neurologic sequelae of domoic acid intoxication due to the ingestion of contaminated mussels. ***New England Journal of Medicine*** 322: 1781-1787.

Thornton, S., Nolan, S. and F. M. D. Gulland. 1998. Bacterial isolates from California sea lions (*Zalophus californianus*), harbor seals (*Phoca vitulina*), and northern elephant seals (*Mirounga angustirostris*) admitted to a rehabilitation center along the central California coast, 1994-1995. ***Journal of Zoo and Wildlife Medicine*** 29: 171-176.

Todd, E. 1993. Domoic acid and amnesic shellfish poisoning: a review. ***Journal of Food Protection*** 56: 69-83.

Trillmich, F. and K. A. Ono (eds.). 1991. **Pinnipeds and El Niño: responses to environmental stress.** Springer-Verlag, Berlin.

Truelove J. and F. Iverson. 1994. Serum domoic acid clearance and clinical observations in the cynomolgus monkey and Sprague-Dawley rat following a single i.v. dose. ***Bulletin of Environmental Contamination and Toxicology*** 52: 479-486.

Tryphonas, L. and F. Iverson. 1990. Neuropathology of excitatory neurotoxins; the domoic acid model. ***Toxicologic Pathology*** 18 (part 2) :165-169.

Tryphonas L., Truelove, J. and F. Iverson F. 1990. Acute parenteral neurotoxicity of domoic acid in Cynomolgus monkeys (*M. fasicularis*). ***Toxicologic Pathology*** 18: 297-303.

Vandenbroek, D. J., Keeler, D., McBain R., Gage, L. J., Amaya-Sherman, L. and M. Koski. 1987. Tonic-clonic convulsions in California sea lions. ***18th Annual International Association for Aquatic Animal Medicine Conference,*** 1987 May 10-14, Monterey, California (Abstract).

Van Dolah, F. M., Leighfield, T. A. and J. S. Ramsdell. 1997. A microplate receptor assay for the amnesic shellfish poisoning, domoic acid, utilizing a cloned glutamate receptor. ***Analytical Biochemistry***, 245: 102-103.

Work, T. M., Barr, B., Beale, A. M., Fritz, L., Quilliam, M. A. and J. L. C. Wright. 1993. Epidemiology of domoic acid poisoning in brown pelicans (*Pelecanus occidentalis*) and Brandt's cormorants (*Phalacrocorax penicillatus*) in California.. ***Journal of Zoo and Wildlife Medicine*** 24: 54-62.

Walz, P. M., Garrison, D. L., Graham, W. M., Cattey, M. A., Tjeerdema, R. S. and M. W. Silva. 1994. Domoic-acid producing diatom blooms in Monterey Bay, California: 1991-1993. ***Natural Toxins*** 2: 271-279.

List of Terms

dl	deciliter; one-tenth of a liter
g or gm	gram
HPLC	High Performance Liquid Chromotography
HPLC/UV	High Performance Liquid Chromotography with ultraviolet detection
HPLC/MS	High Performance Liquid Chromotography with mass spectrometry
HPLC/MS/MS	High Performance Liquid Chromotography with tandem mass spectrometry
IM	intramuscular
IV	intravascular
kg	kilogram; one thousand grams
mg	milligram; one-thousandth of a gram
ml	milliliter; one-thousandth of a liter
mm	millimeter; one-thousandth of a meter
M	mass
m/z	mass/charge
NOS	National Ocean Service, National Oceanic and Atmospheric Administration, Charleston, South Carolina
NWFSC	Northwest Fisheries Science Center, National Marine Fisheries Service, Seattle, Washington
RBA	Receptor binding assay
SAX	strong anion exchange
SSP	species
TFA	Trichloroacetic acid
TMMC	The Marine Mammal Center, Sausalito, California
ug	microgram; one-millionth of a gram
UCSC	University of California, Santa Cruz

Appendix 1A Dead Animals										
Acc #	Name	Admit date	Disposition	Disp Date	Sex	Age class	Age	Pregnant	Strand Location	Strand County
							Yrs			
CSL 3690	Jarkarta	5/18/98	Died	5/18/98	F	Adult	7	no	Monterey	Monterey
CSL 3691	Angelo	5/18/98	Died	5/18/98	F	Adult	9	no	Oceano Dunes	San Luis Obispo
CSL 3692	Jordan	5/16/98	Died	5/18/98	F	Adult	9	no	Oceano Dunes	San Luis Obispo
CSL 3699	Sallee	5/19/98	Euthanized	5/20/98	F	Adult	13	yes	Oceano Dunes	San Luis Obispo
CSL 3700	Alexandra	5/19/98	Euthanized	5/20/98	F	Adult	6	no	Oceano Dunes	San Luis Obispo
CSL 3707	Franky	5/20/98	Euthanized	5/21/98	M	Subadult	3.5	NA	Oceano Dunes	San Luis Obispo
CSL 3709	Dean	5/20/98	Died	5/20/98	F	Adult	11	no	Oceano Dunes	San Luis Obispo
CSL 3721	Toe	5/21/98	Died	6/3/98	F	Adult		yes	Oceano Dunes	San Luis Obispo
CSL 3724	Three	5/21/98	Died	5/22/98	F	Adult	10	yes	Oceano Dunes	San Luis Obispo
CSL 3725	Two	5/21/98	Died	5/21/98	F	Adult	8	yes	Oceano Dunes	San Luis Obispo
CSL 3726	Pedwar	5/21/98	Euthanized	6/2/98	F	Adult		yes	Oceano Dunes	San Luis Obispo
CSL 3729	Andromeda	5/22/98	Euthanized	6/1/98	F	Adult	11	no	Monterey	Monterey
CSL 3732	Neuf	5/22/98	Died	6/22/98	F	Adult		no	Oceano Dunes	San Luis Obispo
CSL 3734	Benny	5/22/98	Died	5/23/98	F	Subadult	4	no	Oceano Dunes	San Luis Obispo
CSL 3736	Eight	5/22/98	Died	5/22/98	M	Juvenile		NA	Oceano Dunes	San Luis Obispo
CSL 3741	Lumberjack	5/23/98	Died	5/29/98	F	Adult	7	yes	Marina	Monterey
CSL 3742	Chaos	5/23/98	Euthanized	5/31/98	F	Adult	10	no	Monterey	Monterey
CSL 3743	DOA	5/23/98	Died	5/23/98	F	Adult	4.5	yes	Marina	Monterey
CSL 3744	Reid	5/23/98	Died	5/23/98	F	Adult	6	no	Marina	Monterey
CSL 3745	Theiran	5/22/98	Died	6/12/98	M	Juvenile		no	Oceano Dunes	San Luis Obispo
CSL 3746	Finnegan	5/22/98	Euthanized	6/1/98	F	Adult	12	yes	Oceano Dunes	San Luis Obispo
CSL 3747	Fiona	5/22/98	Euthanized	6/2/98	F	Adult		yes	Oceano Dunes	San Luis Obispo
CSL 3748	Sixteen	5/22/98	Died	5/23/98	F	Adult		no	Oceano Dunes	San Luis Obispo
CSL 3749	Shamus	5/22/98	Died	5/24/98	F	Adult	11	yes	Oceano Dunes	San Luis Obispo
CSL 3757	Twenty six	5/23/98	Died	5/23/98	F	Adult		yes	Oceano Dunes	San Luis Obispo
CSL 3758	Twenty three	5/23/98	Died	5/23/98	F	Adult	8	no	Shell Beach	San Luis Obispo
CSL 3760	Oatmeal	5/24/98	Euthanized	6/2/98	F	Adult		Yes-fetus	Oceano Dunes	San Luis Obispo
CSL 3765	DOA	5/24/98	Died	5/24/98	F	Adult	4	yes	Monterey	Monterey
CSL 3768	Toddy	5/24/98	Died	11/25/98	M	Juvenile		NA	Sand City	Monterey
CSL 3770	Joule	5/24/98	Euthanized	6/4/98	F	Adult	7	Yes-fetus	Monterey	Monterey
CSL 3780	DOA	5/24/98	Died	5/24/98	F	Adult		yes	Watsonville	Santa Cruz
CSL 3783	Thirty two	5/23/98	Died	5/24/98	F	Adult	13	no	Oceano Dunes	San Luis Obispo
CSL 3791	Neville	5/24/98	Euthanized	6/2/98	F	Adult	12	no	Avila	San Luis Obispo
CSL 3793	Roller	5/25/98	Euthanized	6/4/98	F	Adult	8	Yes-stillbor	Watsonville	Santa Cruz

Acc #	Name	Admit date	Disposition	Disp Date	Sex	Age class	Age	Pregnant	Strand Location	Strand County
							Yrs			
CSL 3794	Muddy	5/25/98	Died	5/31/98	F	Adult	10	Yes-fetus	Moss Landing	Monterey
CSL 3796	Kristen	5/23/98	Died	6/1/98	F	Adult	7	Yes-fetus	Pismo Pier	San Luis Obispo
CSL 3800	Lady bug	5/26/98	Euthanized	5/27/98	F	Adult	6	Yes-fetus	Moss Landing	Monterey
CSL 3801	Whisper	5/25/98	Euthanized	5/31/98	F	Adult	9	no	Oceano Dunes	San Luis Obispo
CSL 3802	No Name	5/26/98	Euthanized	6/27/98	F	Adult		Yes-fetus	Monterey	Monterey
CSL 3803	Ouch	5/26/98	Euthanized	5/27/98	F	Adult	9	no	Pacific Grove	Monterey
CSL 3804	Kitty	5/26/98	Euthanized	6/3/98	F	Adult		no	Moss Landing	Monterey
CSL 3806	Flower	5/27/98	Euthanized	6/1/98	F	Adult	8	Yes-fetus	Monterey	Monterey
CSL 3807	Opal	5/27/98	Died	5/27/98	F	Adult	9	Yes-fetus	Aptos	Santa Cruz
CSL 3824	Sady	5/29/98	Euthanized	6/3/98	F	Adult	11	yes	Santa Cruz	Santa Cruz
CSL 3901	Palm	6/8/98	Euthanized	6/22/98	F	Adult		no	Pajaro Dunes	Santa Cruz
CSL 3931	Whitelight	6/14/98	Euthanized	6/14/98	M	Subadult		NA	Half Moon Bay	San Mateo
CSL 3950	Athena	6/16/98	Died	6/20/98	F	Adult		no	Pacific Grove	Monterey
CSL 3969	Digger	6/19/98	Died	6/19/98	F	Adult		NA	Oceano Dunes	San Luis Obispo

Appendix 1B Live Animals									
Acc #	Name	Admit date	Dispositior	Disp Date	Sex	Age	Pregnant	Strand Location	Strand County
CSL 3708	Sammy	5/20/98	Released	11/5/98	F	Adult	No	Oceano Dunes	San Luis Obispo
CSL 3717	Thelma	5/21/98	Released	6/25/98	F	Adult	No	Monterey	Monterey
CSL 3719	Tick	5/21/98	Released	7/18/98	F	Adult	Yes	Oceano Dunes	San Luis Obispo
CSL 3720	Tack	5/21/98	Released	7/18/98	F	Juvenile	No	Oceano Dunes	San Luis Obispo
CSL 3727	Solo	5/21/98	Released	6/14/98	M	Subadult	NA	Oceano Dunes	San Luis Obispo
CSL 3731	Ju-Ni	5/22/98	Released	8/5/98	F	Adult	Yes	Oceano Dunes	San Luis Obispo
CSL 3733	Pentobarb	5/21/98	Released	8/5/98	M	Subadult	NA	Oceano Dunes	San Luis Obispo
CSL 3735	Septimus	5/22/98	Released	8/5/98	M	Juvenile	NA	Pismo Beach	San Luis Obispo
CSL 3752	Pistachio	5/23/98	Released	6/25/98	F	Adult	Yes	Oceano Dunes	San Luis Obispo
CSL 3754	Pecan	5/23/98	Released	6/25/98	F	Subadult	No	Oceano Dunes	San Luis Obispo
CSL 3755	Macadamia	5/23/98	Released	7/22/98	F	Adult	No	Oceano Dunes	San Luis Obispo
CSL 3767	Newton	5/24/98	Released	8/5/98	F	Adult	No	Monterey	Monterey
CSL 3769	Pascal	5/24/98	Released	8/2/98	F	Adult	Yes	Watsonville	Monterey
CSL 3775	Skipper	5/24/98	Released	6/20/98	F	Juvenile	No	Oceano Dunes	San Luis Obispo
CSL 3776	Professor	5/23/98	Released	6/22/98	M	Subadult	NA	Oceano Dunes	San Luis Obispo
CSL 3777	Howell	5/24/98	Released	6/25/98	F	Adult	No	Los Osos	San Luis Obispo
CSL 3792	Tara	5/24/98	Released	6/14/98	M	Juvenile	NA	Pismo Beach	San Luis Obispo
CSL 3795	Mellow	5/25/98	Released	6/22/98	M	Subadult	NA	Watsonville	Santa Cruz
CSL 3812	Esperanza	5/28/98	Released	11/5/98	F	Adult	No	Santa Cruz	Santa Cruz
CSL 3815	Mahjong	5/28/98	Released	11/5/98	F	Adult	No	Santa Cruz	Santa Cruz
CSL 3822	Salace	5/29/98	Released	11/5/98	F	Adult	No	Moss Landing	Monterey
CSL 3835	Punchy	5/30/98	Released	7/22/98	F	Adult	Yes	Pismo Beach	San Luis Obispo

Appendix 2A, Admit hematology																					
Acc #	Name	WBC	RBC	HGB	HCT	MCV	MCH	MCHC	segs	segs	bands	bands	lymph	lymph	monos	monos	eos	eos	baso	baso	plat
		x 10^3	x10^6	g/dl	%	fL	pg	g/dl	%	Abs	%	Abs	%	Abs	%	Abs	%	Abs	%	Abs	x 10^3
CSL 3708	Sammy	8.5	5.84	22.2	67.2	115.1	38	33	63	5.355	2	0.17	19	1.615	1	0.085	15	1.28	0	0	503
CSL 3717	Thelma	12.6	4.46	17.3	51.8	115.9	38.7	33.4	48	6.048	0	0	33	4.158	3	0.378	16	2.02	0	0	327
CSL 3719	Tick	14	3.56	15.5	39.3	110.4	43.5	39.4	63	8.82	0	0	23	3.22	7	0.98	7	0.98	0	0	392
CSL 3720	Tack	11.2	4.22	14.8	50.9	120.6	35.1	29.1	69	7.728	4	0.448	12	1.344	3	0.336	11	1.23	0	0	357
CSL 3727	Solo	11.8	4.5	17.5	53.3	118.4	38.9	32.8	70	8.26	1	0.118	16	1.888	13	1.534	0	0	0	0	246
CSL 3731	Ju-Ni	12.6	5.01	19.7	59.8	119.4	39.3	32.9	85	10.71	0	0	7	0.882	0	0	8	1.01	0	0	406
CSL 3735	Septimus	12.4	5.18	18.4	59.2	114.3	35.5	31.1	58	7.192	0	0	31	3.844	7	0.868	1	0.12	0	0	253
CSL 3752	Pistachio	12.5	4.84	18.3	52.9	109.3	37.8	34.6	81	10.13	0	0	12	1.5	2	0.25	5	0.63	0	0	319
CSL 3754	Pecan	13	5.7	21.1	60.6	106.3	37	34.8	61	7.93	0	0	19	2.47	7	0.91	13	1.69	0	0	199
CSL 3755	Macadamia	16.6	5.01	18.8	55.3	110.4	37.5	34	68	11.29	1	0.166	19	3.154	4	0.664	8	1.33	0	0	124
CSL 3767	Newton	13	4.67	17.7	58.9	126.1	37.9	30.1	64	8.32	0	0	25	3.25	10	1.3	1	0.13	0	0	258
CSL 3768	Skipper	9.4	4.68	16.3	54.3	116	34.8	30	52	4.888	0	0	21	1.974	11	1.034	13	1.22	2	0.19	125
CSL 3775	Toddy	18.3	4.24	15.9	48.6	114.6	37.5	32.7	84	15.73	2	0.366	12	2.196	1	0.183	0	0	0	0	214
CSL 3776	Professor	8.8	5.32	18.7	63.3	119	35.2	29.5	67	5.896	2	0.176	19	1.672	10	0.88	1	0.09	0	0	332
CSL 3795	Mellow	11.9	4.76	18.7	53.8	113	39.3	34.8	na	na	na	na	na	na	na	na	na	na	0	0	250
CSL 3812	Esparanza	10.4	5.18	20.2	68.1	131.5	39	29.7	76	7.904	3	0.312	13	1.352	5	0.52	3	0.31	0	0	206
CSL 3815	Mahjong	6.4	5.05	19.3	60.1	118.3	38	32.1	57	3.648	1	0.064	24	1.536	4	0.256	11	0.7	0	0	205
CSL 3822	Salace	10.1	4.68	18.1	58.4	124.8	38.7	31	72	7.272	4	0.404	15	1.515	3	0.303	4	0.4	1	0.06	430
CSL 3835	Punchy	10.2	4.73	17.7	50.5	106.8	37.4	35	51	5.202	1	0.102	27	2.754	4	0.408	14	1.43	0	0	359

Appendix 2B, Admit hematology																					
Acc #	Name	WBC	RBC	HGB	HCT	MCV	MCH	MCHC	segs	segs	bands	bands	lymph	lymph	monos	monos	eos	eos	baso	baso	plat
		x 10^3	x10^6	g/dl	%	fL	pg	g/dl	%	Abs	%	Abs	%	Abs	%	Abs	%	Abs	%	Abs	x 10^3
CSL 3700	Alexandra	11.1	5.52	21.4	59.3	108.3	38.8	35.8	80	8.88	0	0	10	1.11	1	0.111	9	0.999	0	0	353
CSL 3707	Franky	11.6	6.16	23.3	65.3	106	37.8	35.7	13	1.51	0	0	13	1.508	2	0.232	16	1.856	0	0	291
CSL 3721	Toe	11.2	3.62	13	41.6	114.9	35.9	31.3	64	7.17	3	0.336	12	1.344	3	0.336	18	2.016	0	0	339
CSL 3726	Pedwar	12.7	5.77	20.8	64.6	112	36	32.2	73	9.27	2	0.254	13	1.651	2	0.254	10	1.27	0	0	253
CSL 3729	Andromeda	9.1	5.16	19.5	55.7	107.9	37.8	35	75	6.83	0	0	14	1.274	0	0	11	1.001	0	0	732
CSL 3732	Neuf	5.5	4.09	15.6	44.6	109	38.1	35	61	3.36	4	0.22	23	1.265	3	0.165	8	0.44	0	0	73
CSL 3741	Lumberjack	14.7	4.24	16.7	51.2	120.8	39.4	32.6	57	8.38	4	0.588	8	1.176	4	0.588	27	3.969	0	0	333
CSL 3742	Chaos	4	4.52	18.1	56.8	125.7	40	31.9	84	3.36	0	0	13	0.52	3	0.12	0	0	0	0	129
CSL 3745	Thieran	12.2	4.5	16.3	46.4	109.8	36.2	33	68	8.3	1	0.122	21	2.562	4	0.488	6	0	0	0	234
CSL 3746	Finnegan	6.7	5.22	18.5	55.5	106.3	35.4	33.3	55	3.69	1	0.067	12	0.804	3	0.201	29	1.943	0	0	298
CSL 3747	Fiona	11.5	4.31	17.9	50.1	116.2	41.5	35.7	74	8.51	1	0.115	17	1.955	7	0.805	1	0.115	0	0	400
CSL 3749	Shamus	8.2	4.37	16.7	49.6	113.5	38.2	33.7	69	5.66	4	0.328	9	0.738	6	0.492	12	0.984	0	0	420
CSL 3760	Oatmeal	16.2	4.31	16.9	48.4	112.3	39.2	34.9	73	11.8	2	0.324	10	1.62	1	0.162	14	2.268	0	0	329
CSL 3768	Toddy	9.4	4.68	16.3	54.3	116	34.8	30	52	4.89	0	0	21	1.974	11	1.034	13	1.222	2	0.188	125
CSL 3770	Joule	9.8	4.28	15.5	51.4	120.1	36.2	36.2	82	8.04	5	0.49	10	0.98	3	0.294	0	0	0	0	74
CSL 3791	Neville	8.7	4.11	16.4	49.5	120.4	39.9	33	64	5.57	4	0.348	18	1.566	8	0.696	9	0.783	0	0	212
CSL 3793	Roller	16.9	4.99	19.6	64.2	128.7	39.3	30.5	67	11.3	2	0.338	13	2.197	14	2.366	4	0.676	0	0	163
CSL 3794	Muddy	9.5	4.19	16.3	56.9	135.8	38.9	28.6	77	7.32	5	0.475	14	1.33	2	0.19	2	0.19	0	0	193
CSL 3796	Kristen	18	5.05	19.7	56.8	112.5	39	34.7	78	14	1	0.18	2	0.36	1	0.18	18	3.24	0	0	307
CSL 3802	No Name	8.7	4.35	16.4	44.7	102.8	37.7	36.7	77	6.7	1	0.087	14	1.218	3	0.261	5	0.435	0	0	189
CSL 3804	Kitty	10.1	5.32	21.8	61.7	116	41	35.5	84	8.48	0	0	4	0.404	7	0.707	5	0.505	0	0	76
CSL 3806	Flower	8.2	4.89	19.9	54.6	111.7	40.7	36.4	69	5.66	6	0.492	11	0.902	9	0.738	5	0.41	0	0	265
CSL 3824	Sady	10.2	5.1	18.8	59.7	117.1	36.9	31.8	82	8.36	3	0.306	10	1.02	3	0.306	2	0.204	0	0	126
CSL 3901	Palm	11.8	4.57	17.4	52.6	115.1	38.1	33.1	55	6.49	0	0	27	3.186	5	0.59	13	1.534	0	0	344
CSL 3950	Athena	8.3	4.96	18.8	55.2	111.3	37.9	34.1	88	7.3	0	0	5	0.415	4	0.332	1	0.083	0	0	357

Appendix 2C, Admit Blood Chemistries

Acc. #	Name	Na	K	Cl	Glu	BUN	Creat	Prot	Alb	Glob	Ur. Ac.	Ca	Phos	Tot Bil	Dir Bil	GGT	Alk P	AST	ALT	LDH	Iron	Chol	Trigl	CK
		meq/l	meq/l	meq/l	mg/dl	mg/dl	mg/dl	gm/dl	gm/dl	gm/dl	mg/dl	mg/dl	mg/dl	mg/dl	mg/dl	mg/dl	u/l	u/l	u/l	u/l	mcg/dl	mg/dl	mg/dl	
CSL3699	Sallee	141	4	95	91	16	1.4	9.3	3	6.3	0.5	8.5	5.5	0.6	0.1	83	26	150	119	1599	46	246	75	na
CSL3700	Alexandra	142	4	96	88	16	1.4	9	3.1	5.9	0.5	8.7	4.7	0.4	0.1	62	45	204	116	2521	41	162	43	na
CSL 3708	Sammy	142	5.3	99	136	42	2.3	8.6	2.4	6.2	1.2	8.5	7.7	0.7	0.1	186	35	97	87	1567	22	253	82	na
CSL 3719	Tick	164	5.8	113	126	21	1.4	7.8	3.2	4.6	2.1	9	7.1	1.7	0.2	52	21	40	35	765	28	172	85	na
CSL 3720	Tack	143	5	100	103	22	1.4	9.8	3.5	6.3	3.1	9	7.6	2.4	0.1	87	12	56	39	1229	82	188	80	777
CSL 3721	Toe	143	5	10	103	22	1.4	9.8	3.5	6.3	3.1	9	7.6	2.4	0.1	87	12	56	39	1229	82	188	80	777
CSL 3724	Three	147	8.9	89	334	44	4.4	9.8	3.1	6.7	4.6	9.9	12	0.7	0.2	114	53	na	163	2664	193	190	90	na
CSL 3726	Pedwar	143	5.4	95	104	22	1.6	12.6	6.3	6.3	8.7	7.4	8.3	10	0.4	10	na	61	22	2958	na	247	284	na
CSL 3727	Solo	150	5.6	106	92	33	1.1	9	3.2	5.8	2	9	6.5	1.2	0.1	48	41	156	75	707	60	157	85	6288
CSL 3729	Andromeda	146	5.1	99	190	38	1.6	9.1	3.2	5.9	2.5	7.2	7.8	1.9	0.2	110	26	117	71	1747	79	216	97	1920
CSL 3731	Ju-Ni	157	5.3	105	113	16	1.6	11.2	5.6	5.6	6.9	8.4	7.8	7.7	1.5	19	na	125	41	2607	na	264	101	na
CSL 3732	Neuf	167	5	117	115	32	1.9	11.4	4.7	6.7	5	9.7	8.7	5.4	1.1	87	10	116	45	1561	165	212	186	na
CSL 3733	Pentobarb	151	4.8	105	121	14	1.3	8.3	33	6	2.6	8.6	7.8	1.8	0.2	51	20	149	67	1319	94	224	71	6367
CSL 3734	Benny	138	7.6	88	37	77	5.9	9.5	3.1	6.4	5.6	8.5	17	1.7	0.2	86	75	na	335	2761	92	162	111	na
CSL 3735	Septimus	149	4.8	111	70	62	0.9	8.7	3.2	5.5	3.8	8.6	6.5	2.4	0.2	76	45	81	82	952	220	186	215	750
CSL 3741	Lumberjack	148	5.2	100	77	21	1.7	7.4	2.7	4.7	1.2	8	9.5	0.5	0.2	72	37	83	65	1488	50	167	154	na
CSL 3745	Thieran	151	4.5	108	87	37	0.9	8.7	3	5.7	1.7	8.6	5.8	0.8	0.1	171	40	56	94	620	103	135	101	1033
CSL 3746	Finnegan	147	4.8	101	67	52	1.8	7.8	2.6	5.2	1.3	7.8	9.9	0.5	0.2	131	32	64	67	2250	66	206	115	na
CSL 3752	Pistachio	150	4.2	99	na	na	na	na	na	na	na	na	na	na	na	na	na	na	na	na	na	na	na	na
CSL 3754	Pecan	144	5.1	101	111	30	1.1	8.4	3	5.4	1.2	9.1	5.4	0.6	0.1	54	35	30	91	930	118	158	56	169
CSL 3795	Mellow	145	4.2	101	93	17	1.6	8.9	2.8	6.1	1.2	8.6	6.2	0.5	0.1	78	42	82	55	599	40	203	73	na
CSL 3801	Whisper	139	4.5	102	101	26	1.2	9.2	3.3	5.9	1.9	8.1	5.4	2.1	0.2	102	15	60	117	1606	135	181	57	311
CSL 3802	No Name	149	4.7	104	102	19	1.3	8.5	2.7	5.8	1.2	8.2	5.7	0.6	0.1	90	27	43	60	517	57	158	118	1311
CSL 3804	Kitty	151	4.7	100	167	37	1.5	8.3	2.8	5.5	1.5	8.4	6.9	1.3	0.2	137	26	70	80	885	101	213	50	623
CSL 3806	Flower	149	5.4	105	67	74	1.7	8.9	3	5.9	1.2	8.9	9	0.6	0.2	183	44	64	91	2075	43	184	100	912
CSL 3812	Esperanza	146	4.6	101	102	87	1.7	6.9	2.2	4.7	1.1	7.3	9.4	0.5	0.1	89	39	112	134	1762	132	107	46	na
CSL 3815	Mahjong	176	6.3	127	112	27	2.2	8.8	3.4	5.4	0.9	11	8.1	0.7	0.2	48	32	23	34	569	79	122	36	na
CSL 3822	Salace	159	5.4	111	106	19	0.6	8.99	3	6	na	9.8	7.8	0.78	na	na	31	90	83	na	na	112	na	na
CSL 3835	Punchy	158	6.1	118	115	17	1.4	6.8	2.4	4.4	1.1	8.9	7	0.9	0.2	52	27	81	51	1050	81	121	44	na
CSL 3901	Palm	167	6	112	90	66	3.1	10.2	3.3	6.9	1.2	11	12	0.5	0.2	105	34	56	30	760	96	288	62	na
CSL 3950	Athena	156	6.1	110	82	61	1.3	8.1	1.9	6.2	1.3	9.6	11	0.5	0.2	188	34	65	82	718	155	138	24	na

Appendix 3A Hematology, Pre-release

Acc #	Name	WBC	RBC	HGB	HCT	MCV	MCH	MCHC	segs	segs	bands	bands	lymph	lymph	monos	monos	eos	eos	baso	baso	plat
		x 10^3	x10^6	g/dl	%	fL	pg	g/dl	%	Abs	%	Abs	%	Abs	%	Abs	%	Abs	%	Abs	x 10^3
CSL 3709	Sammy	17.5	3.62	13	40.9	113	35.9	31.8	36	6.3	1	0.175	36	6.3	4	0.7	8	1.4	0	0	338
CSL 3717	Thelma	9.4	4.23	17	46.8	110.6	39	35.3	40	3.76	3	0.282	32	3.008	2	0.188	23	2.162	0	0	395
CSL 3719	Tick	13.5	4.44	17	47.7	107.4	37.8	35.2	60	8.1	0	0	20	2.7	11	1.485	9	1.215	0	0	297
CSL 3720	Tack	12.6	4.3	16	46.4	107.9	37.2	34.5	46	5.796	0	0	35	4.41	5	0.63	8	1.008	1	0.126	292
CSL 3727	Solo	11.8	4.5	18	53.3	118.4	38.9	32.8	70	8.26	1	0.118	16	1.888	13	1.534	0	0	0	0	411
CSL 3731	Ju-Ni	19.2	4.19	16	44.8	106.9	37.9	35.5	77	14.78	1	0.192	13	2.496	2	0.384	7	1.344	0	0	287
CSL 3733	Pentobarb	12.8	4.19	16	46.2	110.3	38.9	35.3	48	6.144	1	0.128	44	5.632	3	0.384	1	0.128	0	0	225
CSL 3735	Septimus	12.4	4.4	18	49.1	11.6	40.6	36.7	64	7.936	1	0.124	25	3.1	8	0.992	2	0.248	0	0	352
CSL 3752	Pistachio	10.9	4.95	19	52.4	105.9	38.8	36.6	53	5.777	6	0.654	33	3.597	6	0.654	1	0.109	0	0	300
CSL 3754	Pecan	16.7	5.11	19	53.5	104.7	37.2	35.5	40	6.68	4	0.668	42	7.014	4	0.668	6	1.002	2	0.334	262
CSL 3755	Macadamia	17.8	4.69	17	50.6	107.9	36.2	33.6	72	12.82	2	0.356	17	3.026	5	0.89	4	0.712	0	0	369
CSL 3767	Newton	13	4.67	18	58.9	126.1	37.9	30.1	64	8.32	0	0	25	3.25	10	1.3	1	0.13	0	0	258
CSL 3769	Pascal	11.1	3.96	16	45.4	114.6	39.6	34.6	68	7.548	0	0	23	2.553	5	0.555	1	0.111	0	0	292
CSL 3775	Skipper	15.5	4.21	16	46.2	109.7	37.5	34.2	78	12.09	2	0.31	12	1.86	4	0.62	4	0.62	0	0	333
CSL 3776	Professor	10.7	4.72	18	52.3	110.8	38.6	34.8	59	6.313	1	0.107	25	2.675	4	0.428	11	1.177	0	0	325
CSL 3792	Howell	15.3	4.2	16	43.7	103	37.4	35.9	87	13.31	2	0.306	7	1.071	2	0.306	2	0.306	0	0	358
CSL 3795	Tara	13.9	4.36	16	45.4	104.1	36	34.6	72	10.01	1	0.139	10	1.39	4	0.556	13	1.807	0	0	530
CSL 3812	Mellow	16.1	3.65	15	40.8	111.8	41.6	37.3	85	13.69	3	0.483	5	0.805	7	1.127	0	0	0	0	421
CSL 3815	Esperanza	6.6	4.76	18	48	100.8	38.7	38.3	80	5.28	0	0	11	0.726	3	0.198	1	0.066	0	0	305
CSL 3822	Mahjong	7.6	4.21	17	44.2	105	39.2	37.3	51	3.876	0	0	39	2.964	3	0.228	5	0.38	5	0.33	532
CSL 3835	Salace	9.8	5.2	21	56.7	109	41	37.6	63	6.174	2	0.196	29	2.842	2	0.196	6	0.588	2	0.152	412

Appendix 3B, Blood Chemistries, Pre-release

Acc. #	Name	Na	K	Cl	Glu	BUN	Creat	Prot	Alb	Glob	Uri Ac	Ca	Phos	Tot Bil	Dir Bil	GGT	AP	AST	ALT	LDH	Iron	Chol	Trigl
		meq/l	meq/l	meq/l	mg/dl	mg/dl	mg/dl	gm/dl	gm/dl	gm/dl	mg/dl	mg/dl	mg/dl	mg/dl	mg/dl	mg/dl	u/l	u/l	u/l	u/l	mcg/dl	mg/dl	mg/dl
CSL 3708	Sammy	144	4.3	101	3	39	1.8	10.9	2.3	8.6	1.4	9.8	8.4	0.3	0.1	209	46	91	72	1497	59	299	44
CSL 3717	Thelma	149	5.1	106	99	38	1.4	8.9	3.1	5.8	1.4	8.3	6.4	0.5	0.1	69	63	25	54	377	70	170	96
CSL 3719	Tick	149	4.9	102	86	33	1	9.3	3.1	6.2	2	9.1	7.4	0.9	0.1	50	42	52	64	852	146	230	140
CSL 3720	Tack	149	5.4	105	60	46	1.1	9.2	3.4	5.8	2.7	10	7.8	0.7	0.2	43	67	31	31	599	125	222	198
CSL 3727	Solo	150	5.6	106	92	33	1.1	9	3.2	5.8	2	9	6.5	1.2	0.1	48	41	156	75	707	60	157	85
CSL 3731	Ju-Ni	162	5.39	115	110	22.6	0.67	9.19	3.16	6.04	na	9.7	5.8	0.43	na	na	42	28	49	na	na	210	na
CSL 3733	Pentobarb	148	5.1	102	104	41	1.3	10.6	3.7	6.9	4.9	10	8.9	1.5	0.2	51	65	31	31	626	119	261	352
CSL 3735	Septimus	147	4.7	104	94	38	1.2	9.1	3.1	6	3.3	9.2	8.7	1.1	0.1	45	68	34	36	592	147	269	246
CSL 3752	Pistachio	143	5.3	97	99	15	1.7	8.8	3.2	5.6	1.2	9.1	6.3	0.7	0.2	51	23	23	23	617	43	196	35
CSL 3754	Pecan	156	5.2	108	82	48	1.2	9.8	3.3	6.5	2.7	10	9.3	0.9	0.1	na	32	73	47	57	584	164	209
CSL 3755	Macadamia	153	4.9	108	89	57	1	8.2	3	5.2	2.3	7.9	6.1	1	0.2	145	54	45	45	783	166	161	158
CSL 3767	Newton	146	4.7	104	55	36	1.1	9.7	2.8	6.9	2.2	8.6	5.4	0.5	0.1	59	41	39	43	692	115	148	118
CSL 3769	Pascal	151	5.3	112	73	46	1	8.9	2.9	6	3.1	9	7.1	1.7	0.2	83	33	38	38	915	124	182	196
CSL 3775	Skipper	147	4.7	111	86	61	1	8.9	2.9	6	2.3	9.2	5.5	1.2	0.2	92	30	33	50	392	115	141	179
CSL 3776	Professor	154	4.8	107	47	50	1	9.5	3.4	6.1	3.3	9	9.1	1.3	0.2	44	82	75	26	2689	138	178	166
CSL 3792	Howell	150	5.5	107	90	39	1.1	9.3	3.1	6.2	2	8.2	6.6	1.5	0.1	48	19	116	41	1198	101	188	77
CSL 3795	Tara	146	4.5	103	113	53	1.1	8.5	3	5.5	1.5	9.5	6.3	0.5	0.2	95	57	58	50	417	124	200	97
CSL 3812	Mellow	155	5.2	108	115	48	1.3	8.9	3.3	5.6	1.2	9.7	6.7	0.3	0.1	68	50	29	47	423	49	183	94
CSL 3815	Esperanza	149	3.7	105	119	15	1.7	8.4	2.4	6	0.6	8.2	4.5	0.4	0.1	43	37	14	16	440	53	148	20
CSL 3822	Mahjong	153	4.3	107	76	19	1.8	9.2	2.7	6.5	1.1	8.7	6.9	0.3	0.1	38	54	50	26	1972	82	123	na
CSL 3835	Salace	156	4.89	114	172	22.9	0.9	11.2	4.14	7.06	na	9.4	8.4	na	na	na	85	na	10	na	na	130	na

APPENDIX 4: Neurologic examination of the California sea lion

Acc. No: **Name:** **Date:** **Time:** **Observer:**

Posture
1. Sitting up on fore flippers
2. Recumbency: ventral, sternal, lateral R L, dorsal;
3. Body twisted to R L
4. Opisthotonus

Responsiveness
To audible or visual approach:
1. Charges person
2. Moves away at speed
3. Moves away hesitantly
4. Attempts to move but can't
5. Lifts head
6. Moves eyes to observe
7. No response
8. Seizuring

To touching lumbar area:
1. Does not allow due to aggressive behavior
2. Moves away rapidly
3. Moves away slowly
4. Lifts head
5. Attempts to move but unable
6. Unresponsive

Locomotion
Ground:
1. Moves rapidly around pen using all 4 flippers
2. Moves reluctantly around pen with all 4 flippers
3. Moves around pen but does not use hind-flippers
4. Ataxic
5. Scoots on ventrum without using fore-flippers
6. Attempts to get up on fore flippers but falls over
7. Unable to use fore and hind-flippers on same side (hemiplegia)
8. Circling
9. Immobile

Pool:
1. Swims normally, leaps over side of pool easily
2. Swims normally, gets out down ramp
3. Floats without using flippers
4. Cannot enter pool

APPENDIX 5: GROSS NECROPSY REPORTS

The Marine Mammal Center
Marin Headlands, GGNRA
Sausalito, CA 94965

GROSS NECROPSY REPORT

Acc#	CSL 3690
Name	Jakarta
Tag#	—
Species	Z. californianus

Form completed by	F. Gulland		
Strand location	Monterey Beach Motel		
Strand county	Monterey	Euthanasia	
Strand date	5-17-98	☐ Yes	☒ No
Admit date	5-18-98		
Death date	5-18-98	Time	before 2200
Post mortem date	5-19-98	Time	1200

Carcass classification: (2) - fresh
3 - fair, decomposed, organs intact
4 - poor, advanced decomposition
5 - mummified

Sex	F	SL 147 cm	BD 28 mm
Age	Adult	AG 103 cm	UG 90 cm
Weight	77.2 kg. (estimate/actual)		
SON	emaciated 1 2 3 (4) 5 6 7 obese		

Clinical signs/diagnosis	Seizures
Antibiotics given	Dual Pen
Pertinent lab results	None

Photos ☒

Radiographs ☐

MICROBIOLOGY

☒ Lung	2+ E coli, few enteric gram-rod, few non enteric gram-rod
☒ Liver	few E coli, rare enteric gram-rod
☒ Brain	RARE E coli
☐ Lymph node	
☐	

HISTOLOGY SAMPLES

(lung)	(gonad)
trachea	prostate
(heart)	(uterus)
aorta	penis
pulmonary artery	eye (L / R)
thymus	(brain)
(salivary gland)	spinal cord
(thyroid)	bone marrow
tonsil	(muscle)
tongue	skin
(oesophagus)	blubber
(stomach)	
duodenum	Lymph nodes:
(jejunum)	submandibular
(ileum)	cranial cervical
(colon)	prescapular
(pancreas)	axillary
(spleen)	(tracheobronchial)
(liver)	(hilar)
(gall bladder)	(gastric)
(adrenal)	hepatic
(kidney)	(mesenteric)
ureter	colonic
(urinary bladder)	sublumbar
urethra	inguinal
OTHER:	

Gross necropsy abnormalities: Tooth worm, flat on gums

- uterine horns similar size, no sign of pregnancy. Cervix smooth
- slight roughening of surface of vagina
- gastric mucosa deeppred; rugae swollen, 3 volcanic ulcers with purple mucosa around rim, laval nematodes in center.
- intestines empty, colon green pasty contents
- lungs diffusely congested (mild), mild interstitial edema
- Heart - all 4 chambers dilated, myocardium pale orange
- posterior vena cava distended with clotted blood
- Kidneys swollen, diffuse congestion at c:m junction
- urinary bladder empty
- Liver pale orange, friable, nutmeg pattern, margin paler.
- gallbladder distended with thick green bile.

TOPOGRAPHY	MORPHOLOGY	ETIOLOGY
1 Brain	Seizures	unknown
2 Kidney	Inflammation	unknown
3 Heart muscle - general	Pallor	unknown
4		
5		

Cause of death (preliminary diagnosis): Toxicosis

The Marine Mammal Center
Marin Headlands, GGNRA
Sausalito, CA 94965

GROSS NECROPSY REPORT

Acc#	CSL 3691
Name	Angelo
Tag#	—
Species	Zalophus californianus

Sex	F	SL 186 cm	BD 30 mm
Age	Adult	AG 106 cm	UG 100 cm
Weight	83.5 kg. (estimate/actual)		
SON	emaciated 1 2 3 4 5 (6) 7 obese		

Form completed by	J Gulland	
Strand location	Oceano Beach	
Strand county	SLO	Euthanasia ☐ Yes ☒ No
Strand date	5-18-98	
Admit date	5-18-98	
Death date	5-18-98	Time 1230
Post mortem date	5-19-98	Time 1030

Carcass classification:
2 - fresh
3 - fair, decomposed, organs intact
4 - poor, advanced decomposition
5 - mummified

Clinical signs/diagnosis	
Antibiotics given	
Pertinent lab results	

Photos ☐

Radiographs ☐

MICROBIOLOGY

☒ Lung - 1+ ples shigelloides, Ex RARE enteric gram - Rod

☒ Liver - few. pleisomonas shigelloide

☒ Brain - few ples shigelloids, RARE enteric gram - Rod

☐ Lymph node

☐

HISTOLOGY SAMPLES

lung, trachea, heart, aorta, pulmonary artery, thymus, salivary gland, thyroid, tonsil, tongue, oesophagus, stomach, duodenum, jejunum, ileum, colon, pancreas, spleen, liver, gall bladder, adrenal, kidney, ureter, urinary bladder, urethra, OTHER:

gonad, prostate, uterus, penis, eye (L / R), brain, spinal cord, bone marrow, muscle, skin, blubber

Lymph nodes: submandibular, cranial cervical, prescapular, axillary, tracheobronchial, hilar, gastric, hepatic, mesenteric, colonic, sublumbar, inguinal

Gross necropsy abnormalities:

- Lungs severely congested
- Stomach empty mucosa red, mucous + ~ 30 worms (Anisakidae) inside
- ileum empty, dilated gas. Colon contained black tarry material
- Liver mildly friable, slight nutmeg pattern
- Heart dilated, myocardium pale red. (R) ventricle + atrium distended.
- Skeletal muscle around temporomandibular joint pale red
- Hematoma ~ 1/2 cm x 1/2 cm over cranium (L) side.
- (L) uterine horn distended to 15 cm diameter, endometrium deep purple - ? site of placenta loss - Cervix open, deep purple
- mammary glands developed, no milk present.

TOPOGRAPHY	MORPHOLOGY	ETIOLOGY
1 Brain	Seizures	unknown
2 uterus	~~[illegible]~~ focal pattern	pregnancy
3		
4		
5		

Cause of death (preliminary diagnosis): unknown

The Marine Mammal Center
Marin Headlands, GGNRA
Sausalito, CA 94965

ROSS NECROPSY REPORT

Acc#	CSL 3692
Name	JORDAN
Tag#	—
Species	Zalophus californianus

Sex	F	SL 153 cm	BD 21 mm
Age	Adult	AG 80 cm	UG 94 cm
Weight	71 kg. (estimate/actual)		
SON	emaciated 1 2 (3) 4 5 6 7 obese		

Form completed by	J Guilland	
Strand location	Oceano Dunes State Park	
Strand county	San Luis Obispo	Euthanasia ☐ Yes ☐ No
Strand date	5/16/98	
Admit date	5/6/98	
Death date	5/17/98	Time overnight
Post mortem date	5/19/98	Time

Carcass classification: (2) - fresh
3 - fair, decomposed, organs intact
4 - poor, advanced decomposition
5 - mummified

Clinical signs/diagnosis	Seizuring. Brown mucus from mouth Dead on arrival
Antibiotics given	—
Pertinent lab results	—

ARCHIVES	
Bullets	#
Pellets	#
Gillnet/Line/Hooks/Rocks	

STORED SAMPLES		
Tissue See next sheet	Test	Sent to
Tissue	Test	Sent to
Tissue	Test	Sent to

HISTOLOGY SAMPLES

(lung)	gonad
trachea	prostate
(heart)	(uterus)
aorta	penis
pulmonary artery	eye (L / R)
thymus	(brain)
salivary gland	spinal cord
(thyroid)	bone marrow
(tonsil)	(muscle)
tongue	skin
oesophagus	blubber
(stomach)	
duodenum	Lymph nodes:
(jejunum)	(submandibular)
ileum	cranial cervical
colon	prescapular
(pancreas)	axillary
(spleen)	tracheobronchial
(liver)	(hilar)
(gall bladder)	(gastric)
adrenal	hepatic
(kidney)	(mesenteric)
ureter	colonic
(urinary bladder)	sublumbar
urethra	inguinal
OTHER:	

ANCILLARY DIAG	MICROBIOLOGY
☒ Photos	☒ Lung 1+ Enterobacteria cloacae, few E.coli
☐ Kidney smear	☒ Liver No growth
☒ Tooth for aging	☐ Intestine
☐ Radiographs	☐ Lymph node
☐ Parasites	☒ Brain 1+ Enterobacteria ; 1+ E.coli
	☒ Pericardial fluid - Rare Enterobacter cloacae Rare E.coli

Gross necropsy abnormalities:

- Bloody mucus in oral cavity and encrusted around lips
- Stomach dilated with gas, contained reddish brown mucus
- Rugae swollen, red multiple erosions 1-5mm diameter over all rugae. ~8 volcanic ulcers with raised purple rim 2cm diameter
- Intestines distended with gas, no ingesta
- Liver pale yellow, friable, nutmeg patter. Gall bladder distended with thick green/brown bile ~10 Zalophotrema flukes in bile duct.
- Kidneys swollen, moderate loss of renule definition, renal cortices pale tan, congestion at cortico medullary junction
- Urinary bladder empty. Uterus small, nonpregnant.
- Lungs diffusely congested
- Pericardial sac contained ~20cc clear reddish/brown fluid
- Epicardium covered in fibrin tags. myocardium pale orange colour.

TOPOGRAPHY	MORPHOLOGY	ETIOLOGY
1 Brain	Seizures	unknown
2 stomach	Hemorrhage	"
3 "	Ulceration & erosion	Anisakidae
4 Epicardium	fibrinous inflammation	unknown,
5		

Cause of death (preliminary diagnosis): unknown

The Marine Mammal Center
Marin Headlands, GGNRA
Sausalito, CA 94965

Fetus on attached sheet

GROSS NECROPSY REPORT

Acc#	CSW 3699
Name	Sallee
Tag#	—
Species	Zalophus californianus

Sex	F	SL 169 cm	BD 38 mm
Age	adult	AG 114 cm	UG 92 cm
Weight	74 kg. (estimate/actual)		
SON	emaciated 1 2 3 4 5 (6) 7 obese		

Form completed by	M. HAULENA	
Strand location	Oceano Dunes	
Strand county	SLO	Euthanasia
Strand date	5/19/98	☒ Yes ☐ No
Admit date	5/19/98	
Death date	5-20-98	Time 1300
Post mortem date	5-20-98	Time 1400

Carcass classification: (2) fresh
3 - fair, decomposed, organs intact
4 - poor, advanced decomposition
5 - mummified

Clinical signs/diagnosis	Seizures
Antibiotics given	Duel Pen
Pertinent lab results	AST(SGOT)=150 U/L, ALT(SGPT)=119 U/L

Photos ☐

Radiographs ☐

HISTOLOGY SAMPLES

lung	gonad
trachea	prostate
heart	uterus
aorta	penis
pulmonary artery	eye (L / R)
thymus	brain
salivary gland	spinal cord
thyroid	bone marrow
tonsil	muscle
tongue	skin
oesophagus	blubber
stomach	
duodenum	Lymph nodes:
jejunum	submandibular
ileum	cranial cervical
colon	prescapular
pancreas	axillary
spleen	tracheobronchial
liver	hilar
gall bladder	gastric
adrenal	hepatic
kidney	mesenteric
ureter	colonic
urinary bladder	sublumbar
urethra	inguinal

OTHER:

MICROBIOLOGY

- ☒ Lung - RARE E. coli, Ex RARE non enteric gram- Rod.
- ☒ Liver - FEW E. coli
- ☒ Brain RARE E. coli, RARE PROTEUS MIRABILIS
- ☒ Tonsil - RARE E. coli
- ☒ ~~Lymph node~~ heart - RARE E. coli
- ☒ Uterine fluid
- ☒ Pericardial fluid - Ex RARE E. coli
- ☒ Kidney swab - Ex RARE E. coli, Ex non-enteric gram- Rod

Gross necropsy abnormalities:

KIDNEYS - M2 PALE, SWOLLEN, M3 LOSS OF RENAL DIFFERENTIATION WITH A 3.0cm HYDRONEPHROTIC CYST ON CRANIAL POLE OF (R) KIDNEY

LUNGS - M2-3 GENERALIZED CONGESTION AND CONSOLIDATION

GALL BLADDER - M2 THICKENING OF WALL

STOMACH - M2-3 THICK MUCOPURULENT YELLOW-GREEN FLUID

UTERUS - NEAR-TERM PREGNANCY - SEE FETUS NECROPSY REPORT
- DARK RED, FRIABLE PLACENTOMES
- BROWNISH-TINGED FLUID SURROUNDING FETUS

LIVER - M2-3 ENLARGED LIVER

TOPOGRAPHY	MORPHOLOGY	ETIOLOGY
1 Brain	Seizures	unknown
2 uterus	pregnant	—
3		
4		
5		

Cause of death (preliminary diagnosis): seizures / UNKNOWN / INTERSTITIAL NEPHRITIS / GASTRITIS

The Marine Mammal Center
Marin Headlands, GGNRA
Sausalito, CA 94965

GROSS NECROPSY REPORT

Acc#	CSL 3649 F
Name	fetus
Tag#	—
Species	Zalophus californianus

Sex	F	SL	69 cm	BD	1 mm
Age	neonate	AG	36 cm	UG	41 cm
Weight	6 kg. (estimate/actual)				
SON	emaciated 1 2 3 4 5 6 7 obese				

Form completed by	Diane Paschall		
Strand location	Oceano Dunes		
Strand county	SLO	Euthanasia	☐ Yes ☒ No
Strand date	5-19-98		
Admit date	5-19-98		
Death date	5-20-98	Time	1200
Post mortem date	5-20-98	Time	1500

Carcass classification: (2) - fresh
3 - fair, decomposed, organs intact
4 - poor, advanced decomposition
5 - mummified

Clinical signs/diagnosis	Mother euthanized.
Antibiotics given	—
Pertinent lab results	—

Photos ☒

Radiographs ☐

HISTOLOGY SAMPLES

(lung)	(gonad)
(trachea)	prostate
(heart)	(uterus)
(aorta)	penis
(pulmonary artery)	eye (L / R)
(thymus)	(brain)
salivary gland	spinal cord
(thyroid)	bone marrow
tonsil	muscle
(tongue)	skin
(oesophagus)	blubber
(stomach)	
(duodenum)	Lymph nodes:
(jejunum)	submandibular
(ileum)	cranial cervical
(colon)	prescapular
(pancreas)	axillary
(spleen)	tracheobronchial
(liver)	hilar
(gall bladder)	gastric
(adrenal)	hepatic
(kidney)	mesenteric
ureter	colonic
(urinary bladder)	sublumbar
urethra	inguinal

OTHER:

MICROBIOLOGY

☐ Lung

☐ Liver

☐ Brain

☐ Lymph node

Pericardial fluid - Rare E coli, from this - Enterococcus
☐ Umbilicus - Rare non-enteric gram-rod

Gross necropsy abnormalities:

10cc blood tinged fluid in pericardium, trachea bronchi filled c. fluid
other
No significant findings

TOPOGRAPHY	MORPHOLOGY	ETIOLOGY
1		
2		
3		
4		
5		

Cause of death (preliminary diagnosis): Euthanasia.

The Marine Mammal Center
Marin Headlands, GGNRA
Sausalito, CA 94965

GROSS NECROPSY REPORT

Acc#	CSL 3700
Name	Alexandra
Tag#	—
Species	Zalophus californianus

Sex	F	SL 161 cm	BD 24 mm
Age	Adult	AG 90 cm	UG 78 cm
Weight	64.5 kg. (estimate/actual)		
SON	emaciated 1 2 3 4 5 (6) 7 obese		

Form completed by	M. HAULENA / D. PASCHALL		
Strand location	Oceano Dunes		
Strand county	SLO	Euthanasia	
Strand date	5-19-98	☒ Yes	☐ No
Admit date	5-19-98		
Death date	5-20-98	Time 1200	
Post mortem date	5-20-98	Time 1230	

Carcass classification: (2) - fresh
3 - fair, decomposed, organs intact
4 - poor, advanced decomposition
5 - mummified

Clinical signs/diagnosis	Seizures
Antibiotics given	Dual Pen
Pertinent lab results	None

Photos ☒

Radiographs ☐

HISTOLOGY SAMPLES

(lung) (trachea) (heart) (aorta) (pulmonary artery) thymus (salivary gland) (thyroid) (tonsil) (tongue) (oesophagus) (stomach) (duodenum) (jejunum) (ileum) (colon) (pancreas) (spleen) (liver) (gall bladder) (adrenal) (kidney) ureter (urinary bladder) urethra

(gonad) prostate (uterus) penis (eye (L/(R)) (brain) spinal cord bone marrow (muscle) (skin) (blubber)

Lymph nodes: (submandibular) cranial cervical (prescapular) (axillary) tracheobronchial (hilar) (gastric) hepatic mesenteric colonic (sublumbar) (inguinal)

OTHER:

MICROBIOLOGY

☒ Lung - NO GROWTH

☒ Liver 2+ ecoli, 1+ non enteric gram-rod, few proteus mirabilis few enterococcus

☐ ~~Brain~~ Stomach - rare nonenteric gram-rod

Pericardial fluid - few non-enteric gram-rod, rare non-enteric #2

☒ ~~Lymph node~~ Heart - rare-E coli; non-enteric gram-rod, rare non enteric #2

☒ Tonsil - rare E coli, few enterococcus, rare non-enteric gram-rod

X Brain - few E coli few non enteric gram-rod, rare non enteric #2

Gross necropsy abnormalities:

Tonsils enlarged; musculature in neck pale, all lymph nodes gelatinous, gastric sl. enlarged; trachea + bronchi mucosa red/purple; lungs congested, granulomas, interstitial edema, 1+ Parafilaroides; thin dark bile in gallbladder; liver capsule white, edema, liver pale and severely swollen; small red flecks on spleen; pancreas sl. swollen; stomach filled with clear/yellow thick tenacious mucous fluid; mucosa white/brown; duodenum filled with bright yellow fluid

HEART - RAISED ~2mm SOFT EDEMATOUS, DARK YELLOW PLAQUES UP TO 10cm DIAMETER COVERING ~70% OF OA EPICARDIUM, DO NOT PENETRATE MYOCARDIUM ON CUT SURFACE, ~50 ml OF BLOOD-TINTED FLUID IN PERICARDIAL SAC

EYES - OD, M3 KERATITIS WITH CORNEAL OPACIFICATION, NEOVASCULARIZATION

KIDNEYS - M1-2 SWOLLEN, M2 ~~HEMORRHAGE~~ HEMORRHAGE AT C:M JUNCTION

TOPOGRAPHY	MORPHOLOGY	ETIOLOGY
1 Brain	Seizures	unknown
2 Epicardium	fibrinous inflammation	unknown
3		
4		
5		

Cause of death (preliminary diagnosis): UNKNOWN / EPICARDITIS | Toxicosis

The Marine Mammal Center
Marin Headlands, GGNRA
Sausalito, CA 94965

GROSS NECROPSY REPORT

Acc#	CSL3707
Name	Franky
Tag#	—
Species	Zalophus Californianus

Form completed by	J Gulland		
Strand location	Oceano Dunes		
Strand county	SLO	Euthanasia	
Strand date	5/20/98	☒ Yes	☐ No
Admit date	5/20/98		
Death date	5/21/98	Time	8:00
Post mortem date	5/21/98	Time	12:00

Carcass classification: (2) fresh
3 - fair, decomposed, organs intact
4 - poor, advanced decomposition
5 - mummified

Sex	M	SL 151 cm	BD 28 mm
Age	Subadult	AG 89 cm	UG 71 cm
Weight	64 kg. (estimate/actual)		
SON	emaciated 1 2 3 (4) 5 6 7 obese		

Clinical signs/diagnosis	pupils dilated, grand mal seizures
Antibiotics given	Penicillin
Pertinent lab results	wbc 11.6 17% bands

Photos ☐

Radiographs ☐

MICROBIOLOGY

- ☒ Lung
- ☐ Liver
- ☐ Brain
- ☐ Lymph node
- ☐

HISTOLOGY SAMPLES

(lung)	(gonad)
trachea	prostate
(heart)	uterus
aorta	penis
pulmonary artery	eye (L / R)
thymus	(brain)
(salivary gland)	(spinal cord)
(thyroid)	bone marrow
(tonsil)	(muscle)
(tongue)	skin
(oesophagus)	blubber
(stomach)	
(duodenum)	Lymph nodes:
(jejunum)	(submandibular)
(ileum)	cranial cervical
(colon)	prescapular
(pancreas)	axillary
(spleen)	tracheobronchial
(liver)	(hilar)
(gall bladder)	(gastric)
(adrenal)	hepatic
(kidney)	(mesenteric)
ureter	colonic
(urinary bladder)	sublumbar
urethra	inguinal
OTHER:	

Gross necropsy abnormalities:

- stomach contained bloodtinged grey mucus. ~20 Anisakids in stomach
- myocardium pale, ~~two~~ all chambers of heart engorged with blood. ~ 5cc clear orange fluid in pericardial sac.
- lungs mildly congested
- tongue and oropharynx appear congested.
- No other abnormalities detected

TOPOGRAPHY	MORPHOLOGY	ETIOLOGY
1 Brain	Seizures	unknown
2 Stomach	Hemorrhage	unknown
3 Heart muscle - general	pallor	unknown
4		
5		

Cause of death (preliminary diagnosis): Toxicosis

The Marine Mammal Center
Marin Headlands, GGNRA
Sausalito, CA 94965

GROSS NECROPSY REPORT

Acc#	CSL 3709
Name	Dean
Tag#	—
Species	Zalophus californianus

Form completed by	F. Gulland.		
Strand location	Oceano Dunes		
Strand county	SLO	Euthanasia	
Strand date	5-20-98	☐ Yes	☒ No
Admit date	5-20-98		
Death date	5-20-98	Time 2300	
Post mortem date	5-21-98	Time 1300	

Carcass classification: (2) fresh
3 - fair, decomposed, organs intact
4 - poor, advanced decomposition
5 - mummified

Sex	F	SL 159 cm	BD 17 mm
Age	adult	AG 100 cm	UG 86 cm
Weight	76 kg. (estimate/actual)		
SON	emaciated 1 2 (3) 4 5 6 7 obese		

Clinical signs/diagnosis	Seizures
Antibiotics given	Dual Pen
Pertinent lab results	—

Photos ☐

Radiographs ☐

MICROBIOLOGY

☒ Lung No growth 96 hrs

☐ Liver

☐ Brain

☐ Lymph node

☐

HISTOLOGY SAMPLES

(lung)	(gonad)
(trachea)	prostate
(heart)	(uterus)
(aorta)	penis
pulmonary artery	eye (L / R)
thymus	(brain)
(salivary gland)	(spinal cord)
(thyroid)	bone marrow
tonsil	(muscle)
(tongue)	skin
oesophagus	blubber
(stomach)	
(duodenum)	Lymph nodes:
(jejunum)	(submandibular)
(ileum)	cranial cervical
(colon)	prescapular
(pancreas)	axillary
(spleen)	(tracheobronchial)
(liver)	hilar
(gall bladder)	(gastric)
adrenal	hepatic
(kidney)	(mesenteric)
ureter	colonic
(urinary bladder)	sublumbar
urethra	inguinal
OTHER:	

Gross necropsy abnormalities:

Pale pink oral mucous membranes, inflamed worn to gum level, 2 upper incisors missing. Red mucoid material in oropharynx. Nasopharyngeal mucosa red congested. Mucosa over arytenoids congested. Submandibular (LN) congested enlarged. Lungs diffusely mildly congested with slight interstitial edema. Myocardium pale, hemorrhage in wall of (L) ventricle extending ~2mm from outer surface into myocardium. All chambers of heart engorged. Gallbladder distended with thick black/orange bile. Balophorema in bile duct and canaliculi of liver. Spleen constricted. Rugae of stomach swollen, red, mild erosions of rugae, 2 volcanic ulcers with Anisakid larvae in centre. ~50 Anisakids in stomach. Kidneys swollen, renal cortices pale tan. (L) uterine wall has thickened area ~2cm x 2cm

TOPOGRAPHY	MORPHOLOGY	ETIOLOGY
1 Brain	Seizures	unknown
2 Lung	Edema	
3		
4		
5		

Cause of death (preliminary diagnosis): Toxicosis

The Marine Mammal Center
Marin Headlands, GGNRA
Sausalito, CA 94965

GROSS NECROPSY REPORT

Acc#	CSL 3721
Name	TOE
Tag#	13070
Species	ZALOPHUS CALIFORNIANUS

Sex	F	SL 170 cm	BD 12 mm
Age	adult	AG 99 cm	UG 92 cm
Weight	67.5 kg. (estimate/actual)		
SON	emaciated 1 2 (3) 4 5 6 7 obese		

Form completed by	T. SPRAKER / M. HAULENA		
Strand location	OCEANO DUNES		
Strand county	SAN LUIS OBISPO	Euthanasia	
Strand date	5/21/98	☒ Yes	☐ No
Admit date	5/21/98		
Death date	6/3/98	Time	11:00 am
Post mortem date	6/3/98	Time	11:00 am

Carcass classification: (2) fresh
3 - fair, decomposed, organs intact
4 - poor, advanced decomposition
5 - mummified

Clinical signs/diagnosis	seizures, anorexia
Antibiotics given	DUAL-PEN
Pertinent lab results	EOSINOPHILIA ~ 18%

Photos ☐

Radiographs ☐

HISTOLOGY SAMPLES ✓

lung	gonad
trachea	prostate
heart	uterus
aorta	penis
pulmonary artery	eye (L / R)
thymus	brain
salivary gland	spinal cord
thyroid	bone marrow
tonsil	muscle
tongue	skin
oesophagus	blubber
stomach	
duodenum	Lymph nodes:
jejunum	submandibular
ileum	cranial cervical
colon	prescapular
pancreas	axillary
spleen	tracheobronchial
liver	hilar
gall bladder	gastric
adrenal	hepatic
kidney	mesenteric
ureter	colonic
urinary bladder	sublumbar
urethra	inguinal
OTHER:	

MICROBIOLOGY

☐ Lung

☐ Liver

☐ Brain

☐ Lymph node

☒ pharynx culture taken - 3+ E. coli, 1+ Klebsiella pneum. 1+ non enteric gram ⊖ rod prob. Morg.

Gross necropsy abnormalities:

heart valves: A/V of left side - thickening (mild)
uterine horn: (R) side thickened wall
gastric ulcers: 7, +4 round worms
Meckel's Diverticulum
gall bladder: flukes

tox samples + virology + domoic acid samples taken

TOPOGRAPHY	MORPHOLOGY	ETIOLOGY
1 BRAIN	SEIZURES	UNKNOWN
2 VALVES OF HEART	HYPERTROPHY	UNKNOWN
3		
4		
5		

Cause of death (preliminary diagnosis): UNKNOWN / TOXICOSIS

The Marine Mammal Center
Marin Headlands, GGNRA
Sausalito, CA 94965

GROSS NECROPSY REPORT

Acc#	CSL 3724
Name	THREE
Tag#	—
Species	Zalophus

Form completed by	Dan Fletcher		
Strand location	Oceano Dunes		
Strand county	SLO	Euthanasia	
Strand date	5/21/98	☐ Yes	☒ No
Admit date	5/21/98		
Death date	5/22/98	Time 0600	
Post mortem date	5/23/98	Time 1200	

Carcass classification: (2) fresh
3 - fair, decomposed, organs intact
4 - poor, advanced decomposition
5 - mummified

Sex	F	SL 174 cm	BD 21 mm
Age	Adult	AG 111 cm	UG 111 cm
Weight	99.5 kg. (estimate/actual)		
SON	emaciated 1 2 3 4 (5) 6 7 obese		

Clinical signs/diagnosis	Seizures
Antibiotics given	Dual Pen
Pertinent lab results	

Photos ☒

Radiographs ☐

MICROBIOLOGY

☐ Lung

☐ Liver

☐ Brain

☐ Lymph node

☐

HISTOLOGY SAMPLES

(lung)	(gonad)
(trachea)	prostate
(heart)	(uterus)
(aorta)	penis -
(pulmonary artery)	eye (L / R)
thymus	(brain)
(salivary gland)	spinal cord
(thyroid)	bone marrow
(tonsil)	muscle
(tongue)	skin
(oesophagus)	blubber
(stomach)	
(duodenum)	Lymph nodes:
(jejunum)	(submandibular)
(ileum)	(cranial cervical)
(colon)	(prescapular)
(pancreas)	(axillary)
(spleen)	(tracheobronchial)
(liver)	(hilar)
(gall bladder)	(gastric)
(adrenal)	(hepatic)
(Kidney)	(mesenteric)
ureter	(colonic)
(urinary bladder)	(sublumbar)
urethra	(inguinal)
OTHER:	
(hard palate)	

Gross necropsy abnormalities:

+ all lymph nodes hemorrhagic and some necrotic
+ full term fetus - placenta necrotic.
+ Kidneys - surface hemorrhage, severe loss of tubule diff, swollen
+ myocardium very pale
+ adrenal medulla very pale cortex stretched
+ lungs dark purple, red foam in trachea + bronchi
+ ulcers on hard palate.

+ Fetus 10Kg, 77cm Standard length, AG 48cm, UG 50cm
Fetal tissues labelled 3724F

TOPOGRAPHY	MORPHOLOGY	ETIOLOGY
1 Brain	Seizures	unknown
2 Lymphnodes	Inflamation	unknown
3 Heart muscle - general	Pallor	unknown
4 Uterus	pregnant	—
5		

Cause of death (preliminary diagnosis): ? Toxicosis

The Marine Mammal Center
Marin Headlands, GGNRA
Sausalito, CA 94965

GROSS NECROPSY REPORT

Acc#	OSL 3724F
Name	Fetus
Tag#	
Species	Z. californianus

Sex		SL 77 cm	BD mm
Age		AG 48 cm	UG 50 cm
Weight	10 kg. (estimate/actual)		
SON	emaciated 1 2 3 4 5 6 7 obese		

Form completed by			
Strand location			
Strand county		Euthanasia ☐ Yes ☐ No	
Strand date			
Admit date			
Death date		Time	
Post mortem date	5-23-98	Time	

Carcass classification:
2 - fresh
3 - fair, decomposed, organs intact
4 - poor, advanced decomposition
5 - mummified

Clinical signs/diagnosis	
Antibiotics given	
Pertinent lab results	

Photos ☐

Radiographs ☐

HISTOLOGY SAMPLES

lung	gonad
trachea	prostate
heart	uterus
aorta	penis
pulmonary artery	eye (L / R)
thymus	brain
salivary gland	spinal cord
thyroid	bone marrow
tonsil	muscle
tongue	skin
oesophagus	blubber
stomach	
duodenum	Lymph nodes:
jejunum	submandibular
ileum	cranial cervical
colon	prescapular
pancreas	axillary
spleen	tracheobronchial
liver	hilar
gall bladder	gastric
adrenal	hepatic
kidney	mesenteric
ureter	colonic
urinary bladder	sublumbar
urethra	inguinal
OTHER:	

MICROBIOLOGY

☐ Lung

☐ Liver

☐ Brain

☐ Lymph node

☐

Gross necropsy abnormalities:

ELD tox on back →

TOPOGRAPHY	MORPHOLOGY	ETIOLOGY
1		
2		
3		
4		
5		

Cause of death (preliminary diagnosis): Intrauterine death

The Marine Mammal Center
Marin Headlands, GGNRA
Sausalito, CA 94965

GROSS NECROPSY REPORT

Acc#	CSL 3725
Name	Two
Tag#	—
Species	Z-californianus

Form completed by	J Gulland		
Strand location	Post 4, Oceano Dunes		
Strand county	SLO	Euthanasia	
Strand date	5/21/98	☐ Yes	☒ No
Admit date	5/21/98		
Death date	5/22/98	Time overnight	
Post mortem date	5/23/98	Time 15:00	

Carcass classification: (2) fresh
3 - fair, decomposed, organs intact
4 - poor, advanced decomposition
5 - mummified

Sex	F	SL 167 cm	BD 22 mm
Age	Adult	AG 110 cm	UG 118 cm
Weight	98 kg. (estimate/actual)		
SON	emaciated 1 2 3 4 5 (6) 7 obese		

Clinical signs/diagnosis	Seizuring on beach, seizures unresponsive to valium, died
Antibiotics given	—
Pertinent lab results	—

Photos ☐

Radiographs ☐

MICROBIOLOGY

☐ Lung

☐ Liver

☐ Brain

☐ Lymph node

☐

HISTOLOGY SAMPLES

lung	gonad
trachea	prostate
heart	uterus
aorta	penis
pulmonary artery	eye (L / R)
thymus	brain
salivary gland	spinal cord
thyroid	bone marrow
tonsil / hard palate	muscle / diaphragm
tongue	skin
oesophagus	blubber
stomach	
duodenum	Lymph nodes:
jejunum	submandibular
ileum	cranial cervical
colon	prescapular
pancreas	axillary
spleen	tracheobronchial
liver	hilar
gall bladder	gastric
adrenal	hepatic
kidney	mesenteric
ureter	colonic
urinary bladder	sublumbar
urethra	inguinal
OTHER:	

Gross necropsy abnormalities:
- 1mm dia ulcers over hard palate
- pregnant. Fetus - 8kg ♂, 70cm long, Axillary 41cm, Umbi girth 43cm
- masseter muscle pale
- myocardium pale.
- kidneys swollen, hemorrhage on surface of both kidneys
- blood tinged foam in trachea + bronchi
- mild congestion of lungs
- multiple volcanic ulcers in stomach.
- all lymphnodes appear congested

Fetal tissues labeled 3725 F

TOPOGRAPHY	MORPHOLOGY	ETIOLOGY
1 Brain	seizures	unknown
2 Stomach	ulceration + erosion	"
3 Kidney	Inflammation	"
4 Heart muscle - general	Pallor	"
5		

Cause of death (preliminary diagnosis): ? Toxicosis? open.

The Marine Mammal Center
Marin Headlands, GGNRA
Sausalito, CA 94965

ROSS NECROPSY REPORT

Acc#	CSL 3725F
Name	Fetus
Tag#	
Species	Z. californianus

Sex		SL 70 cm	BD mm
Age		AG 41 cm	UG 43 cm
Weight	9 kg. (estimate/actual)		
SON	emaciated 1 2 3 4 5 6 7 obese		

Form completed by		
Strand location		
Strand county		Euthanasia ☐ Yes ☐ No
Strand date		
Admit date		
Death date		Time
Post mortem date	5-23-98	Time

Carcass classification:
2 - fresh
3 - fair, decomposed, organs intact
4 - poor, advanced decomposition
5 - mummified

Clinical signs/diagnosis	
Antibiotics given	
Pertinent lab results	

Photos ☐

Radiographs ☐

HISTOLOGY SAMPLES

lung	gonad
trachea	prostate
heart	uterus
aorta	penis
pulmonary artery	eye (L / R)
thymus	brain
salivary gland	spinal cord
thyroid	bone marrow
tonsil	muscle
tongue	skin
oesophagus	blubber
stomach	
duodenum	Lymph nodes:
jejunum	submandibular
ileum	cranial cervical
colon	prescapular
pancreas	axillary
spleen	tracheobronchial
liver	hilar
gall bladder	gastric
adrenal	hepatic
kidney	mesenteric
ureter	colonic
urinary bladder	sublumbar
urethra	inguinal
OTHER:	

MICROBIOLOGY

☐ Lung

☐ Liver

☐ Brain

☐ Lymph node

☐

Gross necropsy abnormalities:

ELD tox on back →

TOPOGRAPHY	MORPHOLOGY	ETIOLOGY
1		
2		
3		
4		
5		

Cause of death (preliminary diagnosis): Intrauterine death

The Marine Mammal Center
Marin Headlands, GGNRA
Sausalito, CA 94965

GROSS NECROPSY REPORT

Acc#	CSL3726
Name	Pedwar
Tag#	~~CSL~~ 13021
Species	Zalophus californianus

Sex	F	SL 176 cm	BD 21 mm
Age	Adult	AG 105 cm	UG 75 cm
Weight	83.5 kg. (estimate/actual)		
SON	emaciated 1 2 3 (4) 5 6 7 obese		

Form completed by	Spraker		
Strand location	Oceano Dunes		
Strand county	SLO	Euthanasia	
Strand date	5/21/98	☒ Yes	☐ No
Admit date	5/21/98		
Death date	2 June 98	Time 8:30	
Post mortem date	"	Time 8:30	

Carcass classification: (2 - fresh) 3 - fair, decomposed, organs intact; 4 - poor, advanced decomposition; 5 - mummified

Clinical signs/diagnosis	
Antibiotics given	
Pertinent lab results	

Photos ☐

Radiographs ☐

HISTOLOGY SAMPLES

lung	gonad
trachea	prostate
heart	uterus
aorta	penis
pulmonary artery	eye (L / R)
thymus	brain
salivary gland	spinal cord
thyroid	bone marrow
tonsil	muscle
tongue	skin
oesophagus	blubber
stomach	
duodenum	Lymph nodes:
jejunum	submandibular
ileum	cranial cervical
colon	prescapular
pancreas	axillary
spleen (Spraker)	tracheobronchial
liver	hilar
gall bladder	gastric
adrenal	hepatic
kidney	mesenteric
ureter	colonic
urinary bladder	sublumbar
urethra	inguinal
OTHER:	

MICROBIOLOGY

☐ Lung

☐ Liver

☐ Brain

☐ Lymph node

☐

Gross necropsy abnormalities:

- not lactating
- right horn uterus large - ~10-12 days post-parturition
- ♀ - crusta ulcer - +3 small red. stom + feed lam.
- adrenals - OK
  inguinal ~ slightly enlarged
  TONSIL - NSL

TOPOGRAPHY	MORPHOLOGY	ETIOLOGY
1 Brain	seizures	domoic acid
2 Uterus	focal pattern	pregnancy
3		
4		
5		

Cause of death (preliminary diagnosis): Toxicosis due to domoic acid

The Marine Mammal Center
Marin Headlands, GGNRA
Sausalito, CA 94965

GROSS NECROPSY REPORT

Acc#	CSL 3729
Name	ANDROMEDA
Tag#	13153
Species	Zalophus californianus

Sex	F	SL 190 cm	BD 10 mm
Age	Adult	AG 98 cm	UG 78 cm
Weight	88 kg.	(estimate/actual)	
SON	emaciated 1 2 3 4 5 6 7 obese		

Form completed by	Spraker		
Strand location	Monterey St. Beh		
Strand county	Monterey	Euthanasia	
Strand date	5/22/98	☑ Yes	☐ No
Admit date	5/22/98		
Death date	1 June '98	Time 16:30	
Post mortem date	1 June 98	Time 16:30	

Carcass classification: 2 - fresh
3 - fair, decomposed, organs intact
4 - poor, advanced decomposition
5 - mummified

Clinical signs/diagnosis	Repeated seizures
Antibiotics given	penicillin
Pertinent lab results	CK 1920

Photos ☐

Radiographs ☐

HISTOLOGY SAMPLES

lung	gonad
trachea	prostate
heart	uterus
aorta	penis
pulmonary artery	eye (L / R)
thymus	brain
salivary gland	spinal cord
thyroid	bone marrow
tonsil	muscle
tongue	skin
oesophagus	blubber
stomach	
duodenum	Lymph nodes:
jejunum	submandibular
ileum	cranial cervical
colon	prescapular
pancreas	axillary
spleen (Spraker)	tracheobronchial
liver	hilar
gall bladder	gastric
adrenal	hepatic
kidney	mesenteric
ureter	colonic
urinary bladder	sublumbar
urethra	inguinal
OTHER:	

MICROBIOLOGY

☐ Lung

☐ Liver

☐ Brain

☐ Lymph node

☐

Gross necropsy abnormalities:

- Flukes in bile duct with severe bile duct hyperplasia
- Sev. Acanthocephalid in SI
- Tapes in ileum/caecum
- Severe large plaques of fibrin on the epicardium of the left ventricle
- ~~All other~~ small amount of fibrin in left eye - posterior chamber
- subcut edema - right chest - (injection site)

TOPOGRAPHY	MORPHOLOGY	ETIOLOGY
1 Brain	Seizures	Domoic acid
2 Eye	Inflamation	unknown
3		
4		
5		

Cause of death (preliminary diagnosis): Toxicosis due to domoic acid

The Marine Mammal Center
Marin Headlands, GGNRA
Sausalito, CA 94965

GROSS NECROPSY REPORT

Acc#	CSL 3731 fetus
Name	— stillborn
Tag#	CSL-13121-F
Species	Cal Sea Lion

Sex	F	SL 81 cm	BD 6 mm
Age	Stillbirth	AG 41 cm	UG 42 cm
Weight	6.8 kg. (estimate/actual)		
SON	emaciated 1 2 3 (4) 5 6 7 obese		

Form completed by	Sprauer	
Strand location	-	
Strand county	-	Euthanasia ☐ Yes ☒ No
Strand date	-	
Admit date	-	
Death date		Time
Post mortem date	6-2-98	Time

Carcass classification:
2 - fresh
3 - fair, decomposed, organs intact
4 - poor, advanced decomposition
5 - mummified

Clinical signs/diagnosis	- female gone birth to still birth
Antibiotics given	
Pertinent lab results	at 9:00AM 2 June 98 PMI - Ohr.

Photos ☐

Radiographs ☐

MICROBIOLOGY

☐ Lung

☐ Liver

☐ Brain

☐ Lymph node

☐

HISTOLOGY SAMPLES

lung	gonad
trachea	prostate
heart	uterus
aorta	penis
pulmonary artery	eye (L / R)
thymus	brain
salivary gland	spinal cord
thyroid	bone marrow
tonsil	muscle
tongue	skin
oesophagus	blubber
stomach	
duodenum	Lymph nodes:
jejunum	submandibular
ileum	cranial cervical
colon	prescapular
pancreas	axillary
spleen	tracheobronchial
liver	hilar
gall bladder	gastric
adrenal	hepatic
kidney	mesenteric
ureter	colonic
urinary bladder	sublumbar
urethra	inguinal
OTHER:	

Gross necropsy abnormalities:

- Female fetus
- Severe congestion of head
- hair slippage
PMD - ~2 day (appr.)

NGL - large normal thymus

TOPOGRAPHY	MORPHOLOGY	ETIOLOGY
1 Lung	Atelectasis	stillbirth
2		
3		
4		
5		

Cause of death (preliminary diagnosis): stillbirth

NEUF CSL 3732

The Marine Mammal Center
Marin Headlands, GGNRA
Sausalito, CA 94965

GROSS NECROPSY REPORT

Acc#	CSL 3732
Name	NEUF
Tag#	1313
Species	Z.C

Form completed by	S. Rommel		
Strand location	Oceano Dunes		
Strand county	SLO	Euthanasia	
Strand date	5-22-98	☐ Yes	☒ No
Admit date	5-22-98		
Death date	6-22-98	Time 2130	
Post mortem date	23 Jun 98	Time -	

Sex	F	SL 142 cm	BD 2 mm
Age	Adult	AG 60 cm	UG 54 cm
Weight	29 kg. (estimate/actual)		
SON	emaciated (1) 2 3 4 5 6 7 obese		

Carcass classification: (2) - fresh
3 - fair, decomposed, organs intact
4 - poor, advanced decomposition
5 - mummified

Clinical signs/diagnosis	weak, seizures
Antibiotics given	penicillin
Pertinent lab results	—

Photos ☐

Radiographs ☐

HISTOLOGY SAMPLES

(lung)	(gonad)
(trachea)	prostate
(heart)	(uterus)
(aorta)	penis
(pulmonary artery)	(eye (L)/R)
(thymus)	(brain)
(salivary gland)	(spinal cord)
(thyroid)	bone marrow
(tonsil)	(muscle)
(tongue)	(skin)
(oesophagus)	blubber
(stomach)	
(duodenum)	Lymph nodes:
(jejunum)	(submandibular)
(ileum)	cranial cervical
(colon)	(prescapular)
(pancreas)	(axillary)
(spleen)	(tracheobronchial)
(liver)	hilar
(gall bladder)	(gastric)
(adrenal)	hepatic
(kidney)	(mesenteric)
ureter	(colonic)
(urinary bladder)	(sublumbar)
urethra	(inguinal)
OTHER:	

MICROBIOLOGY

☐ Lung

☐ Liver

☐ Brain

☐ Lymph node

☐

Gross necropsy abnormalities:

- SMALL BLACK CLOTS WITH OMENTUM - BLACK FLUID IN ABDOMEN - all ABDOMINAL lymn enlarged & REACTIVE
- ABUNDANT SUBDERMAL EDEMA - enlarged lymn nodes -
- adrenals enlarged
- gastric mucosa dark black - ACK
- RED MUCOSA SMALL INTESTINE

TOPOGRAPHY	MORPHOLOGY	ETIOLOGY
1 Brain	seizures	unknown
2 omentum	inflammation	unknown
3		
4		
5		

Cause of death (preliminary diagnosis): unknown. Await histology - suspect toxicosis

The Marine Mammal Center
Marin Headlands, GGNRA
Sausalito, CA 94965

GROSS NECROPSY REPORT

Acc#	CSL 3734
Name	Benny
Tag#	—
Species	Z. californianus

Sex	F	SL 137 cm	BD 21 mm
Age	3 yr	AG 82 cm	UG 64 cm
Weight	52 kg. (estimate/actual)		
SON	emaciated 1 2 3 (4) 5 6 7 obese		

Form completed by	J Gulland		
Strand location	Grand Avenue, Oceano		
Strand county	S.L.O.	Euthanasia	
Strand date	5/22/98	☐ Yes	☒ No
Admit date	5/22/98		
Death date	5/23/98	Time	12:00
Post mortem date	5/23/98	Time	15:00

Carcass classification: (2) fresh
3 - fair, decomposed, organs intact
4 - poor, advanced decomposition
5 - mummified

Clinical signs/diagnosis	Head waving, white froth from mouth, seizures
Antibiotics given	penicillin
Pertinent lab results	—

Photos ☒

Radiographs ☐

HISTOLOGY SAMPLES

(lung)	(gonad)
trachea	prostate
(heart)	(uterus)
(aorta)	penis
pulmonary artery	eye (L / R)
thymus	(brain)
(salivary gland)	spinal cord
(thyroid)	bone marrow
(tonsil)	(muscle)
(tongue)	skin
(oesophagus)	blubber
(stomach)	
(duodenum)	Lymph nodes:
(jejunum)	(submandibular)
(ileum)	(cranial cervical)
(colon)	prescapular
(pancreas)	axillary
(spleen)	(tracheobronchial)
(liver)	(hilar)
(gall bladder)	(gastric)
(adrenal)	hepatic
(kidney)	(mesenteric)
ureter	colonic
(urinary bladder)	sublumbar
urethra	inguinal
OTHER:	

MICROBIOLOGY

☐ Lung

☐ Liver

☐ Brain

☐ Lymph node

☐

Gross necropsy abnormalities:

- (L) neck circular lesion 10 x 7 cm of alopecia, hyperkeratosis, hyperpigmentation
- center of skin lesion ulcerated
- Submandibular LN enlarged, edematous
- liver pale, slightly friable with faint reticular pattern on surface
- gall bladder full, thick green/black bile inside
- stomach contained frank blood. Rugae swollen, deep red, multiple 1mm diam. erosions over entire surface. 4 volcanic ulcers ~10 Anisakids in center of ulcers.
- Intestines + colon contained black tarry material
- Blood tinged mucus in esophagus
- ~~lungs mildly congested~~
- myocardium pale pink, all chambers of heart engorged with blood
- mild cerebral edema

TOPOGRAPHY	MORPHOLOGY	ETIOLOGY
1 skin	alopecia	unknown
2 stomach	ulceration + erosion	"
3 stomach	hemorrhage	"
4 brain	seizures	unknown
5		

Cause of death (preliminary diagnosis): ? Toxicosis ?

The Marine Mammal Center
Marin Headlands, GGNRA
Sausalito, CA 94965

GROSS NECROPSY REPORT

Acc#	CSL 3736
Name	EIGHT
Tag#	—
Species	ZALOPHUS

Sex	M	SL 112 cm	BD 24 mm
Age	2-3 yrs	AG 72 cm	UG 67 cm
Weight	32 kg. (estimate/actual)		
SON	emaciated 1 2 (3) 4 5 6 7 obese		

Form completed by	Dan Fletcher	
Strand location	OCEANO DUNES	
Strand county	SLO	Euthanasia ☐ Yes ☒ No
Strand date	5/22/98	
Admit date	5/22/98	
Death date	5/22/98	Time 1500
Post mortem date	5/23/98	Time 1400

Carcass classification: (2) - fresh; 3 - fair, decomposed, organs intact; 4 - poor, advanced decomposition; 5 - mummified

Clinical signs/diagnosis	Seizures, thick brown mucous from mouth, labored breathing
Antibiotics given	Duel Pen
Pertinent lab results	

Photos ☒

Radiographs ☐

HISTOLOGY SAMPLES

lung, trachea, heart, aorta, pulmonary artery, thymus, salivary gland, thyroid, tonsil, tongue, oesophagus, stomach, duodenum, jejunum, ileum, colon, pancreas, spleen, liver, gall bladder, adrenal, kidney, ureter, urinary bladder, urethra

gonad, prostate, uterus, penis, eye (L / R), brain, spinal cord, bone marrow, muscle, skin, blubber

Lymph nodes: submandibular, cranial cervical, prescapular, axillary, tracheobronchial, hilar, gastric, hepatic, mesenteric, colonic, sublumbar, inguinal

OTHER:

MICROBIOLOGY

☐ Lung

☐ Liver

☐ Brain

☐ Lymph node

☐

Gross necropsy abnormalities:

+ lungs congested, interstitial edema

+ kidneys swollen mild loss of tubule differentiation.

+ Slightly pale myocardium
bloody ~~effusion~~ fluid in pericardium

+ Congested vessels in cerebrum.

TOPOGRAPHY	MORPHOLOGY	ETIOLOGY
1 Brain	seizures	unknown
2 ~~Heart~~ muscle - general	pallor	unknown
3 pericardium	effusion	unknown
4		
5		

Cause of death (preliminary diagnosis): ? TOXICOSIS ?

The Marine Mammal Center
Marin Headlands, GGNRA
Sausalito, CA 94965

GROSS NECROPSY REPORT

Acc#	CSL 3741
Name	Lumberjack
Tag#	13180
Species	Zalophus californianus

Sex	F	SL 143 cm	BD 34 mm
Age	Adult	AG 106 cm	UG 86 cm
Weight	79.5 kg.	(estimate/actual) 5/23	
SON	emaciated 1 2 3 4 (5) 6 7 obese		

Form completed by	J.A. McMillan		
Strand location	Boardwalk		
Strand county	Monterey	Euthanasia	
Strand date	5/23/98	☐ Yes	☒ No
Admit date	5/23/98		
Death date	5-29-98	Time found @ STEF	0830
Post mortem date	5-29-98	Time	1000

Carcass classification: (2 - fresh) 3 - fair, decomposed, organs intact
4 - poor, advanced decomposition
5 - mummified

Clinical signs/diagnosis	Seizuring on beach. Dead on arrival
Antibiotics given	—
Pertinent lab results	—

Photos ☐

Radiographs ☐

HISTOLOGY SAMPLES

(lung)	(gonad)
(trachea)	prostate
(heart) x-sect.	(uterus)
(aorta)	penis
pulmonary artery	(eye (L/R)) Both
thymus	(brain)
salivary gland	(spinal cord)
thyroid	bone marrow
(onsil)	muscle
tongue	skin
(oesophagus)	blubber
(stomach)	
(duodenum)	Lymph nodes:
(jejunum)	(submandibular)
(ileum)	(cranial cervical)
(colon)	(prescapular)
(pancreas)	(axillary)
(spleen)	tracheobronchial
(liver)	(hilar)
gall bladder	(gastric)
(adrenal)	hepatic
(kidney)	(mesenteric)
ureter	(colonic)
(urinary bladder)	sublumbar
urethra	(inguinal)
OTHER:	(pancreatic)

MICROBIOLOGY

☐ Lung

☐ Liver

☐ Brain

☐ Lymph node

☐

Gross necropsy abnormalities:

Very enlarged edematous inguinal lymph nodes both

- Congested lungs

- See Full necropsy sheet.

(Fetus Female - See Separate Sheet

TOPOGRAPHY	MORPHOLOGY	ETIOLOGY
1 Brain	Seizures	Unknown
2		
3		
4		
5		

Cause of death (preliminary diagnosis): ? Toxicosis

The Marine Mammal Center
Marin Headlands, GGNRA
Sausalito, CA 94965

ROSS NECROPSY REPORT

Acc#	CSL 3741 F
Name	Fetus
Tag#	
Species	Z. californianus

Sex	F	SL 71 cm	BD mm
Age	Fetus	AG 43 cm	UG 37 cm
Weight	7 kg. (estimate/actual)		
SON	emaciated 1 2 3 4 5 6 7 obese		

Form completed by			
Strand location			
Strand county		Euthanasia ☐ Yes ☐ No	
Strand date			
Admit date			
Death date		Time	
Post mortem date	5-29-98	Time	

Carcass classification:
2 - fresh
3 - fair, decomposed, organs intact
4 - poor, advanced decomposition
5 - mummified

Clinical signs/diagnosis	
Antibiotics given	
Pertinent lab results	

Photos ☐

Radiographs ☐

HISTOLOGY SAMPLES

lung	gonad
trachea	prostate
heart	uterus
aorta	penis
pulmonary artery	eye (L / R)
thymus	brain
salivary gland	spinal cord
thyroid	bone marrow
tonsil	muscle
tongue	skin
oesophagus	blubber
stomach	
duodenum	Lymph nodes:
jejunum	submandibular
ileum	cranial cervical
colon	prescapular
pancreas	axillary
spleen	tracheobronchial
liver	hilar
gall bladder	gastric
adrenal	hepatic
kidney	mesenteric
ureter	colonic
urinary bladder	sublumbar
urethra	inguinal
OTHER:	

MICROBIOLOGY

☐ Lung

☐ Liver

☐ Brain

☐ Lymph node

☐

Gross necropsy abnormalities:

dead inside CSL 3741 on post mortem

TOPOGRAPHY	MORPHOLOGY	ETIOLOGY
1		
2		
3		
4		
5		

Cause of death (preliminary diagnosis): Intrauterine death

The Marine Mammal Center
Marin Headlands, GGNRA
Sausalito, CA 94965

_28 lbs

GROSS NECROPSY REPORT

Acc#	CSL 3742
Name	CHAOS
Tag#	13186
Species	Zalophus Californianus

Sex	F	SL 175 cm	BD 20 mm
Age	old Ad.	AG 109 cm	UG 95 cm
Weight	83.6 kg. (estimate/actual)		
SON	emaciated 1 2 3 (4) 5 6 7 obese		

Form completed by	A. Forrestine		
Strand location	Del Monte Beach		
Strand county	Monterey	Euthanasia	
Strand date	5/23/98	☒ Yes	☐ No
Admit date	5/23/98		
Death date	31 May 98	Time	16:00
Post mortem date	31 May 98	Time	16:00

Carcass classification: (2) fresh
3 - fair, decomposed, organs intact
4 - poor, advanced decomposition
5 - mummified

Clinical signs/diagnosis	Seizures
Antibiotics given	
Pertinent lab results	

Photos ☐

Radiographs ☐

MICROBIOLOGY NONE

☐ Lung

☐ Liver

☐ Brain

☐ Lymph node

☐

HISTOLOGY SAMPLES

(lung) (trachea) (heart) (aorta) pulmonary artery (thymus) (salivary gland) (thyroid) (tonsil) (tongue) (oesophagus) (stomach) (duodenum) (jejunum) (ileum) (colon) (pancreas) (spleen) (liver) (gall bladder) (adrenal) (kidney) ureter (urinary bladder) urethra OTHER:

(gonad) ~~prostate~~ (uterus) ~~penis~~ BOWINS (eye (L / R)) (brain) (spinal cord C_1) bone marrow (muscle) ? skin blubber

Lymph nodes: (submandibular) (cranial cervical) (prescapular) (axillary) (tracheobronchial) hilar (gastric) (hepatic) (mesenteric) ~~colonic~~ (sublumbar) (inguinal)

Gross necropsy abnormalities:

1. Pale mucous membranes
Swollen flippers (fat!)
Edema in inguinal / caudal tibial area
Pulmonary interstitial & pleural opacification (fibrosis)
Mitral & tricuspid valve endocardiosis & fibrosis
Left atrial endocardial fibrosis
(blood in pericardial sac 20 to cardiac puncture - agonal)
5 volcano ulcers in stomach c̄ rare parasites
Uterine mural thickening bilateral
Leiomyoma, external, cervix
Mild mineralization renal capsule & adrenal capsule
No gross lesions in CSF

TOPOGRAPHY	MORPHOLOGY	ETIOLOGY
1 Brain	Seizures	Domoic acid
2		
3		
4		
5		

Cause of death (preliminary diagnosis): ? Toxicosis due to domoic acid

NB - HAS 2nd sheet for fetus

The Marine Mammal Center
Marin Headlands, GGNRA
Sausalito, CA 94965

GROSS NECROPSY REPORT

Acc#	3743 CSL
Name	DOA
Tag#	Yellow 562, band 1873
Species	Zalophus Californianus

Form completed by	Collins / Gulland		
Strand location	South of parking lot		
Strand county	Monterey	Euthanasia	☐ Yes ☒ No
Strand date	5-23-98		
Admit date	5-23-98		
Death date	5-23 98	Time	overnight
Post mortem date	5-24-98	Time	15:00

Carcass classification: (2) - fresh
3 - fair, decomposed, organs intact
4 - poor, advanced decomposition
5 - mummified

Sex	F	SL 149 cm	BD 40 mm
Age	Adult	AG 61 cm	UG 60 cm
Weight	98 kg. (estimate/actual)		
SON	emaciated 1 2 3 4 5 (6) 7 obese		

Clinical signs/diagnosis	seizures onset. Died in transit
Antibiotics given	—
Pertinent lab results	

Photos ☐

Radiographs ☐

HISTOLOGY SAMPLES

(lung)	(gonad)
trachea	prostate
(heart)	(uterus)
aorta	penis
pulmonary artery	eye (L / R)
thymus	(brain)
(salivary gland)	spinal cord
(thyroid)	bone marrow
(tonsil)	(muscle)
(tongue)	skin
(oesophagus)	blubber
(stomach)	
(duodenum)	Lymph nodes:
jejunum	(submandibular)
(ileum)	cranial cervical
(colon)	prescapular
(pancreas)	axillary
(spleen)	(tracheobronchial)
(liver)	(hilar)
(gall bladder)	(gastric)
(adrenal)	hepatic
(kidney)	(mesenteric)
ureter	colonic
(urinary bladder)	sublumbar
urethra	inguinal
OTHER:	

MICROBIOLOGY

☐ Lung

☐ Liver

☐ Brain

☐ Lymph node

☐

Gross necropsy abnormalities: pregnant. Fetus — see sheet 3743 F
• petechial hemorrhages over fetal membranes. Amniotic fluid clear
• GI tract empty. gastric mucosa deep red, congested, with focal areas of erosion 1-5mm diameter. 4 volcanic ulcers. ~20 nematodes in gastric lumen
• Bloodtinged mucus in stomach, esophagus, oropharynx
• Tonsils enlarged, deep purple
• gastric & mesenteric LN
• Liver has nutmeg pattern over surface
• urinary bladder empty

TOPOGRAPHY	MORPHOLOGY	ETIOLOGY
1 Brain	Seizures	unknown
2		
3		
4		
5		

Cause of death (preliminary diagnosis): Toxicosis ?

The Marine Mammal Center
Marin Headlands, GGNRA
Sausalito, CA 94965

GROSS NECROPSY REPORT

Acc#	3743 f
Name	DOA F
Tag#	—
Species	Zalop. Californianus

Sex	M	SL 72	cm	BD 4	mm
Age	Kits	AG 40	cm	UG 31	cm
Weight	6.0 kg. (estimate/actual)				
SON	emaciated 1 (2) 3 4 5 6 7 obese				

Form completed by	gulard		
Strand location	AS CSL 3743		
Strand county		Euthanasia	
Strand date		☐ Yes	☒ No
Admit date			
Death date	5-24-98	Time	
Post mortem date	5-24-98	Time	

Carcass classification:
2 - fresh
3 - fair, decomposed, organs intact
4 - poor, advanced decomposition
5 - mummified

Clinical signs/diagnosis	
Antibiotics given	
Pertinent lab results	

Photos ☐

Radiographs ☐

HISTOLOGY SAMPLES

(lung)	gonad
trachea	prostate
heart	uterus
aorta	penis
pulmonary artery	eye (L / R)
(thymus)	brain
salivary gland	spinal cord
thyroid	bone marrow
tonsil	muscle
tongue	skin
oesophagus	blubber
stomach	
duodenum	Lymph nodes:
jejunum	submandibular
ileum	cranial cervical
colon	prescapular
pancreas	axillary
(spleen)	tracheobronchial
(liver)	hilar
gall bladder	gastric
adrenal	hepatic
(kidney)	mesenteric
ureter	colonic
urinary bladder	sublumbar
urethra	inguinal
OTHER:	

MICROBIOLOGY

☐ Lung

☐ Liver

☐ Brain

☐ Lymph node

☐

Gross necropsy abnormalities:

- Appears fresh, No significant abnormalities detected.
- Blubber → Teflon → −40° c.
- H

TOPOGRAPHY	MORPHOLOGY	ETIOLOGY
1		
2		
3		
4		
5		

Cause of death (preliminary diagnosis): Intrauterine death

The Marine Mammal Center
Marin Headlands, GGNRA
Sausalito, CA 94965

GROSS NECROPSY REPORT

Acc#	CSL 3744
Name	REID
Tag#	—
Species	Z. californianus

Form completed by	J Gulland		
Strand location	Marina Beach		
Strand county	Monterey	Euthanasia	
Strand date	5/23/98	☐ Yes	☒ No
Admit date	5/23/98		
Death date	5/23/98	Time	—
Post mortem date	5/24/98	Time	12-00

Carcass classification: (2) fresh
3 - fair, decomposed, organs intact
4 - poor, advanced decomposition
5 - mummified

Sex	F	SL	152 cm	BD	86 mm
Age	Adult	AG	90 cm	UG	72 cm
Weight	80 kg. (estimate/actual)				
SON	emaciated 1 2 3 4 (5) 6 7 obese				

Clinical signs/diagnosis	
Antibiotics given	
Pertinent lab results	

Photos ☐

Radiographs ☐

HISTOLOGY SAMPLES

(lung)	(gonad)
trachea	prostate
(heart)	(uterus)
aorta	penis
pulmonary artery	eye (L / R)
(thymus)	(brain)
(salivary gland)	(spinal cord)
(thyroid)	bone marrow
(tonsil)	muscle
(tongue)	skin
(oesophagus)	blubber
(stomach)	
(duodenum)	Lymph nodes:
jejunum	(submandibular)
(ileum)	cranial cervical
(colon)	prescapular
(pancreas)	axillary
(spleen)	(tracheobronchial)
(liver)	hilar
gall bladder	(gastric)
(adrenal)	hepatic
(kidney)	(mesenteric)
ureter	colonic
(urinary bladder)	sublumbar
urethra	inguinal
OTHER:	

MICROBIOLOGY

☐ Lung

☐ Liver

☐ Brain

☐ Lymph node

☐

Gross necropsy abnormalities: stomach distended w/ gas
Stomach mucosa red, rugae swollen, severe ulceration, frank blood in lumen. No ingesta present. Gastric lymphnodes enlarged, edematous, hemorrhagic.
- intestines empty, distended with gas
- Tonsils enlarged
- lungs mildly congested with mild interstitial edema
- spleen constricted
- myocardium pale with focal white lesion 1mm diameter on surface of (L) ventricle
- (R) uterine horn has band of purple tissue ~1cm wide. ? previous pregnancy?

TOPOGRAPHY	MORPHOLOGY	ETIOLOGY
1 Brain	Seizures	unknown
2 Heart muscle general	Pallor	unknown
3 " " "	Focal pathom	"
4 uterus	" "	
5		

Cause of death (preliminary diagnosis): ? Toxicosis ?

The Marine Mammal Center
Marin Headlands, GGNRA
Sausalito, CA 94965

GROSS NECROPSY REPORT

Acc#	OL 3746
Name	FINNEGAN
Tag#	RFF 13164
Species	CSL

Sex	♀	SL 172 cm	BD 6 mm
Age	Adult	AG 90 cm	UG 74 cm
Weight	83 kg. (estimate/actual)		
SON	emaciated 1 2 3 (4) 5 6 7 obese		

Form completed by	T. Spraker		
Strand location	Oceano Dunes		
Strand county	SLO	Euthanasia	
Strand date	5/22/98	☒ Yes	☐ No
Admit date	5/22/98		
Death date	6/1/98	Time	11:00
Post mortem date	6/1/98	Time	12:00

Carcass classification: (2 - fresh) 3 - fair, decomposed, organs intact
4 - poor, advanced decomposition
5 - mummified

Clinical signs/diagnosis	
Antibiotics given	
Pertinent lab results	

Photos ☐

Radiographs ☐

HISTOLOGY SAMPLES

lung	gonad
trachea Spraker	prostate
heart	uterus
aorta	penis
pulmonary artery	eye (L / R)
thymus	brain
salivary gland	spinal cord
thyroid	bone marrow
tonsil	muscle
tongue	skin
oesophagus	blubber
stomach	
duodenum	Lymph nodes:
jejunum	submandibular
ileum	cranial cervical
colon	prescapular
pancreas	axillary
spleen	tracheobronchial
liver	hilar
gall bladder	gastric
adrenal	hepatic
kidney	mesenteric
ureter	colonic
urinary bladder	sublumbar
urethra	inguinal
OTHER:	

MICROBIOLOGY

☐ Lung

☐ Liver

☐ Brain

☐ Lymph node

☐

Gross necropsy abnormalities:

Esopagus - 2mm raised lesion in proximal portion
Epicardium - fibrin on surface ~~may be associated with euthanasia~~
R Kidney - one 2cm x 1cm cyst
Stomach - fundus - one volcanic ulcers c few Nematodes -
- few trapes ~~&~~ acanocephalus or SI
- edema or subcut
- not pregnant
thicken wall of gall with flukes

TOPOGRAPHY	MORPHOLOGY	ETIOLOGY
1 Brain	siezures	~~unknown~~ Domoic acid
2 Kidney	cyst	unknown
3		
4		
5		

Cause of death (preliminary diagnosis): ? Toxicosis due to domoic acid

The Marine Mammal Center
Marin Headlands, GGNRA
Sausalito, CA 94965

GR S NECROPSY REPORT

Acc#	3746 f
Name	Fetus Still born
Tag#	—
Species	Zalop. Calif.

Sex	M	SL 76 cm	BD 2 mm
Age	Fetus	AG 37 cm	UG 40 cm
Weight	7.0 kg. (estimate/actual)		
SON	emaciated 1 2 (3) 4 5 6 7 obese		

Form completed by	J Gulland	
Strand location	see 3746 CSL (Bomat Tmmc)	
Strand county	" "	Euthanasia ☐ Yes ☒ No
Strand date (MOY)	5/23/98	
Admit date (MOY)	5/23/98	
Death date	5/25/98	Time 0730
Post mortem date	5/25/98	Time 20.30

Carcass classification: (2) - fresh
3 - fair, decomposed, organs intact
4 - poor, advanced decomposition
5 - mummified

Clinical signs/diagnosis	
Antibiotics given	
Pertinent lab results	

ARCHIVES	
Bullets	#
Pellets	#
Gillnet/Line/Hooks/Rocks	

STORED SAMPLES		
Tissue blubliniked	Test tox	Sent to ECD
Tissue	Test	Sent to
Tissue	Test	Sent to

HISTOLOGY SAMPLES	
lung	gonad
trachea	prostate
heart	uterus
aorta	penis
pulmonary artery	eye (L / R)
thymus	brain
salivary gland	spinal cord
thyroid	bone marrow
tonsil	muscle
tongue	skin
oesophagus	blubber
stomach	
duodenum	Lymph nodes:
jejunum	submandibular
ileum	cranial cervical
colon	prescapular
pancreas	axillary
spleen	tracheobronchial
liver	hilar
gall bladder	gastric
adrenal	hepatic
kidney	mesenteric
ureter	colonic
urinary bladder	sublumbar
urethra	inguinal
OTHER:	

ANCILLARY DIAG	MICROBIOLOGY
☐ Photos	☐ Lung
☐ Kidney smear	☐ Liver
☐ Tooth for aging	☐ Intestine
☐ Radiographs	☐ Lymph node
☐ Parasites	☐ Brain
	☐

Gross necropsy abnormalities:

TOPOGRAPHY	MORPHOLOGY	ETIOLOGY
1		
2		
3		
4		
5		

Cause of death (preliminary diagnosis): Intrauterine death

The Marine Mammal Center
Marin Headlands, GGNRA
Sausalito, CA 94965

fetus on attached sheet

GROSS NECROPSY REPORT

Acc#	CSL 3747
Name	Fiona
Tag#	13199
Species	Zalophus californianus

Sex	female	SL 176 cm	BD 28 mm
Age	Adult	AG 109 cm	UG 102 cm
Weight	100.5 kg. (estimate/actual)		
SON	emaciated 1 2 3 4 5 (6) 7 obese		

Form completed by	Guano	
Strand location	Ocean	
Strand county	SLO	Euthanasia
Strand date	5/22/98	☒ Yes ☐ No
Admit date	5/22/98	
Death date	6/2/98	Time 15-30
Post mortem date	6/2/98	Time 16-00

Carcass classification:
(2) - fresh
3 - fair, decomposed, organs intact
4 - poor, advanced decomposition
5 - mummified

Clinical signs/diagnosis	
Antibiotics given	
Pertinent lab results	

Photos ☐

Radiographs ☐

HISTOLOGY SAMPLES

Spreader

lung	gonad
trachea	prostate
heart	uterus
aorta	penis
pulmonary artery	eye (L / R)
thymus	brain
salivary gland	spinal cord
thyroid	bone marrow
tonsil	muscle
tongue	skin
oesophagus	blubber
stomach	
duodenum	Lymph nodes:
jejunum	submandibular
ileum	cranial cervical
colon	prescapular
pancreas	axillary
spleen	tracheobronchial
liver	hilar
gall bladder	gastric
adrenal	hepatic
kidney	mesenteric
ureter	colonic
urinary bladder	sublumbar
urethra	inguinal
OTHER:	

MICROBIOLOGY

☐ Lung

☐ Liver

☐ Brain

☐ Lymph node

☐

Gross necropsy abnormalities:

- Pregnant in left uterus - severely edematous 9cm rupture of base of Right uterine horn
- Placenta darkened, hemorrhagic + congested
- Right ovary small + inactive + left ovary is active with CL
- Seven volcanic ulcers present in stomach

TOPOGRAPHY	MORPHOLOGY	ETIOLOGY
1 Brain	Seizures	Domoic acid
2 Uterus	~~[illegible]~~ Rupture	pregnancy/seizures
3		
4		
5		

Cause of death (preliminary diagnosis): Euthanasia - Toxicosis due to domoic acid. Uterine rupture

The Marine Mammal Center
Marin Headlands, GGNRA
Sausalito, CA 94965

'ROSS NECROPSY REPORT

Acc#	CSL 3747 F
Name	N/A - Fetus
Tag#	
Species	

Sex	male	SL 74 cm	BD 10 mm
Age	fetus	AG 43 cm	UG 45 cm
Weight	kg. (estimate/actual)		
SON	emaciated 1 2 3 4 5 6 7 obese		

Form completed by			
Strand location			
Strand county		Euthanasia ☐ Yes ☐ No	
Strand date			
Admit date			
Death date		Time	
Post mortem date	6-2-98	Time	

Carcass classification:
2 - fresh
3 - fair, decomposed, organs intact
4 - poor, advanced decomposition
5 - mummified

Clinical signs/diagnosis	
Antibiotics given	
Pertinent lab results	

Photos ☐

Radiographs ☐

HISTOLOGY SAMPLES

lung	gonad
trachea	prostate
heart	uterus
aorta	penis
pulmonary artery	eye (L / R)
thymus	brain
salivary gland	spinal cord
thyroid	bone marrow
tonsil	muscle
tongue	skin
oesophagus	blubber
stomach	
duodenum	Lymph nodes:
jejunum	submandibular
ileum	cranial cervical
colon	prescapular
pancreas	axillary
spleen	tracheobronchial
liver	hilar
gall bladder	gastric
adrenal	hepatic
kidney	mesenteric
ureter	colonic
urinary bladder	sublumbar
urethra	inguinal
OTHER:	

MICROBIOLOGY

☐ Lung

☐ Liver

☐ Brain

☐ Lymph node

☐

Gross necropsy abnormalities:

. Death approximately 4-5 days prior

TOPOGRAPHY	MORPHOLOGY	ETIOLOGY
1		
2		
3		
4		
5		

Cause of death (preliminary diagnosis):

The Marine Mammal Center
Marin Headlands, GGNRA
Sausalito, CA 94965

GROSS NECROPSY REPORT

Acc#	CSL 3748
Name	SIXTEEN
Tag#	—
Species	Zalop. Californias

Sex	F	SL 160 cm	BD 35 mm
Age	Adult	AG 114 cm	UG 81 cm
Weight	98 kg. (estimate/actual)		
SON	emaciated 1 2 3 4 (5) 6 7 obese		

Form completed by	J Gulland		
Strand location	Oceano Dunes		
Strand county	SLO	Euthanasia ☐ Yes ☒ No	
Strand date	5/22/98		
Admit date	5/22/98		
Death date	5/23/98	Time overnight	
Post mortem date	5/24/98	Time 17-00	

Carcass classification: (2) - fresh
3 - fair, decomposed, organs intact
4 - poor, advanced decomposition
5 - mummified

Clinical signs/diagnosis	Repeated seizures
Antibiotics given	-
Pertinent lab results	-

Photos ☐

Radiographs ☐

MICROBIOLOGY

☐ Lung

☐ Liver

☐ Brain

☐ Lymph node

☐

HISTOLOGY SAMPLES

(lung)	gonad
(trachea)	prostate
(heart)	(uterus)
aorta	penis
pulmonary artery	~~eye~~ (L / R)
thymus	(brain)
(salivary gland)	spinal cord
(thyroid)	bone marrow
(tonsil)	muscle
(tongue)	skin
(oesophagus)	blubber
(stomach)	
(duodenum)	Lymph nodes:
jejunum	(submandibular)
ileum	cranial cervical
colon	(prescapular)
pancreas	axillary
(spleen)	tracheobronchial
(liver)	(hilar)
gall bladder	(gastric)
(adrenal)	hepatic
(kidney)	(mesenteric)
ureter	colonic
(urinary bladder)	sublumbar
urethra	inguinal
OTHER:	

Gross necropsy abnormalities:

- NEMATODES in stomach ~~to~~ ≈10 parasitic ulcers ≈1cm in diameter
- pale pericardium with tags of fibrin on the left ventricle
- pale HEART, myocardium appears "cooked" almost friable
- swollen, mottled cranial Mediastinal Lymph node, hilar LN
- Oral ulcers, pinpoint (≈10 of them) on the palate
- yellow/bile in esophagus
- Enlarged Tonsils
- Lungs are wet, reddish + heavy, with froth in the trachea down to small bronchi
- Gastric LN large + Dark red
- ≈30 mm of reddish stomach contents

TOPOGRAPHY	MORPHOLOGY	ETIOLOGY
1 Brain	Seizures	Domoic acid
2 Heart muscle - general	pallor	unknown
3 Lung	congestion	unknown
4		
5		

Cause of death (preliminary diagnosis): Toxicosis due to domoic acid

The Marine Mammal Center
Marin Headlands, GGNRA (Note has fetus 3749F)
Sausalito, CA 94965

GROSS NECROPSY REPORT

Acc#	3749
Name	Shamus
Tag#	—
Species	Zalophus californianus

Sex	F	SL 156 cm	BD 36 mm
Age	A	AG 105 cm	UG 87 cm
Weight	107.0 kg. (estimate/actual)		
SON	emaciated 1 2 3 4 5 (6) 7 obese		

Form completed by	~~[illegible]~~ / Collins / DeGuise	
Strand location	Oceano Dunes	
Strand county	SLO	Euthanasia ☐ Yes ☒ No
Strand date	5/22/98	
Admit date	5/22/98	
Death date	5/24/98	Time In transit
Post mortem date	5/24/98	Time 16:00

Carcass classification: (2) fresh; 3 - fair, decomposed, organs intact; 4 - poor, advanced decomposition; 5 - mummified

Clinical signs/diagnosis	Seizures lasting 9-10 minutes. In between, weaving head
Antibiotics given	—
Pertinent lab results	—

Photos ☒ Gastric LN, Stomach

Radiographs ☐

HISTOLOGY SAMPLES

(lung)	gonad
trachea	prostate
(heart)	(uterus)
aorta	penis
pulmonary artery	eye (L/R)
thymus	(brain)
(salivary gland)	spinal cord
(thyroid)	bone marrow
(tonsil)	muscle
tongue	skin
(oesophagus)	blubber
(stomach)	
(duodenum)	Lymph nodes:
jejunum	(submandibular)
ileum	cranial cervical
colon	prescapular
(pancreas)	axillary
(spleen)	tracheobronchial
(liver)	hilar
gall bladder?	(gastric)
(adrenal)	hepatic
(kidney)	(mesenteric)
ureter	colonic
(urinary bladder)	sublumbar
urethra	inguinal

OTHER: (Histo → Davis 5/24)

MICROBIOLOGY

☐ Lung

☐ Liver

☐ Brain

☐ Lymph node

☐

Gross necropsy abnormalities: ADULT

Mouth: Tonsils are large, several pinpoint ulcers in the oral mucosa of the palate.
Resp. System: NSL
Oesophagus: NSL
Stomach: ≈ 300ml whitish frothy fluid in the stomach. Hyperemia gastric mucosa w/ superficial areas w/ a brownish discoloration → photos. Fine parasitic crateriform gastric ulcers, 1-3 cm in length, usually linear in shape.
Gastric LN is large, oedematous on section w/ several areas of necrosis up to 9x3 mm (photos).
Mesenteric LN are oedematous on cut section.
Intestine (duodenum) has several sub-serosal linear hemorrhages. No contents - small intestine →

TOPOGRAPHY	MORPHOLOGY	ETIOLOGY
1 Brain	Seizures	Unknown
2		
3		
4		
5		

Cause of death (preliminary diagnosis): ? Toxicosis ?

The Marine Mammal Center
Marin Headlands, GGNRA
Sausalito, CA 94965

GROSS NECROPSY REPORT

Acc#	CSL 3749 F
Name	Shamus
Tag#	—
Species	CSL - Zalophus californianus

Sex	M	SL 75 cm	BD 3 mm
Age	Fetus	AG [redacted] cm	UG [redacted] cm
Weight	7.0 kg. (estimate/actual)		
SON	emaciated 1 2 (3) 4 5 6 7 obese		

Form completed by	Collins	
Strand location	~~[illegible]~~ see 3749F	
Strand county	"	Euthanasia ☐ Yes ☒ No
Strand date	"	
Admit date	"	
Death date	"	Time
Post mortem date	5/24/98	Time

Carcass classification: (2) - fresh
3 - fair, decomposed, organs intact
4 - poor, advanced decomposition
5 - mummified

Clinical signs/diagnosis	
Antibiotics given	
Pertinent lab results	

Photos ☐

Radiographs ☐

HISTOLOGY SAMPLES

(lung)	gonad
trachea	prostate
(heart)	uterus
aorta	penis
pulmonary artery	eye (L / R)
(thymus)	brain
salivary gland	spinal cord
thyroid	bone marrow
tonsil	muscle
tongue	skin
oesophagus	blubber
stomach	
duodenum	Lymph nodes:
jejunum	submandibular
ileum	cranial cervical
colon	prescapular
pancreas	axillary
spleen	tracheobronchial
(liver)	hilar
gall bladder	gastric
adrenal	hepatic
(kidney)	mesenteric
ureter	colonic
urinary bladder	sublumbar
urethra	inguinal
OTHER:	

MICROBIOLOGY

☐ Lung

☐ Liver

☐ Brain

☐ Lymph node

☐

Gross necropsy abnormalities: FETUS

Mildly to moderately decomposed fetus.
Liver, Kidney: Moderate autolysis
Thymus: Nice and big!
Heart: One section of the left ventricle is marbled, w/ pale myocardium surrounding a darker red area.
Adrenals: NSL

TOPOGRAPHY	MORPHOLOGY	ETIOLOGY
1		
2		
3		
4		
5		

Cause of death (preliminary diagnosis): ? Anoxia? Toxicosis?

The Marine Mammal Center
Marin Headlands, GGNRA
Sausalito, CA 94965

NB: Has fetus, see sheet 3757F

GROSS NECROPSY REPORT

Acc#	CSL 3757
Name	"Twenty Six"
Tag#	—
Species	Zalophus californicus

Form completed by	J Gulland		
Strand location	Oceano Dunes		
Strand county	SLO	Euthanasia	
Strand date	5/23/98	☐ Yes	☒ No
Admit date	5/23/98		
Death date	5/23/98	Time	15-00
Post mortem date	5/24/98	Time	

Sex	F	SL 153 cm	BD 95 mm
Age	Adult	AG 111 cm	UG 108 cm
Weight	90 kg. (estimate/actual)		
SON	emaciated 1 2 3 4 5 (6) 7 obese		

Carcass classification: (2) fresh
3 - fair, decomposed, organs intact
4 - poor, advanced decomposition
5 - mummified

Clinical signs/diagnosis	Repeated seizures
Antibiotics given	Penicillin
Pertinent lab results	—

Photos ☐

Radiographs ☐

MICROBIOLOGY

☐ Lung

☐ Liver

☐ Brain

☐ Lymph node

☐

HISTOLOGY SAMPLES

(lung)	(gonad)
trachea	prostate
(heart)	(uterus) placenta
(aorta)	penis
(pulmonary artery)	eye (L / R)
thymus	(brain)
(salivary gland)	(spinal cord)
(thyroid)	bone marrow
(tonsil)	muscle
tongue	skin
(oesophagus)	blubber
(stomach)	
(duodenum)	Lymph nodes:
(jejunum)	submandibular
(ileum)	cranial cervical
(colon)	prescapular
(pancreas)	axillary
(spleen)	(tracheobronchial)
(liver)	(hilar)
(gall bladder)	(gastric)
(adrenal)	hepatic
(kidney)	(mesenteric)
ureter	colonic
(urinary bladder)	sublumbar
urethra	inguinal
OTHER:	cranial mediastinal

Gross necropsy abnormalities:

- Petechial hemorrhages on placenta + fetal membranes
- Large purple tonsil
- Mild interstitial edema of lungs
- Crusted mucus around lips, congested mucosa in oral pharynx
- Sub Q bruising over (L) axillary area
- Stomach - swollen rugae, - Areas of frank blood in lumen
- Enlarged Mesenteric LN, VERY ENLARGED HILAR LN edematous, enlarged!
- Reticular pattern of Liver
- Hemorrhagic gastric LN - enlarged, edematous.
- Adrenals - cortical hyperplasia
- Congested Spleen, gall bladder empty
- Pale Myocardium

TOPOGRAPHY	MORPHOLOGY	ETIOLOGY
1 Brain	Seizures	unknown
2 Lung	Edema	unknown
3 Heart muscle - general	Pale	unknown
4 Lymphnodes	Inflammation	unknown
5		

Cause of death (preliminary diagnosis): ? Toxicosis ?

The Marine Mammal Center
Marin Headlands, GGNRA
Sausalito, CA 94965

GROSS NECROPSY REPORT

Acc#	CSL 3767 F
Name	Twenty six Fetus
Tag#	
Species	Zalop. Californias

Form completed by	J.N. Collins		
Strand location	Ocean Dunes		
Strand county	SLO	Euthanasia	☐ Yes ☒ No
Strand date	5/23/98		
Admit date	5/23/98		
Death date	5/23/98	Time	1500
Post mortem date	5/24/98	Time	1800

Carcass classification: (2) - fresh
3 - fair, decomposed, organs intact
4 - poor, advanced decomposition
5 - mummified

Sex	F	SL 73 cm	BD 4 mm
Age	Fetus	AG 39 cm	UG 38 cm
Weight	7.0 kg. (estimate/actual)		
SON	emaciated 1 2 3 4 5 6 7 obese		

Clinical signs/diagnosis	
Antibiotics given	
Pertinent lab results	

Photos ☐

Radiographs ☐

MICROBIOLOGY

☐ Lung

☐ Liver

☐ Brain

☐ Lymph node

☐

HISTOLOGY SAMPLES

(lung)	gonad
trachea	prostate
(heart)	uterus
aorta	penis
pulmonary artery	eye (L / R)
thymus	brain
salivary gland	spinal cord
thyroid	bone marrow
tonsil	muscle
tongue	skin
oesophagus	blubber
stomach	
duodenum	Lymph nodes:
jejunum	submandibular
ileum	cranial cervical
colon	prescapular
pancreas	axillary
(spleen)	tracheobronchial
(liver)	hilar
gall bladder	gastric
adrenal	hepatic
(kidney)	(mesenteric)
ureter	colonic
urinary bladder	sublumbar
urethra	inguinal
OTHER:	

Gross necropsy abnormalities:

Patchy pale areas on myocardium
Lungs - patchy areas of hemorrhage on all lobes
Enlarged Mesenteric Lymph Nodes

TOPOGRAPHY	MORPHOLOGY	ETIOLOGY
1 Heart muscle general	Patchy pattern	Unknown
2		
3		
4		
5		

Cause of death (preliminary diagnosis): Anoxia. Maternal death

The Marine Mammal Center
Marin Headlands, GGNRA
Sausalito, CA 94965

GROSS NECROPSY REPORT

Acc#	3758 (DOA) CSW
Name	Twenty three 23
Tag#	—
Species	Zalophus californianus

Sex	F	SL 160 cm	BD 33 mm
Age	Adult	AG 104 cm	UG 88 cm
Weight	84 kg. (estimate/actual)		
SON	emaciated 1 2 3 4 (5) 6 7 obese		

Form completed by	gulland / DeGuise		
Strand location	SLO - Shell beach		
Strand county	SLO	Euthanasia ☐ Yes ☒ No	
Strand date	5/23/98		
Admit date	5/23/98		
Death date	5/23/98	Time	16.00
Post mortem date	5/24/98	Time	19.15

Carcass classification: (2 - fresh) 3 - fair, decomposed, organs intact 4 - poor, advanced decomposition 5 - mummified

Clinical signs/diagnosis	Obtunded. gurgling on inspiration
Antibiotics given	—
Pertinent lab results	—

Photos ☐

Radiographs ☐

HISTOLOGY SAMPLES

(lung) (trachea) (heart) aorta pulmonary artery thymus (salivary gland) (thyroid) (tonsil) (tongue) (oesophagus) (stomach) (duodenum) jejunum (ileum) (colon) (pancreas) (spleen) (liver) (gall bladder) (adrenal) (kidney) ureter (urinary bladder) urethra

(gonad) prostate (uterus) penis eye (L / R) (brain) spinal cord bone marrow muscle skin blubber

Lymph nodes: (submandibular) cranial cervical prescapular axillary tracheobronchial hilar (gastric) (hepatic) (mesenteric) colonic (sublumbar) inguinal

OTHER: [sent to Davis 5/25]

MICROBIOLOGY

☐ Lung

☐ Liver

☐ Brain

☒ Lymph node (Inguinal) - No growth on plate, Thio = Ecoli, non enteric gram-rod, Enterococcus

☒ large gram + maybe clostridium sp.

Gross necropsy abnormalities:

Stomach contained bloodtinged mucus. Rugae swollen, mucosa ulcerated + multiple erosions 1-3 mm dia. Intestines empty, petecchial hemorrhages on mucosa. Colon + rectum contained dry hard feces. ~10 Anisakids in stomach

gall bladder empty. spleen constricted

- Bile canaliculi in liver contained multiple Zalophatrema.
- uterus small, ovaries smooth. mammary glands not developed
- Inguinal (LN) enlarged, abscessed. Mesenteric, gastric + hepatic lymph nodes enlarged, hemorrhagic, edematous with foci of necrosis
- Few (10-15) pin point erosions/ulcers in the oral mucosa of the palate
- Lungs are reddish + wet. Serous fluid oozes on cut section
- Heart pale on surface + cut surface of left ventricle myocardium

TOPOGRAPHY	MORPHOLOGY	ETIOLOGY
1 Brain	seizures	unknown
2 palate	ulceration + erosion	unknown
3 Ventricles	patchy pattern	unknown.
4 pericardium	inflammation	unknown.
5		

Cause of death (preliminary diagnosis): ? Toxicosis

The Marine Mammal Center
Marin Headlands, GGNRA
Sausalito, CA 94965

GROSS NECROPSY REPORT

Acc#	#3760
Name	Oatmeal
Tag#	#13125
Species	CSL

Sex	F	SL 178 cm	BD 20 mm
Age	adult	AG 100 cm	UG 99 cm
Weight	97 kg. (estimate/actual)		
SON	emaciated 1 2 3 (4) 5 6 7 obese		

Form completed by	Dawn Zeilinger	
Strand location	Ocano	
Strand county	SLO	Euthanasia ☒ Yes ☐ No
Strand date	5/24	
Admit date	5/24/98	
Death date	6/2/98	Time 12:00 pm
Post mortem date	6/2/98	Time 12:00 pm

Carcass classification: (2) fresh
3 - fair, decomposed, organs intact
4 - poor, advanced decomposition
5 - mummified

Clinical signs/diagnosis	seizuring
Antibiotics given	
Pertinent lab results	

Photos ☐

Radiographs ☐

HISTOLOGY SAMPLES

lung, trachea, heart, aorta, pulmonary artery, thymus, salivary gland, thyroid, tonsil, tongue, oesophagus, stomach, duodenum, jejunum, ileum, colon, pancreas, spleen, liver, gall bladder, adrenal, kidney, ureter, urinary bladder, urethra, OTHER:

to Sprake

gonad, prostate, uterus, penis, eye (L / R), brain, spinal cord, bone marrow, muscle, skin, blubber

Lymph nodes: submandibular, cranial cervical, prescapular, axillary, tracheobronchial, hilar, gastric, hepatic, mesenteric, colonic, sublumbar, inguinal

MICROBIOLOGY

☐ Lung

☐ Liver

☐ Brain

☐ Lymph node

☒ mass - no fungus isolated @ 21 days, from thio - clostridium perfringens

Gross necropsy abnormalities:

- integ - 5x3 cm ~~[illegible]~~ area of alopecia - black pigment - dorsal surface mid-body
3x1 cm alopecic area ventral sternum
fetus - SL-72 cm, AG-40 UG-39, fem. BD-6 mm
- uterus - fetus L horn - full-term
CL on left ovary. large (2 cm diameter) fluid-filled cyst R ovary
3-4 cm white plaque on chorion surface
- spleen - 2x2 cm area white gran. tissue - old fracture ~~w/ [illegible]~~
- gallbladder - biliary hyperplasia w/ flukes (many)
- stomach - 4 2x2 cm ulcers w/ many ass. small nematodes, also large nematodes present (Goe)

TOPOGRAPHY	MORPHOLOGY	ETIOLOGY
1 Brain	Seizures	unknown
2 Uterus	enlargement	pregnancy
3 gallbladder	Hyperplasia	trematodes
4		
5		

Cause of death (preliminary diagnosis): Toxicosis

~~The~~ Marine Mammal Center
Marin Headlands, GGNRA
Sausalito, CA 94965 inam

GROSS NECROPSY REPORT

Acc#	3765
Name	DOA
Tag#	—
Species	Z. c.

Form completed by	W.A. McCulloch		
Strand location	Fisherman's Wharf		
Strand county	Monterey	Euthanasia	
Strand date	5-24-98	☐ Yes	☒ No
Admit date	5-24-98		
Death date	5-24-98	Time	
Post mortem date	25 MAY 98	Time	17:20

Carcass classification: (2 - fresh) 3 - fair, decomposed, organs intact; 4 - poor, advanced decomposition; 5 - mummified

Sex	F	SL 154 cm	BD 13 mm
Age	Adult	AG 95 cm	UG 98 cm
Weight	90 kg. (estimate/actual)		
SON	emaciated 1 2 3 4 5 6 7 obese		

Clinical signs/diagnosis	
Antibiotics given	
Pertinent lab results	

ARCHIVES	
Bullets	#
Pellets	#
Gillnet/Line/Hooks/Rocks	

lung, kidney, placenta → STORED SAMPLES virology → TMMC

Tissue blub, liv, ki, brn, tx/c	Test	tox	Sent to ECO
Tissue Stomach, feces	Test	biotoxin	Sent to TMMC
Tissue blub, mus, liv, kid	Test	tox	Sent to TMMC

HISTOLOGY SAMPLES

lung ✓	gonad ✓
trachea	prostate
heart ✓	uterus ✓
aorta ✓	penis
pulmonary artery	eye (L/R)
thymus	brain ✓
salivary gland ✓	spinal cord ✓
thyroid	bone marrow
tonsil ✓	muscle ✓
tongue	skin
oesophagus ✓	blubber ✓
stomach ✓	
duodenum	Lymph nodes:
jejunum	submandibular
ileum ✓	cranial cervical
colon ✓	prescapular
pancreas ✓	axillary
spleen ✓	tracheobronchial ✓
liver ✓	hilar ✓
gall bladder	gastric ✓
adrenal ✓	hepatic ✓
kidney ✓	mesenteric ✓
ureter	colonic ✓
urinary bladder ✓	sublumbar
urethra	inguinal
OTHER:	

ANCILLARY DIAG

- ☐ Photos
- ☐ Kidney smear
- ☒ Tooth for aging
- ☐ Radiographs
- ☐ Parasites

MICROBIOLOGY

- ☐ Lung
- ☐ Liver few mesenteric gram-rod
- ☐ Intestine
- ☐ Lymph node NOT COLLECTED
- ☐ Brain
- ☐ Spleen – Δ+ edwardsiella, RARE mesenteric gram⊖ rod

Gross necropsy abnormalities:

- gastric & mesenteric lymphadenopathy w/ mottled coloration in X sections
- uterine circulation enlarged
- petechiae in uterus at cervix

TOPOGRAPHY	MORPHOLOGY	ETIOLOGY
1 Brain	seizures	unknown
2		
3		
4		
5		

Cause of death (preliminary diagnosis): Toxicosis. Seizures

The Marine Mammal Center
Marin Headlands, GGNRA
Sausalito, CA 94965

ROSS NECROPSY REPORT

Acc#	CSL 3769 Fetus
Name	(Pascalis fetus)
Tag#	none
Species	Zcl.

Sex	Male	SL 77 cm	BD 4 mm
Age	Fetus	AG 31 cm	UG 41 cm
Weight	6.8 kg. (estimate/actual)		
SON	emaciated 1 2 3 (4) 5 6 7 obese		

Form completed by	T. Sparker	
Strand location	mann - stillborn onsite	
Strand county	mann	Euthanasia ☐ Yes ☒ No
Strand date		
Admit date	6	
Death date	3 June 98	Time
Post mortem date	3 June 98	Time

Carcass classification:
2 - fresh
3 - fair, decomposed, organs intact
4 - poor, advanced decomposition
5 - mummified

Clinical signs/diagnosis	
Antibiotics given	
Pertinent lab results	

Photos ☐

Radiographs ☐

HISTOLOGY SAMPLES

lung	gonad
trachea	prostate
heart	uterus
aorta	penis
pulmonary artery	eye (L / R)
thymus	brain
salivary gland	spinal cord
thyroid	bone marrow
tonsil	muscle
tongue	skin
oesophagus	blubber
stomach	
duodenum	Lymph nodes:
jejunum	submandibular
ileum	cranial cervical
colon	prescapular
pancreas	axillary
spleen	tracheobronchial
liver	hilar
gall bladder	gastric
adrenal	hepatic
kidney	mesenteric
ureter	colonic
urinary bladder	sublumbar
urethra	inguinal
OTHER:	

MICROBIOLOGY

☐ Lung

☐ Liver

☐ Brain

☐ Lymph node

☐

Gross necropsy abnormalities:

+ hair slipping est PMI - 3-4 days

TOPOGRAPHY	MORPHOLOGY	ETIOLOGY
1		
2		
3		
4		
5		

Cause of death (preliminary diagnosis): Anoxia in utero

The Marine Mammal Center
Marin Headlands, GGNRA
Sausalito, CA 94965

.OSS NECROPSY REPORT

Acc#	CSL 3770
Name	Joule
Tag#	13198
Species	Zalophus californianus

Sex	F	SL 187 cm	BD 22 mm
Age	Adult	AG 108 cm	UG 116 cm
Weight	118 kg. (estimate/actual)		
SON	emaciated 1 2 3 4 (5) 6 7 obese		

Form completed by	[illegible] / Lowenstine	
Strand location	Del Monte Beach	
Strand county	Monterey	Euthanasia
Strand date	5-24-98	☒ Yes ☐ No
Admit date	5-24-98	
Death date	6-4-98	Time 1000
Post mortem date	6-4-98	Time 1015

Carcass classification: (2) - fresh
3 - fair, decomposed, organs intact
4 - poor, advanced decomposition
5 - mummified

Clinical signs/diagnosis	Repeated seizures
Antibiotics given	None
Pertinent lab results	

Photos ☐

Radiographs ☐

MICROBIOLOGY

☐ Lung

☐ Liver

☐ Brain

☐ Lymph node

☐

HISTOLOGY SAMPLES

lung, trachea, heart, aorta, pulmonary artery, thymus, salivary gland, thyroid, tonsil, tongue, oesophagus, stomach, duodenum, jejunum, ileum, colon, pancreas, spleen, liver, gall bladder, adrenal, kidney, ureter, urinary bladder, urethra, OTHER:

to Sprake

gonad, prostate, uterus, penis, eye (L / R), brain, spinal cord, bone marrow, muscle, skin, blubber

Lymph nodes: submandibular, cranial cervical, prescapular, axillary, tracheobronchial, hilar, gastric, hepatic, mesenteric, colonic, sublumbar, inguinal

Gross necropsy abnormalities:. Fetus - autolyzed ~ 5 days dead
Pregnant (R) horn of uterus, 360° clockwise torsion
hemhorrage and necrosis of caudal portion Thrombosis
and large amount of edema medial and caudal to (R) of
the bifurcation of the uterus. Uterine wall was very
edematous in this area The fetus was in anterior
presentation. The uterus contained ~1 L of thick red/brown
foul smelling material. The peritoneal cavity
contained ~3-4 L of red/brown liquid that had a
foul odor. The omental sling was edematous and
dark red in color
(L) kidney larger than right, both cortexes were pale
2 cinarotic plaques 1x2cm at the caudal pole of spleen
7 volcanic ulcers in the stomach

TOPOGRAPHY	MORPHOLOGY	ETIOLOGY
1 Brain	seizures	unknown
2 uterus	torsion - volvulus	unknown
3 peritoneum	inflammation	uterine torsion
4		
5		

Cause of death (preliminary diagnosis): ? Toxicosis. Uterine torsion

The Marine Mammal Center
Marin Headlands, GGNRA
Sausalito, CA 94965

GROSS NECROPSY REPORT

Acc#	CSL 3770F
Name	FETUS (JOLLE CSL 3770)
Tag#	
Species	ZALOPHUS

Sex	F	SL 74 cm	BD 7 mm
Age	FETUS	AG 38.5 cm	UG 45 cm
Weight	7.5 kg. (estimate/actual)		
SON	emaciated 1 2 3 4 5 6 7 obese		

Form completed by			
Strand location			
Strand county		Euthanasia ☐ Yes ☑ No	
Strand date			
Admit date			
Death date		Time	
Post mortem date	6/4/98	Time	10:30

Carcass classification: (2) fresh
3 - fair, decomposed, organs intact
4 - poor, advanced decomposition
5 - mummified

Clinical signs/diagnosis	
Antibiotics given	
Pertinent lab results	

Photos ☐

Radiographs ☐

HISTOLOGY SAMPLES

lung	gonad
trachea	prostate
heart	uterus
aorta	penis
pulmonary artery	eye (L / R)
thymus	brain
salivary gland	spinal cord
thyroid	bone marrow
tonsil	muscle
tongue	skin
oesophagus	blubber
stomach	
duodenum	Lymph nodes:
jejunum	submandibular
ileum	cranial cervical
colon	prescapular
pancreas	axillary
spleen	tracheobronchial
liver	hilar
gall bladder	gastric
adrenal	hepatic
kidney	mesenteric
ureter	colonic
urinary bladder	sublumbar
urethra	inguinal
OTHER:	

MICROBIOLOGY

☐ Lung

☐ Liver

☐ Brain

☐ Lymph node

☐

Gross necropsy abnormalities: Severely autolyzed, most likely dead in utero 4-5 days.

Found in uterus (360° clockwise torsion) in anterior presentation

TOPOGRAPHY	MORPHOLOGY	ETIOLOGY
1		
2		
3		
4		
5		

Cause of death (preliminary diagnosis): Intrauterine death

The Marine Mammal Center
Marin Headlands, GGNRA
Sausalito, CA 94965

GROSS NECROPSY REPORT

Acc#	3780 CSL
Name	—
Tag#	—
Species	Zalophus californianus

Form completed by	JGullow		
Strand location	Pajaro Dunes		
Strand county	Sta Cruz	Euthanasia	
Strand date	5.23.98	☐ Yes	☒ No
Admit date	5.24.98		
Death date	5/24/98	Time	
Post mortem date	5/25/98	Time	18.00

Sex	F	SL 143 cm	BD 31 mm
Age	Adult	AG 94 cm	UG 95 cm
Weight	63 kg. (estimate/actual)		
SON	emaciated 1 2 3 4 5 (6) 7 obese		

Carcass classification: (2) fresh
3 - fair, decomposed, organs intact
4 - poor, advanced decomposition
5 - mummified

Clinical signs/diagnosis	Repeated seizures
Antibiotics given	–
Pertinent lab results	

ARCHIVES	
Bullets	#
Pellets	#
Gillnet/Line/Hooks/Rocks	

STORED SAMPLES

(1) blub, mus, liv, kid, brain	tox → TMMC	(2) liver, lung, kid → virology → TMMC	
Tissue stomach, feces	Test biotoxins	Sent to TMMC	
Tissue mammary tissue, placenta	Test virology	Sent to TMMC	
Tissue blub, liv, kid, bm, bile	Test tox	Sent to ECD	

HISTOLOGY SAMPLES

(lung)	(gonad) x2
trachea	prostate
(heart)	uterus x placenta
(aorta)	penis
pulmonary artery	eye (L / R)
thymus	(brain)
(salivary gland)	spinal cord
(thyroid)	bone marrow
(tonsil)	(muscle - diaphragm, pectoralis)
(tongue)	skin
(oesophagus)	blubber
(stomach)	cervix
(duodenum)	Lymph nodes:
jejunum	(submandibular)
(ileum)	cranial cervical
(colon)	prescapular
(pancreas)	axillary
(spleen)	(tracheobronchial)
(liver)	hilar
gall bladder	(gastric)
(adrenal)	(hepatic)
(kidney)	(mesenteric)
ureter	colonic
(urinary bladder)	sublumbar
urethra	inguinal
OTHER:	

ANCILLARY DIAG

- ☐ Photos
- ☐ Kidney smear
- ☒ Tooth for aging
- ☐ Radiographs
- ☐ Parasites

MICROBIOLOGY

- ☒ Lung few E.coli, few Listeria Nanoni, RARE mesenteric gram-
- ☒ Liver
- ☐ Intestine
- ☒ Lymph node gastric 1+ E.coli, 1+ Listeria Nanoni
- ☐ Brain few mesenteric gram-Rod.
- ☒ Spleen - RARE mesenteric gram-rod

Gross necropsy abnormalities: Late term gestation fetus ♀ 6.0 7 lbs 3 oz birth
- petecchial hemorrhages on fetal membranes. fetus
- urinary bladder empty.
- Stomach & intestine empty other than blood tinged mucus. Bile staining in esophagus. Rectum contains black tarry liquid feces.
- Gastric, mesenteric & hepatic LNs enlarged, edematous, hemorrhagic with necrotic foci - only 5 Anisakids in stomach
- Spleen congested. Gall bladder empty
- Lungs diffusely congested - Blood-tinged froth in trachea, bronchi, & bronchioles. Frank blood in bronchi
- Tonsils enlarged, deep purple,
- Myocardium pale. Right atrium & posterior vena cava engorged = blood

TOPOGRAPHY	MORPHOLOGY	ETIOLOGY
1 Brain	Seizures	unknown
2 Heart muscle - general	pallor	"
3		
4		
5		

Cause of death (preliminary diagnosis): Toxicosis.

The Marine Mammal Center
Marin Headlands, GGNRA
Sausalito, CA 94965

ROSS NECROPSY REPORT

Acc#	3783
Name	Thirty two
Tag#	—
Species	2. californianus

Sex	F	SL 151 cm	BD 22 mm
Age	Adult	AG 104 cm	UG 92 cm
Weight	80 kg. (estimate/actual)		
SON	emaciated 1 2 (3) 4 (5) 6 7 obese		

Form completed by	J Gulland	
Strand location	Oceano Dunes	
Strand county	SLO	Euthanasia ☐ Yes ☒ No
Strand date	5/23/98	
Admit date	5/23/98	
Death date	5/24/98	Time ~6am
Post mortem date	5/24/98	Time 19:00

Carcass classification: (2) - fresh
3 - fair, decomposed, organs intact
4 - poor, advanced decomposition
5 - mummified

Clinical signs/diagnosis	Repeated seizures
Antibiotics given	—
Pertinent lab results	—

ARCHIVES	
Bullets	#
Pellets	#
Gillnet/Line/Hooks/Rocks	

STORED SAMPLES		
Tissue Stomach (feces) + contents	Test Toxicology	Sent to TMMC
Tissue brain	Test virology	Sent to TMMC
Tissue mammary tissue	Test parasitology	Sent to TMMC - E. Lyon

HISTOLOGY SAMPLES

(lung)	(gonad)
trachea	prostate
(heart)	(uterus)
(aorta)	penis
pulmonary artery	eye (L / R)
thymus	(brain)
(salivary gland)	spinal cord
(thyroid)	bone marrow
(tonsil)	(muscle)
tongue	skin
(oesophagus)	blubber
(stomach)	
(duodenum)	Lymph nodes:
jejunum	submandibular
(ileum)	cranial cervical
(colon)	prescapular
(pancreas)	axillary
(spleen)	(tracheobronchial)
(liver)	(hilar)
gall bladder	(gastric)
(adrenal)	(hepatic)
(kidney)	(mesenteric)
ureter	colonic
(urinary bladder)	sublumbar
urethra	inguinal
OTHER:	

ANCILLARY DIAG	MICROBIOLOGY
☐ Photos	☐ Lung
☐ Kidney smear	☐ Liver
☒ Tooth for aging	☐ Intestine
☐ Radiographs	☐ Lymph node
☐ Parasites	☐ Brain
	☐

Gross necropsy abnormalities: Lactating. strong smell of ammonia
- Subcutaneous hemorrhage over sternum, ventral abdomen. multiple hemorrhages 5-10 cm diameter along (R) flank
- 1mm dia ulcers over hard palate
- Enlarged deep purple tonsils
- Blood tinged mucus in esophagus. Bile stained mucus distal esophagus
- Stomach + intestines empty, gastric mucosa ulcerated with ~3 volcanic ulcers containing nematodes
- gastric, mesenteric + hepatic (LN)s enlarged, purple with foci of necrosis
- uterine horns not enlarged, involuted, ovaries smooth

TOPOGRAPHY	MORPHOLOGY	ETIOLOGY
1 Brain	Seizures	Demoic acid
2 Blubber	Hemorrhages	Trauma
3		
4		
5		

Cause of death (preliminary diagnosis): ? Toxicosis - demoic acid -

The Marine Mammal Center
Marin Headlands, GGNRA
Sausalito, CA 94965

GROSS NECROPSY REPORT

Acc#	CSL # 3791
Name	Neville
Tag#	13102
Species	Zalophus californian

Sex	F	SL 172 cm	BD 24 mm
Age	Adult	AG 101 cm	UG 78 cm
Weight	88 kg. (estimate/actual)		
SON	emaciated 1 2 3 (4) 5 6 7 obese		

Form completed by	Spraker / Gulland	
Strand location	Avila Beach / Hartford Pier	
Strand county	SLO	Euthanasia
Strand date	5/24/98	☒ Yes ☐ No
Admit date	5/24/98	
Death date	6/2/98	Time
Post mortem date	6/2/98	Time

Carcass classification: (2) - fresh
3 - fair, decomposed, organs intact
4 - poor, advanced decomposition
5 - mummified

Clinical signs/diagnosis	seizures
Antibiotics given	penicillin
Pertinent lab results	–

Photos ☐

Radiographs ☐

MICROBIOLOGY

☐ Lung

☐ Liver

☐ Brain

☐ Lymph node

☒ pharyngeal pouch E. coli, Klebsiella pneumoniae

HISTOLOGY SAMPLES

lung	gonad
trachea	prostate
heart	uterus
aorta	penis
pulmonary artery	eye (L / R)
thymus	brain
salivary gland	spinal cord
thyroid	bone marrow
tonsil	muscle
tongue	skin
oesophagus	blubber
stomach	
duodenum	Lymph nodes:
jejunum	submandibular
ileum	cranial cervical
colon	prescapular
pancreas	axillary
spleen ↗ Spraker	tracheobronchial
liver	hilar
gall bladder	gastric
adrenal	hepatic
kidney	mesenteric
ureter	colonic
urinary bladder	sublumbar
urethra	inguinal
OTHER:	

Gross necropsy abnormalities:

~~white lobulated mass ~ 4x3.5 mm with a 2mm stalk~~

- white glistening firm lobulated 4 x 3.5mm mass with a 2mm stalk on left uterine horn
- Serosal surface of stomach there are several multiple large thickened plaques
- 3 volcanic ulcers
- Moderate amount gray white exudate in laryngeal pouch
- Small ~~white~~ black focal area in retina of right eye both horns of uterus - small - dual not have a pup
- liver - Atresia of connection of common bile duct to duodenum - c̄ marked ectasia of common bile duct
- Atrophy of right lobes of liver - bile ducts of right anastomosis with pancreatic ducts.

TOPOGRAPHY	MORPHOLOGY	ETIOLOGY
1 Brain	seizures	domoic acid
2 uterus	mass	unknown
3 laryngeal ventricles	suppurative inflamation	bacteria
4		
5		

Cause of death (preliminary diagnosis): Toxicosis - domoic acid -

The Marine Mammal Center
Marin Headlands, GGNRA
Sausalito, CA 94965

ROSS NECROPSY REPORT

Acc#	CSL 3793
Name	ROLLER
Tag#	13197
Species	ZALOPHUS

Sex	♀	SL 168 cm	BD 22 mm
Age	ADULT	AG 91 cm	UG 71 cm
Weight	73.0 kg. (estimate/actual)		
SON	emaciated 1 2 3 4 5 6 7 obese		

Form completed by	J Gulland	
Strand location	PAJARO DUNES	
Strand county	SANTA CRUZ	Euthanasia
Strand date	5/25/98	☑ Yes ☐ No
Admit date	5/25/98	
Death date	6/4/95	Time
Post mortem date	6/4/95	Time 0945

Carcass classification: (2) - fresh
3 - fair, decomposed, organs intact
4 - poor, advanced decomposition
5 - mummified

Clinical signs/diagnosis	LETHARGIC; STILLBORN FETUS FOUND; DEPRESSED; HEAD TREMORS
Antibiotics given	DUAL PEN
Pertinent lab results	5 days ago

Photos ☐

Radiographs ☐

HISTOLOGY SAMPLES

lung	gonad
trachea	prostate
heart 5 prake	uterus
aorta	penis
pulmonary artery	eye (L / R)
thymus	brain
salivary gland	spinal cord
thyroid	bone marrow
tonsil	muscle
tongue	skin
oesophagus	blubber
stomach	
duodenum	Lymph nodes:
jejunum	submandibular
ileum	cranial cervical
colon	prescapular
pancreas	axillary
spleen	tracheobronchial
liver	hilar
gall bladder	gastric
adrenal	hepatic
kidney	mesenteric
ureter	colonic
urinary bladder	sublumbar
urethra	inguinal
OTHER:	

MICROBIOLOGY

☐ Lung

☐ Liver

☐ Brain

☐ Lymph node

☑ UTERINE SWAB - few Enterococcus sp. few E. coli

Gross necropsy abnormalities:

- (R) uterine horn distended ~10 cm diameter, contained brown mucoid material. Site of placental attachment deep purple
- 2 volcanic ulcers in stomach

TOPOGRAPHY	MORPHOLOGY	ETIOLOGY
1 Brain	Seizures	Unknown
2		
3		
4		
5		

Cause of death (preliminary diagnosis): toxicosis - seizures

The Marine Mammal Center
Marin Headlands, GGNRA
Sausalito, CA 94965

Path. sheet attached

GROSS NECROPSY REPORT

Acc#	CSL 3794
Name	muddy
Tag#	13111
Species	Zalophus californianus

Sex	F	SL 165 cm	BD 15 mm
Age	Adult	AG 98 cm	UG 105 cm
Weight	100 kg. (estimate/actual)		
SON	emaciated 1 2 3 (4) 5 6 7 obese		

Form completed by	T. Spraker.	
Strand location	Moss Landing	
Strand county	Monterey	Euthanasia ☐ Yes ☒ No
Strand date	5/25/98	
Admit date	5/25/98	
Death date	5/31/98	Time overnight
Post mortem date	5/31/98	Time 16.00

Carcass classification: (2) fresh
3 - fair, decomposed, organs intact
4 - poor, advanced decomposition
5 - mummified

Clinical signs/diagnosis	Repeated
Antibiotics given	
Pertinent lab results	

Photos ☐

Radiographs ☐

HISTOLOGY SAMPLES

lung	gonad
trachea	prostate
heart	uterus
aorta	penis
pulmonary artery	eye (L/R)
thymus	brain
salivary gland	spinal cord
thyroid	bone marrow
tonsil	muscle
tongue	skin
oesophagus	blubber
stomach	
duodenum	Lymph nodes:
jejunum	submandibular
ileum	cranial cervical
colon	prescapular
pancreas	axillary
spleen	tracheobronchial
liver	hilar
gall bladder	gastric
adrenal	hepatic
kidney	mesenteric
ureter	colonic
urinary bladder	sublumbar
urethra	inguinal

OTHER:

MICROBIOLOGY

☐ Lung

☐ Liver

☐ Brain

☐ Lymph node

☐ laryngeal pouch - Strep. viridans
corynebacterium spp.

Gross necropsy abnormalities:

- Adult female - good condition
- 4 small 1 to 4 mm gray raised plaque with/under of L atrium major vessels - normal
- few ~~hydatids~~ nodules in liver & mild biliary fibrosis throughout
- tonsils slightly enlarged remainder nodes OK
- 7 to 10 small nematodes - stomach - no ulcers -
- few acanthocephalids & tapes in SI & ileum
- pregnant & large male fetus - DMF - ~ 12 hr. - NGL -
- urine - ~ 400 cc dark yellow brown ? myoglobin ?
- all other organs - NSL

TOPOGRAPHY	MORPHOLOGY	ETIOLOGY
1 Brain	Seizures	unknown
2 Heart muscle - general	pallor	"
3		
4		
5		

Cause of death (preliminary diagnosis): ? toxicosis ?

The Marine Mammal Center
Marin Headlands, GGNRA
Sausalito, CA 94965

GROSS NECROPSY REPORT

Acc#	CSL 3794 F
Name	
Tag#	
Species	Zalophus californianus

Sex	M	SL 72 cm	BD mm
Age	Fetus	AG 43 cm	UG 48 cm
Weight	65 kg. (estimate/actual)		
SON	emaciated 1 2 3 4 5 6 7 obese		

Form completed by	Tsyrsitko	
Strand location	~~[illegible]~~ Moss Landing Jetty	
Strand county	Monterey	Euthanasia
Strand date	5-25-98	☐ Yes ☐ No
Admit date		
Death date		Time
Post mortem date	31 May 98	Time 1950

Carcass classification: 2 - fresh
3 - fair, decomposed, organs intact
4 - poor, advanced decomposition
5 - mummified

Clinical signs/diagnosis	
Antibiotics given	
Pertinent lab results	

Photos ☐

Radiographs ☐

MICROBIOLOGY

☐ Lung

☐ Liver

☐ Brain

☐ Lymph node

☐

HISTOLOGY SAMPLES

lung	gonad
trachea	prostate
heart	uterus
aorta	penis
pulmonary artery	eye (L / R)
thymus	brain
salivary gland	spinal cord
thyroid	bone marrow
tonsil	muscle
tongue	skin
oesophagus	blubber
stomach	
duodenum	Lymph nodes:
jejunum	submandibular
ileum	cranial cervical
colon	prescapular
pancreas	axillary
spleen	tracheobronchial
liver	hilar
gall bladder	gastric
adrenal	hepatic
kidney	mesenteric
ureter	colonic
urinary bladder	sublumbar
urethra	inguinal
OTHER:	

Gross necropsy abnormalities:

Male term fetus - No gross lesions - Appeared to not have undergone much autolysis PMI 1 day

TOPOGRAPHY	MORPHOLOGY	ETIOLOGY
1		
2		
3		
4		
5		

Cause of death (preliminary diagnosis): Intrauterine death

The Marine Mammal Center
Marin Headlands, GGNRA
Sausalito, CA 94965

fetus on next sheet

GROSS NECROPSY REPORT

Acc#	CSL 3796
Name	KRISTIN
Tag#	13188
Species	Zalophus californianus

Sex	F	SL 176 cm	BD 21 mm
Age	Adult	AG 115 cm	UG 116 cm
Weight	105 kg. (estimate/actual)		
SON	emaciated 1 2 3 4 5 6 7 obese		

Form completed by	Spraker / Guillard	
Strand location	Pismo Pier	
Strand county	SLO	Euthanasia ☐ Yes ☑ No
Strand date	5/23/98	
Admit date	5/23/98	
Death date	6/1/98	Time 9 am
Post mortem date	1 June 98	Time 9:30

Carcass classification: 2 - fresh; 3 - fair, decomposed, organs intact; 4 - poor, advanced decomposition; 5 - mummified

Clinical signs/diagnosis	
Antibiotics given	
Pertinent lab results	

Photos ☐

Radiographs ☐

MICROBIOLOGY

☐ Lung

☐ Liver

☐ Brain

☐ Lymph node

☐

HISTOLOGY SAMPLES

lung	gonad
trachea	prostate
heart	uterus
aorta	penis
pulmonary artery	eye (L / R)
thymus	brain
salivary gland	spinal cord
thyroid	bone marrow
tonsil	muscle
tongue	skin
oesophagus	blubber
stomach	
duodenum	Lymph nodes:
jejunum	submandibular
ileum spraker.	cranial cervical
colon	prescapular
pancreas	axillary
spleen	tracheobronchial
liver	hilar
gall bladder	gastric
adrenal	hepatic
kidney	mesenteric
ureter	colonic
urinary bladder	sublumbar
urethra	inguinal
OTHER:	

Gross necropsy abnormalities:

- FIBRIN IN ANTERIOR Chamber of Right eye
- uterine torsion counterclockwise (180°) severe lens congestion of placenta
- fetus - dead 2 to 3 days -
- few nematodes in stomach / features in ileum
- nodes - NSL

TOPOGRAPHY	MORPHOLOGY	ETIOLOGY
1 Eye	inflamation	unknown
2 uterus	pregnancy	—
3		
4		
5		

Cause of death (preliminary diagnosis): Toxicosis . Domoic acid.

The Marine Mammal Center
Marin Headlands, GGNRA
Sausalito, CA 94965

GROSS NECROPSY REPORT

Acc#	CSC 3796 F
Name	
Tag#	
Species	Z californianus

Sex	M	SL 72 cm	BD 14 mm
Age	fetus	AG 42 cm	UG 41 cm
Weight	7.0 kg. (estimate/actual)		
SON	emaciated 1 2 3 4 5 6 7 obese		

Form completed by			
Strand location			
Strand county		Euthanasia ☐ Yes ☒ No	
Strand date			
Admit date			
Death date	6/1/98	Time	
Post mortem date	1 June 98	Time 10:30	

Carcass classification:
2 - fresh
3 - fair, decomposed, organs intact
4 - poor, advanced decomposition
5 - mummified

Clinical signs/diagnosis	
Antibiotics given	
Pertinent lab results	

Photos ☐

Radiographs ☐

HISTOLOGY SAMPLES

lung	gonad
trachea	prostate
heart	uterus
aorta	penis
pulmonary artery	eye (L / R)
thymus	brain
salivary gland	spinal cord
thyroid	bone marrow
tonsil	muscle
tongue	skin
oesophagus	blubber
stomach	
duodenum	Lymph nodes:
jejunum	submandibular
ileum	cranial cervical
colon	prescapular
pancreas	axillary
spleen	tracheobronchial
liver	hilar
gall bladder	gastric
adrenal	hepatic
kidney	mesenteric
ureter	colonic
urinary bladder	sublumbar
urethra	inguinal
OTHER:	

MICROBIOLOGY

☐ Lung

☐ Liver

☐ Brain

☐ Lymph node

☐

Gross necropsy abnormalities: NGL

male - fetus - posterior presentation
- congestion of head - severe
Tissues very autolytic
- no gross lesions

TOPOGRAPHY	MORPHOLOGY	ETIOLOGY
1		~~[illegible]~~
2		
3		
4		
5		

Cause of death (preliminary diagnosis): Dead in utero

The Marine Mammal Center
Marin Headlands, GGNRA
Sausalito, CA 94965

GROSS NECROPSY REPORT

Acc#	CSL 3800
Name	Lady Bug
Tag#	—
Species	Zalophus californianus

Sex	F	SL 168 cm	BD 14 mm
Age	Adult	AG 95 cm	UG N/E cm
Weight	86 kg. (estimate/actual)		
SON	emaciated 1 2 3 4 5 6 7 obese		

Form completed by	J Gulland		
Strand location	Moss Landing PG&E Plant		
Strand county	Monterey	Euthanasia	
Strand date	5-26-98	☒ Yes	☐ No
Admit date	5-26-98		
Death date	5-27-98	Time 1700	
Post mortem date	5-27-98	Time	

Carcass classification: 2 - fresh
3 - fair, decomposed, organs intact
4 - poor, advanced decomposition
5 - mummified

Clinical signs/diagnosis	Seizures, purulent discharge both eyes
Antibiotics given	None
Pertinent lab results	None

Photos ☐

Radiographs ☒

MICROBIOLOGY

☐ Lung

☐ Liver

☐ Brain

☐ Lymph node

☐

HISTOLOGY SAMPLES

lung	gonad
trachea	prostate
heart	uterus
aorta	penis
pulmonary artery	eye (L/R)
thymus	brain
salivary gland	spinal cord
thyroid	bone marrow
tonsil	muscle
tongue	skin
oesophagus	blubber
stomach	
duodenum	Lymph nodes:
jejunum	submandibular
ileum	cranial cervical
colon	prescapular
pancreas	axillary
spleen	tracheobronchial
liver	hilar
gall bladder	gastric
adrenal	hepatic
kidney	mesenteric
ureter	colonic
urinary bladder	sublumbar
urethra	inguinal

OTHER:

Gross necropsy abnormalities:

- Fetus - 67cm SL, 42cm AG, ♀. Amniotic fluid opaque, green
- Fibrin. tags on corneal surface, brain congested, very hot to touch
- purulent fluid from conjunctiva
- Zuolcanic ulcers on gastric mucosa
- GI tract empty
- colon & rectum contain dry hard feces
- Urinary bladder distended, contains ~200cc pale yellow urine. mucosa deep purple
- Blood tinged mucus in trachea & bronchi.

TOPOGRAPHY	MORPHOLOGY	ETIOLOGY
1 Brain	Seizures	unknown
2 Cornea	Fibrinous inflamation	"
3		
4		
5		

Cause of death (preliminary diagnosis): ? Toxicosis ?

The Marine Mammal Center
Marin Headlands, GGNRA
Sausalito, CA 94965

GROSS NECROPSY REPORT

Acc#	CSL 3801
Name	Whisper
Tag#	13185
Species	Z. c.

Sex	F	SL 164 cm	BD 21 mm
Age	Adult	AG 102 cm	UG 81 cm
Weight	83 kg. (estimate/actual)		
SON	emaciated 1 2 3 4 (5) 6 7 obese		

Form completed by	T Spraker	
Strand location	Oceano Dunes	
Strand county	S. L. Obispo	Euthanasia
Strand date	5/25/98	☒ Yes ☐ No
Admit date	5/25/98	
Death date	5/31/98	Time 11am
Post mortem date	5/31/98	Time 12am

Carcass classification: (2) fresh
3 - fair, decomposed, organs intact
4 - poor, advanced decomposition
5 - mummified

Clinical signs/diagnosis	Repeated seizures, Opistnotonus
Antibiotics given	—
Pertinent lab results	—

Photos ☒ epicardium
Radiographs ☐

HISTOLOGY SAMPLES

lung	gonad
trachea	prostate
heart	uterus
aorta	penis
pulmonary artery	eye (L / R)
thymus	brain
salivary gland	spinal cord
thyroid	bone marrow
tonsil	muscle
tongue	skin
oesophagus	blubber
stomach	
duodenum	Lymph nodes:
jejunum	submandibular
ileum	cranial cervical
colon	prescapular
pancreas	axillary
spleen	tracheobronchial
liver	hilar
gall bladder	gastric
adrenal	hepatic
kidney	mesenteric
ureter	colonic
urinary bladder	sublumbar
urethra	inguinal
OTHER:	

MICROBIOLOGY

☐ Lung

☐ Liver

☐ Brain

☐ Lymph node

☒ posterior laryngeal pouch 3+ E coli, 1 few Viridans strep

Gross necropsy abnormalities: - tonsil - slightly red lined
- excessive grey mucoid material in esophagus
- stom - mild to parasites - 10-11 large ulcers - 1-1½ cm long
- few Acanthocephalids & trmy in SI
- nodes - all WNL
- urinary small brown zone - left kidney - prog - gone 3 mo ago
- one 1½ cm clear ventral aspect left of form ligament
- ~~kidneys~~ & few small yellow algae - spleen
- small cavitation in dorsal pharyngeal pouch
- other organs WNL

TOPOGRAPHY	MORPHOLOGY	ETIOLOGY
1 Brain	Seizures	domoic acid
2		
3		
4		
5		

Cause of death (preliminary diagnosis): Euthanasia. Toxicosis due to domoic acid

The Marine Mammal Center
Marin Headlands, GGNRA
Sausalito, CA 94965

GROSS NECROPSY REPORT

Acc#	CSL 13802
Name	NONAME
Tag#	13169
Species	ZALOPHUS CALIFORNIANUS

Sex	F	SL 162 cm	BD 9 mm
Age	ADULT	AG 90 cm	UG 71 cm
Weight	57 kg. (estimate/actual)		
SON	emaciated 1 (2) 3 4 5 6 7 obese		

Form completed by	M. HALLEWA	
Strand location	MONTEREY DUNES	
Strand county	MONTEREY	Euthanasia ☐ Yes ☐ No
Strand date	5/26/98	
Admit date	5/26/98	
Death date	6/27/98	Time 09:30
Post mortem date	6/27/98	Time 10:00

Carcass classification: (2) fresh
3 - fair, decomposed, organs intact
4 - poor, advanced decomposition
5 - mummified

Clinical signs/diagnosis	anorexic, seizures, stillbirth
Antibiotics given	
Pertinent lab results	

Photos ☐

Radiographs ☐

HISTOLOGY SAMPLES

(lung)	(gonad)
trachea	prostate
(heart)	(uterus)
aorta	penis
(pulmonary artery)	eye (L / R)
thymus	(brain)
(salivary gland)	spinal cord
thyroid	bone marrow
(tonsil)	(muscle)
(tongue)	(skin)
oesophagus	(blubber)
(stomach)	
(duodenum)	Lymph nodes:
jejunum	submandibular
ileum	cranial cervical
(colon)	prescapular
(pancreas)	axillary
spleen	tracheobronchial
(liver)	(hilar)
gall bladder	gastric
adrenal	hepatic
(kidney)	mesenteric
(ureter)	colonic
(urinary bladder)	sublumbar
urethra	inguinal
OTHER:	(thoracic/mediastinal)

MICROBIOLOGY

☐ Lung

☐ Liver

☐ Brain

☐ Lymph node

☑ abscess 3+ group F beta strep

Gross necropsy abnormalities:

SKIN/MUSCLE - ABSCESS - 20cm long x 4cm x 10cm in (L) PECTORAL MUSCLE WITH MULTIPLE FISTULAE, AND MZ ASSOCIATED MUSCLE NECROSIS

LUNG - 2+ PARAFILARIDAE, MZ CONGESTION/CONSOLIDATION INTERMITTENT

STOMACH - MZ ULCERATION 2+ SMALL (<2cm) INTERMITTENT

LIVER - TRICHINOSIS SMALL BILIARY FORM 3+ EIMERIA IN BILE DUCTS

LYMPH NODES - (1) ABSCESSED MEDIASTINAL (4) MILLIARY MZ INVOLVED BIRD FEATHERS

TESTES - (2) HAVE DISTENDED 2 4cm DIAMETER WITH FLUID & [illegible] IN NUDA

KIDNEYS - MZ SWOLLEN, MI-2 PALE, MI LOSS OF RENAL DIFFERENTIATION

TOPOGRAPHY	MORPHOLOGY	ETIOLOGY
1 Brain	Seizures	unknown
2		
3		
4		
5		

Cause of death (preliminary diagnosis): UNKNOWN / POSSIBLE DOMOIC ACID TOXICOSIS

The Marine Mammal Center
Marin Headlands, GGNRA
Sausalito, CA 94965

GRO NECROPSY REPORT

Acc#	3802F
Name	-still born- CSL
Tag#	none
Species	Zc.

Sex	Male	SL 79.5cm	BD 5 mm
Age	Neonate	AG 42 cm	UG 44 cm
Weight	7.0 kg. (estimate/actual)		
SON	emaciated 1 2 3 4 5 6 7 obese		

Form completed by	Spraker		
Strand location	— Inutero of 3802		
Strand county	-	Euthanasia	
Strand date	-	☐ Yes	☒ No
Admit date	-		
Death date	2 est 3 days	Time	
Post mortem date	6/2/98	Time 15:30	

Carcass classification: 2 - fresh
3 - fair, decomposed, organs intact
4 - poor, advanced decomposition
5 - mummified

Clinical signs/diagnosis	
Antibiotics given	
Pertinent lab results	

Photos ☐

Radiographs ☐

HISTOLOGY SAMPLES

lung	gonad
trachea	prostate
heart	uterus
aorta	penis
pulmonary artery	eye (L / R)
thymus	brain
salivary gland	spinal cord
thyroid	bone marrow
tonsil	muscle
tongue	skin
oesophagus	blubber
stomach	
duodenum	Lymph nodes:
jejunum	submandibular
ileum	cranial cervical
colon	prescapular
pancreas	axillary
spleen	tracheobronchial
liver	hilar
gall bladder	gastric
adrenal	hepatic
kidney	mesenteric
ureter	colonic
urinary bladder	sublumbar
urethra	inguinal
OTHER:	

MICROBIOLOGY

☐ Lung

☐ Liver

☐ Brain

☐ Lymph node

☐

Gross necropsy abnormalities:

- Several days post mortem - skin loosening

NO GROSS LESIONS

TOPOGRAPHY	MORPHOLOGY	ETIOLOGY
1		
2		
3		
4		
5		

Cause of death (preliminary diagnosis): In utero death. Anoxia.

The Marine Mammal Center
Marin Headlands, GGNRA
Sausalito, CA 94965

GROSS NECROPSY REPORT

Acc#	3803 csl
Name	Ouch
Tag#	No tag
Species	CSL - Zalophus californianus

Sex	♀	SL 154 cm	BD 16 mm
Age	Adult	AG 89 cm	UG 71 cm
Weight	59 kg. (estimate/actual)		
SON	emaciated 1 2 3 (4) 5 6 7 obese		

Form completed by	Wam / Joan Herman		
Strand location	635 Oceanview		
Strand county	Monterey	Euthanasia	
Strand date	5-25-98	☑ Yes	☐ No
Admit date	5-26-98		
Death date	27 May 98	Time	11:00
Post mortem date	5-27-98	Time	

Carcass classification: (2) - fresh
3 - fair, decomposed, organs intact
4 - poor, advanced decomposition
5 - mummified

Clinical signs/diagnosis	Prolapsed uterus
Antibiotics given	None
Pertinent lab results	None

Photos ☐

Radiographs ☐

HISTOLOGY SAMPLES

(lung)	gonad
trachea	prostate
(heart)	(uterus)
aorta	penis
pulmonary artery	eye (L / R)
thymus	(brain)
salivary gland	spinal cord
(thyroid)	bone marrow
tonsil	muscle
tongue	skin
oesophagus	blubber
(stomach)	
(duodenum)	Lymph nodes:
(jejunum)	submandibular
ileum	cranial cervical
colon	prescapular
pancreas	axillary
spleen	(tracheobronchial)
liver	hilar
gall bladder	gastric
adrenal	hepatic
kidney	(mesenteric)
ureter	colonic
(urinary bladder)	sublumbar
urethra	inguinal
OTHER:	

MICROBIOLOGY

☐ Lung

☐ Liver

☐ Brain

☐ Lymph node

☒ peritoneal swab - Lt β streptococcus

Gross necropsy abnormalities:

- 3mm cyst on cranial 1/2 (R) thyroid gland
- 500ml blood tinged fluid in peritoneal cavity
- spleen constricted
- gastric mucosa thickened, red, moderate erosion of mucosa
- ~20 Anisakids in lumen
- Intestines empty
- mesenteric LN gelatinous, enlarged
- urinary bladder empty
- uterine prolapse - tissue thickened, necrotic, containing pus and necrotic mucosa

TOPOGRAPHY	MORPHOLOGY	ETIOLOGY
1 uterus	prolapse	unknown
2 thyroid	cyst	unknown
3		
4		
5		

Cause of death (preliminary diagnosis): Euthanonic, prolapse + necrosis of uterus ~~sept~~ Pomoic Acid Toxicity

The Marine Mammal Center
Marin Headlands, GGNRA
Sausalito, CA 94965

GROSS NECROPSY REPORT

Acc#	CSL #3804
Name	"Kitty"
Tag#	#13157
Species	~~ZAM~~ Zalophus californianus

Sex	F	SL 170 cm	BD 12 mm
Age	adult	AG 92 cm	UG 78 cm
Weight	62.5 kg. (estimate/actual)		
SON	emaciated 1 2 (3) 4 5 6 7 obese		

Form completed by	Dawn Zeiliger	
Strand location	PG&E, MOSS LANDING	
Strand county	MONTEREY	Euthanasia
Strand date	~~4/1/98~~ 5/26/98	☒ Yes ☐ No
Admit date	5/26/98	
Death date	6/3/98	Time 9:15
Post mortem date	6/3/98	Time 9:15

Carcass classification: (2) fresh
3 - fair, decomposed, organs intact
4 - poor, advanced decomposition
5 - mummified

Clinical signs/diagnosis	seizures, tonic/clonic, chronic
Antibiotics given	—
Pertinent lab results	HCT = 61.7 (DEHYDRATION)

Photos ☐

Radiographs ☐

HISTOLOGY SAMPLES

to Spraker

lung	gonad
trachea	prostate
heart	uterus
aorta	penis
pulmonary artery	eye (L / R)
thymus	brain
salivary gland	spinal cord
thyroid	bone marrow
tonsil	muscle
tongue	skin
oesophagus	blubber
stomach	
duodenum	Lymph nodes:
jejunum	submandibular
ileum	cranial cervical
colon	prescapular
pancreas	axillary
spleen	tracheobronchial
liver	hilar
gall bladder	gastric
adrenal	hepatic
kidney	mesenteric
ureter	colonic
urinary bladder	sublumbar
[illegible]ra	inguinal
[illegible]R:	

MICROBIOLOGY

☐ Lung

☐ Liver

☐ Brain

☐ Lymph node

☐

Gross necropsy abnormalities:

- stomach - nine healing ulcers
- spleen - 2 cirrhotic plaques
- gallbladder - flukes, fibrotic ducts, ectasia
- stomach - ~~[illegible]~~ large nematode
  two small (1cm diameter) fluid-filled cysts
- uterus - not pregnant, serosal scars +
  vascular hyperplasia indicates post pregnancy
- ileo-colic-cecal junction - few tapeworms

TOPOGRAPHY	MORPHOLOGY	ETIOLOGY
1 BRAIN	SEIZURES	UNKNOWN
2 STOMACH	ULCERATION	ANISAKIDAE
3 GALL BLADDER	FIBROSIS, ECTASIA	ZALOPHATREMA
4 UTERUS	HYPERPLASIA	POST - PARTURIENT
5		

Cause of death (preliminary diagnosis): UNKNOWN / TOXICOSIS

The Marine Mammal Center
Marin Headlands, GGNRA
Sausalito, CA 94965

GROSS NECROPSY REPORT

Acc#	CSL 3805
Name	Hunter
Tag#	—
Species	Zalophus californianus

Form completed by	Diane Paschall		
Strand location	Born at TMMC		
Strand county	"	Euthanasia	
Strand date	"	☒ Yes	☐ No
Admit date born	5-25-98		
Death date	5-28-98	Time	1847
Post mortem date	5-29-98	Time	1200

Sex	F	SL 74 cm	BD mm
Age	3 days	AG 45 cm	UG 41 cm
Weight	7.3 kg. (estimate/actual)		
SON	emaciated 1 2 3 4 5 6 7 obese		

Carcass classification:
2 - fresh
3 - fair, decomposed, organs intact
4 - poor, advanced decomposition
5 - mummified

Clinical signs/diagnosis	born from CSL 3752, still alive, would not nurse prop, aspirated formula
Antibiotics given	Baytril
Pertinent lab results	None

Photos ☐

Radiographs ☐

HISTOLOGY SAMPLES

none

lung	gonad
trachea	prostate
heart	uterus
aorta	penis
pulmonary artery	eye (L / R)
thymus	brain
salivary gland	spinal cord
thyroid	bone marrow
tonsil	muscle
tongue	skin
oesophagus	blubber
stomach	
duodenum	Lymph nodes:
jejunum	submandibular
ileum	cranial cervical
colon	prescapular
pancreas	axillary
spleen	tracheobronchial
liver	hilar
gall bladder	gastric
adrenal	hepatic
kidney	mesenteric
ureter	colonic
urinary bladder	sublumbar
urethra	inguinal
OTHER:	

MICROBIOLOGY

- ☐ Lung
- ☐ Liver
- ☐ Brain
- ☐ Lymph node
- ☐

Gross necropsy abnormalities:

blubber - yellow
lungs - dark purple
liver - pale, yellow/orange, hemorrhage on one lobe
stomach - brown fluid (formula)
intestines - empty

TOPOGRAPHY	MORPHOLOGY	ETIOLOGY
1 Blubber	jaundice	prematurity
2		
3		
4		
5		

Cause of death (preliminary diagnosis): Hypoglycemia - Hypothermia

The Marine Mammal Center
Marin Headlands, GGNRA
Sausalito, CA 94965

See attached sheet for fetus

GROSS NECROPSY REPORT

Acc#	CSL 3806
Name	Flower
Tag#	13155
Species	CSL

Sex	♀	SL 172 cm	BD mm
Age	Adult	AG 183 cm	UG 83 cm
Weight	85.0 kg. (estimate/actual)		
SON	emaciated 1 2 3 (4) 5 6 7 obese		

Form completed by	J. Herman		
Strand location	Monterey Dune		
Strand county	Monterey	Euthanasia	
Strand date	5/27/98	☒ Yes	☐ No
Admit date	5/27/98		
Death date	6/1/98	Time	14:00
Post mortem date	6/1/98	Time	14:10

Carcass classification: (2) - fresh
3 - fair, decomposed, organs intact
4 - poor, advanced decomposition
5 - mummified

Clinical signs/diagnosis	Seizures. Stillborn fetus
Antibiotics given	Penicillin
Pertinent lab results	—

Photos ☐

Radiographs ☐

HISTOLOGY SAMPLES

to Agnes

lung	gonad
trachea	prostate
heart	uterus
aorta	penis
pulmonary artery	eye (L / R)
thymus	brain
salivary gland	spinal cord
thyroid	bone marrow
tonsil	muscle
tongue	skin
oesophagus	blubber
stomach	
duodenum	Lymph nodes:
jejunum	submandibular
ileum	cranial cervical
colon	prescapular
pancreas	axillary
spleen	tracheobronchial
liver	hilar
gall bladder	gastric
adrenal	hepatic
kidney	mesenteric
ureter	colonic
urinary bladder	sublumbar
urethra	inguinal
OTHER:	

MICROBIOLOGY

☐ Lung

☐ Liver

☐ Brain

☐ Lymph node

☒ Peritoneal fluid Enterococcus

Gross necropsy abnormalities:

(L) Heart - fibrinous pericarditis
Mesentery adhesions to the liver
Gall bladder wall thickened
Bile duct full of flukes
3cm cyst cranial pole of (R) Kidney
Stomach - heavy infestation of small nematodes with associated ulcers ranging from 0.75 - 1.5cm in diameter. Thick mucous present
large nematodes present also
Intestinal tract contains small amount of mucoid yellow material
Placental attachment present in right uterine horn
no associated odor

TOPOGRAPHY	MORPHOLOGY	ETIOLOGY
1 Brain	seizures	Domoic acid
2 pericardium	Fibrinous inflamation	unknown
3 Bile ducts	obstruction	Zalophatrema hepaticum
4 stomach	ulceration + erosion	Anisakidae
5 uterus	~~peo~~ focal pattern	pregnancy

Cause of death (preliminary diagnosis): ? Toxicosis due to domoic acid

The Marine Mammal Center
Marin Headlands, GGNRA
Sausalito, CA 94965

GROSS NECROPSY REPORT

Acc#	CSL 3806 / FETUS
Name	—
Tag#	—
Species	CSL ZALOPHUS CALIFORNIANUS

Form completed by	W.A. Mitchell		
Strand location	–		
Strand county	–	Euthanasia	
Strand date	–	☐ Yes	☑ No
Admit date	–		
Death date	5/30/98	Time ~3:15	
Post mortem date	5/30/98	Time 4:10	

Sex	M	SL 73 cm	BD 4 mm
Age	FETUS	AG 34 cm	UG 37 cm
Weight	5 kg. 12 lbs 12.03 (estimate/actual)		
SON	emaciated 1 (2) 3 4 5 6 7 obese		

Carcass classification: (2 - fresh) 3 - fair, decomposed, organs intact
4 - poor, advanced decomposition
5 - mummified

Clinical signs/diagnosis	
Antibiotics given	
Pertinent lab results	

Photos ☐

Radiographs ☐

HISTOLOGY SAMPLES

lung	gonad
trachea	prostate
heart	uterus
aorta	penis
pulmonary artery	eye (L / R)
thymus	brain
salivary gland	spinal cord
thyroid	bone marrow
tonsil	muscle
tongue	skin
oesophagus	blubber
stomach	
duodenum	Lymph nodes:
jejunum	submandibular
ileum	cranial cervical
colon	prescapular
pancreas	axillary
spleen	tracheobronchial
liver	hilar
gall bladder	gastric
adrenal	hepatic
kidney	mesenteric
ureter	colonic
urinary bladder	sublumbar
urethra	inguinal
OTHER:	

MICROBIOLOGY

☐ Lung

☐ Liver

☐ Brain

☐ Lymph node

☐

Gross necropsy abnormalities:
- fluid filled lungs
- bile colored fluid in stomach
- margins of liver rounded

TOPOGRAPHY	MORPHOLOGY	ETIOLOGY
1 Lung	Atelectasis	stillborn
2		
3		
4		
5		

Cause of death (preliminary diagnosis): perinatal mortality

The Marine Mammal Center
Marin Headlands, GGNRA
Sausalito, CA 94965

GROSS NECROPSY REPORT

Acc#	CSL 3807
Name	OPAL
Tag#	–
Species	Z. californianus

Form completed by	L. Lowenstine		
Strand location	Hidden Beach		
Strand county	S. CRUZ	Euthanasia ☐ Yes ☒ No	
Strand date	5/27/98		
Admit date	5/27/98		
Death date	5/27/98	Time 23:00	
Post mortem date	5/28/98	Time 16:00	

Carcass classification: (1) - fresh; 3 - fair, decomposed, organs intact; 4 - poor, advanced decomposition; 5 - mummified

Sex	F	SL 156 cm	BD 42 mm
Age	Adult	AG 107 cm	UG 98 cm
Weight	87 kg. (estimate/actual)		
SON	emaciated 1 2 3 4 5 (6) 7 obese		

86.5

Clinical signs/diagnosis	Seizures on beach. Died in transit.
Antibiotics given	—
Pertinent lab results	–

Photos ☑ beside skeleton, skin,
Radiographs ☐

MICROBIOLOGY None submitted

☐ Lung
☐ Liver
☐ Brain
☐ Lymph node
☐

HISTOLOGY SAMPLES

lung	gonad
trachea	~~prostate~~
heart	uterus
aorta	penis
pulmonary artery	eye (L/R)
thymus	brain
salivary gland	spinal cord C1,2
thyroid	bone marrow
tonsil	muscle
tongue	skin
oesophagus	blubber
stomach	mam. gland
duodenum	Lymph nodes:
jejunum	submandibular
ileum	cranial cervical
colon	prescapular
pancreas	axillary
spleen	tracheobronchial
liver	hilar
gall bladder	gastric
adrenal	hepatic
kidney	mesenteric
ureter	colonic
urinary bladder	sublumbar
urethra	inguinal

OTHER: placenta, fetal tissues

Gross necropsy abnormalities:
- Multifocal severe parasitic gastritis
- Severe parasitic choledochitis + cholecystitis
- Gastric + hepatic lymphadenopathy with enlarged cortical lymphoplasia and multifocal lymphadenitis
- Mild multifocal palatine ulceration (?) - per rectal red submucosal foci
- Grossly edema with multifocal perivascular necrosis + fibrin thrombi
  Fetus - 5.9 kg, 70 cm SL
  - pneumonia aspiration
  - multifocal Kulchitsky hemorrhage
- lymphocytic depletion
- no gross brain lesions

TOPOGRAPHY	MORPHOLOGY	ETIOLOGY
1 Brain	Seizures	Unknown
2		
3		
4		
5		

Cause of death (preliminary diagnosis): ? Toxicosis

The Marine Mammal Center
Marin Headlands, GGNRA
Sausalito, CA 94965

GROSS NECROPSY REPORT

Acc#	CSL 3807 F
Name	fetus
Tag#	
Species	2. californianus

Sex		SL 70 cm	BD mm
Age	fetus	AG cm	UG cm
Weight	5.9 kg. (estimate/actual)		
SON	emaciated 1 2 3 4 5 6 7 obese		

Form completed by			
Strand location			
Strand county		Euthanasia	
Strand date		❑ Yes	❑ No
Admit date			
Death date		Time	
Post mortem date	5/28/98	Time	

Carcass classification:
2 - fresh
3 - fair, decomposed, organs intact
4 - poor, advanced decomposition
5 - mummified

Clinical signs/diagnosis	
Antibiotics given	
Pertinent lab results	

Photos ❑

Radiographs ❑

HISTOLOGY SAMPLES

lung	gonad
trachea	prostate
heart	uterus
aorta	penis
pulmonary artery	eye (L / R)
thymus	brain
salivary gland	spinal cord
thyroid	bone marrow
tonsil	muscle
tongue	skin
oesophagus	blubber
stomach	
duodenum	Lymph nodes:
jejunum	submandibular
ileum	cranial cervical
colon	prescapular
pancreas	axillary
spleen	tracheobronchial
liver	hilar
gall bladder	gastric
adrenal	hepatic
kidney	mesenteric
ureter	colonic
urinary bladder	sublumbar
urethra	inguinal
OTHER:	

MICROBIOLOGY

❑ Lung

❑ Liver

❑ Brain

❑ Lymph node

❑

Gross necropsy abnormalities:

TOPOGRAPHY	MORPHOLOGY	ETIOLOGY
1		
2		
3		
4		
5		

Cause of death (preliminary diagnosis): Intrauterine death

The Marine Mammal Center
Marin Headlands, GGNRA
Sausalito, CA 94965

GROSS NECROPSY REPORT

Acc#	CSL 3824
Name	SADY
Tag#	13107
Species	ZALOPHUS CALIFORNIANUS

Sex	♀	SL 171 cm	BD 39 mm
Age	ADULT	AG 96 cm	UG 905 cm
Weight	63.5 kg. (estimate/actual)		
SON	emaciated 1 2 3 4 5 6 7 obese		

Form completed by	T. SPRAKER / M. HAULENA		
Strand location	COCHRAN LAGOON		
Strand county	SANTA CRUZ	Euthanasia	
Strand date	5/29/98	☑ Yes	☐ No
Admit date	5/29/98		
Death date	6/3/98	Time	12:15
Post mortem date	6/3/98	Time	12:30

Carcass classification: 2 - fresh; 3 - fair, decomposed, organs intact; 4 - poor, advanced decomposition; 5 - mummified

Clinical signs/diagnosis	SEIZURES; BIRTH OF STILLBORN FETUS.
Antibiotics given	
Pertinent lab results	DEHYDRATION HCT: 59.7

Photos ☐

Radiographs ☐

HISTOLOGY SAMPLES ✓

lung	gonad
trachea	prostate
heart	uterus
aorta to UCD	penis
pulmonary artery	eye (L / R)
thymus	brain
salivary gland	spinal cord
thyroid	bone marrow
tonsil	muscle
tongue	skin
oesophagus	blubber
stomach	
duodenum	Lymph nodes:
jejunum	submandibular
ileum	cranial cervical
colon	prescapular
pancreas	axillary
spleen	tracheobronchial
liver	hilar
gall bladder	gastric
adrenal	hepatic
kidney	mesenteric
ureter	colonic
urinary bladder	sublumbar
urethra	inguinal
OTHER:	

MICROBIOLOGY

☐ Lung

☐ Liver

☐ Brain

☒ Lymph node sublumbar (R) no growth

☒

Gross necropsy abnormalities:

uterus - R horn enlarged, thickened, edematous mucosa - hemorrhage in lumen of uterus + vagina
three small (3-6 mm) pale white masses ~~on endometrium~~ vaginal fornix

two firm lumpy masses - sublumbar nodes presumably
L - 6x4x3 cm - pus on cut section - white, firm
R - 4x3x3 cm - no obvious pus
four shallow healing gastric ulcers - some nematodes (small + large)
gallbladder flukes present

TOPOGRAPHY	MORPHOLOGY	ETIOLOGY
1 BRAIN	SEIZURES	UNKNOWN
2 UTERUS, MUCOSA	HYPERPLASIA	POST-PARTURIENT
3 GALL BLADDER	INFLAMMATION	ZALOPHATREMA
4		
5		

Cause of death (preliminary diagnosis): UNKNOWN / TOXICOSIS

PALM CSL 3901

The Marine Mammal Center
Marin Headlands, GGNRA
Sausalito, CA 94965

GROSS NECROPSY REPORT

Acc#	CSL 3901
Name	PALM
Tag#	13247
Species	Z. C.

Sex	F	SL 176 cm	BD 15 mm
Age	Adult	AG 95 cm	UG 81 cm
Weight	93 kg. (estimate/actual)		
SON	emaciated 1 2 3 4 5 (6) 7 obese		

Form completed by	S. Rommel	
Strand location	Pajaro Dunes	
Strand county	Santa Cruz	Euthanasia
Strand date	6-8-98	☒ Yes ☐ No
Admit date	6-8-98	
Death date	6-22-98	Time
Post mortem date	22 Jun 98	Time

Carcass classification: (2) - fresh
3 - fair, decomposed, organs intact
4 - poor, advanced decomposition
5 - mummified

Clinical signs/diagnosis	senility, anorexia
Antibiotics given	penicillin
Pertinent lab results	PO4 11.9 Ca 11.0 BUN 66 Fe 96

Photos ☐

Radiographs ☐

HISTOLOGY SAMPLES

lung, trachea, heart, aorta, pulmonary artery, thymus, salivary gland, thyroid, tonsil, tongue, oesophagus, stomach, duodenum, jejunum, ileum, colon, pancreas, spleen, liver, gall bladder, adrenal, kidney, ureter, urinary bladder, urethra, OTHER:

gonad, prostate, uterus, penis, eye (L/R), brain, spinal cord, bone marrow, muscle, skin, blubber

Lymph nodes: submandibular, cranial cervical, prescapular, axillary, tracheobronchial, hilar, gastric, hepatic, mesenteric, colonic, sublumbar, inguinal

MICROBIOLOGY

☐ Lung

☐ Liver

☐ Brain

☐ Lymph node

☐

Gross necropsy abnormalities:

- KIDNEY CAPSULES OPAQUE - LOSS OF DIFFERENTIATION
- GALL BLADDER MUCOSA W/ LESIONS
- AX. lnn REACTIVE - NOT ENLGD. NOT DARK.
- lung caseous cpt superficial to pleurop ln.
- Teeth worn to gum margin

TOPOGRAPHY	MORPHOLOGY	ETIOLOGY
1 KIDNEY	inflamation	unknown
2 Brain	seizures	unknown
3		
4		
5		

Cause of death (preliminary diagnosis): Euthanasia, senility, Renal damage

The Marine Mammal Center
Marin Headlands, GGNRA
Sausalito, CA 94965

GROSS NECROPSY REPORT

Acc#	CSL 3931
Name	WHITELIGHT
Tag#	–
Species	Zalophus californianus

Sex	M	SL 133 cm	BD 12 mm
Age	Sub adult	AG 80 cm	UG 66 cm
Weight	42.5 kg. (estimate/actual)		
SON	emaciated 1 2 3 4 (5) 6 7 obese		

Form completed by	M. HAMLEMI		
Strand location	QUINES BEACH		
Strand county	SAN MATEO	Euthanasia	
Strand date	6/14/98	☑ Yes	☐ No
Admit date	6/14/98		
Death date	6/14/98	Time	21:12
Post mortem date	6/15/98	Time	11:30

Carcass classification: (2) fresh
3 - fair, decomposed, organs intact
4 - poor, advanced decomposition
5 - mummified

Clinical signs/diagnosis	
Antibiotics given	
Pertinent lab results	

Photos ☐

Radiographs ☐

HISTOLOGY SAMPLES

lung	gonad
trachea	prostate
heart	uterus
aorta	penis
pulmonary artery	eye (L / R)
thymus	brain
salivary gland	spinal cord
thyroid	bone marrow
tonsil	muscle
tongue	skin
oesophagus	blubber
stomach	
duodenum	Lymph nodes:
jejunum	submandibular
ileum	cranial cervical
colon	prescapular
pancreas	axillary
spleen	tracheobronchial
liver	hilar
gall bladder	gastric
adrenal	hepatic
kidney	mesenteric
ureter	colonic
urinary bladder	sublumbar
urethra	inguinal
OTHER:	

MICROBIOLOGY

☐ Lung

☐ Liver

☐ Brain

☐ Lymph node

☐

Gross necropsy abnormalities:

KIDNEYS - M1-2 SWELLING, M2 PALLOR, M1-2 LOSS OF RENALE DIFFERENTIATION WITH HEMORRHAGE AT C:M JUNCTION
STOMACH: - 2° ANISAKIDS 3 VOLCANIC ULCERS UP TO 8cm DIAMETER WITH CAPUAL ANISAKIDS WITHIN
LUNGS - 1° PARAFILAROIDES, M1 CONGESTION
TRACHEA/BRONCHI - M1-2 FOAM IN 2° BRONCHI, BILATERAL

TOPOGRAPHY	MORPHOLOGY	ETIOLOGY
1 Brain	Seizures	unknown
2		
3		
4		
5		

Cause of death (preliminary diagnosis): ~~UNKNOWN~~ Toxicosis. Seizures

The Marine Mammal Center
Marin Headlands, GGNRA
Sausalito, CA 94965

GROSS NECROPSY REPORT

Acc#	CSL 3835 F
Name	punchy's fetus
Tag#	—
Species	Zalophus californian

Sex	m	SL 81 cm	BD 4 mm
Age	fetus	AG 40 cm	UG 42 cm
Weight	6 kg. (estimate/actual)		
SON	emaciated 1 2 (3) 4 5 6 7 obese		

Form completed by	J Guilland		
Strand location	80 m in Marin		
Strand county		Euthanasia ☐ Yes ☐ No	
Strand date			
Admit date			
Death date	31 May 98	Time	
Post mortem date	31 May 98	Time 12:30	

Carcass classification:
2 - fresh
3 - fair, decomposed, organs intact
4 - poor, advanced decomposition
5 - mummified

Clinical signs/diagnosis	
Antibiotics given	
Pertinent lab results	

Photos ☐

Radiographs ☐

MICROBIOLOGY

☐ Lung

☐ Liver

☐ Brain

☐ Lymph node

☐

HISTOLOGY SAMPLES

lung	gonad
trachea	prostate
heart	uterus
aorta	penis
pulmonary artery	eye (L / R)
thymus	brain
salivary gland	spinal cord
thyroid	bone marrow
tonsil	muscle
tongue	skin
oesophagus	blubber
stomach	
duodenum	Lymph nodes:
jejunum	submandibular
ileum	cranial cervical
colon	prescapular
pancreas	axillary
spleen	tracheobronchial
liver	hilar
gall bladder	gastric
adrenal	hepatic
kidney	mesenteric
ureter	colonic
urinary bladder	sublumbar
urethra	inguinal
OTHER:	

Gross necropsy abnormalities: [illegible]

- Dead in utero
- Hemorrhage over skull - frontal bones

TOPOGRAPHY	MORPHOLOGY	ETIOLOGY
1		
2		
3		
4		
5		

Cause of death (preliminary diagnosis): Intrauterine death

The Marine Mammal Center
Marin Headlands, GGNRA
Sausalito, CA 94965

GROSS NECROPSY REPORT

Acc#	CSL 3950
Name	Athena
Tag#	13 218
Species	Z. californianus

Sex	F	SL 166 cm	BD 1 mm
Age	Adult	AG 85 cm	UG 74 cm
Weight	50 kg. (estimate/actual)		
SON	emaciated 1 (2) 3 4 5 6 7 obese		

Form completed by	J Gulland		
Strand location	Asilomar Beach		
Strand county	monterey	Euthanasia	
Strand date	6/15/98	☐ Yes	☒ No
Admit date	6/15/98		
Death date	6/20/-98	Time	10-00
Post mortem date	6/20/-98	Time	15-00

Carcass classification: (2) - fresh
3 - fair, decomposed, organs intact
4 - poor, advanced decomposition
5 - mummified

Clinical signs/diagnosis	Depressed obtunded
Antibiotics given	–
Pertinent lab results	–

Photos ☐

Radiographs ☐

HISTOLOGY SAMPLES

(lung)	(gonad)
trachea	prostate
(heart)	(uterus)
aorta	penis
pulmonary artery	(eye) (L) (R)
thymus	(brain)
(salivary gland)	(spinal cord)
(thyroid)	bone marrow
tonsil	muscle
tongue	skin
oesophagus	blubber
(stomach)	
duodenum	Lymph nodes:
jejunum	submandibular
(ileum)	cranial cervical
colon	prescapular
pancreas	axillary
(spleen)	tracheobronchial
(liver)	hilar
gall bladder	(gastric)
(adrenal)	hepatic
(kidney)	mesenteric
ureter	colonic
(urinary bladder)	sublumbar
urethra	inguinal
OTHER:	

MICROBIOLOGY

☐ Lung

☐ Liver

☐ Brain

☐ Lymph node

☐

Gross necropsy abnormalities: - No mammary gland development
- Non pregnant uterus, smooth ovaries
- urinary bladder empty
- GI tract empty
- severe congestion & swelling of rugae. Severe focal ulcerations & erosions of mucosa. 2 volcanic ulcers
~ 20 Anisakids
- 4 + parafilaroides in lungs
- Myocardium pale, 1 focal white nodule 0.5cm x 3cm x 1mm on surface of right ventricle, on epicardium, not penetrating myocardium

TOPOGRAPHY	MORPHOLOGY	ETIOLOGY
1 Brain	Seizures	unknown
2 myocardium	focal pattern	"
3		
4		
5		

Cause of death (preliminary diagnosis): Toxicosis – suspect domoic acid.

The Marine Mammal Center
Marin Headlands, GGNRA
Sausalito, CA 94965

GROSS NECROPSY REPORT

Acc#	CSL 3769
Name	Digger
Tag#	–
Species	ZC.

Sex	F	SL 121 cm	BD 21 mm
Age	~~2yr~~ 1yr	AG 72 cm	UG 68 cm
Weight	33 kg. (estimate/actual)		
SON	emaciated 1 2 3 (4) 5 6 7 obese		

Form completed by	B Romnell	
Strand location	Oceano Dunes.	
Strand county	SLO	Euthanasia ☐ Yes ☒ No
Strand date	6/19/98	
Admit date	6/19/98	
Death date	6/19/98	Time
Post mortem date	6/20/98	Time 16-00

Carcass classification: (2) fresh
3 - fair, decomposed, organs intact
4 - poor, advanced decomposition
5 - mummified

Clinical signs/diagnosis	DOA, seizures on beach
Antibiotics given	–
Pertinent lab results	–

Photos ☐

Radiographs ☐

MICROBIOLOGY

☐ Lung

☐ Liver

☐ Brain

☐ Lymph node

☐

HISTOLOGY SAMPLES

(lung)	gonad
trachea	prostate
(heart)	uterus
aorta	penis
pulmonary artery	(eye) (L / R)
thymus	(brain)
salivary gland	spinal cord
thyroid	bone marrow
tonsil	(muscle)
tongue	(skin)
oesophagus	blubber
(stomach)	
(duodenum)	Lymph nodes:
(jejunum)	(submandibular)
(ileum)	cranial cervical
(colon)	(prescapular)
(pancreas)	(axillary)
(spleen)	(tracheobronchial)
(liver)	hilar
gall bladder	(gastric)
(adrenal)	hepatic
(kidney)	(mesenteric)
ureter	colonic
(urinary bladder)	sublumbar
urethra	inguinal
OTHER:	

Gross necropsy abnormalities:

SMALL (0.75cm DIA) ALOPECIA VENT. ABDOMEN
TRACHEOBRONCHIAL LNN REACTIVE; LUNGS CONGESTED
MESENTERIC LNN SLIGHTLY ENLARGED
FOCAL HYPERPLASIA IN ADRENAL CORTEX
URINARY BLADDER EMPTY.
STOMACH EMPTY

TOPOGRAPHY	MORPHOLOGY	ETIOLOGY
1 Brain	seizures	unknown
2		
3		
4		
5		

Cause of death (preliminary diagnosis): Toxicosis – suspect domoic acid.

The Marine Mammal Center
Marin Headlands, GGNRA
Sausalito, CA 94965

GROSS NECROPSY REPORT

Acc#	CSL 4024
Name	Fire Cracker
Tag#	13345
Species	Zalophulus Californianus

Sex	F	SL 72 cm	BD 13 mm
Age	Adult	AG 97 cm	UG 71 cm
Weight	79.1 kg. (estimate/actual)		
SON	emaciated 1 2 3 4 (5) 6 7 obese		

Form completed by	Shawn Johnson	
Strand location	Oceano Dunes	
Strand county	SLO	Euthanasia
Strand date	7/2/98	☒ Yes ☐ No
Admit date	7/2/98	Sub Telozol IM
Death date	7/12/98	Time 1300
Post mortem date	7/12/98.	Time 1500

Carcass classification: (2) fresh
3 - fair, decomposed, organs intact
4 - poor, advanced decomposition
5 - mummified

Clinical signs/diagnosis	lethargic, blind-?, tactile seizures, shaking
Antibiotics given	Amoxicillin, Tribrissen
Pertinent lab results	None

Photos ☐

Radiographs ☒ Neg Bullet

HISTOLOGY SAMPLES

(lung) trachea (heart) aorta pulmonary artery thymus salivary gland thyroid tonsil tongue oesophagus stomach duodenum (jejunum) ileum (colon) (pancreas) (spleen) (liver) (gall bladder) (adrenal) (kidney) ureter urinary bladder urethra OTHER:

(gonad) prostate uterus penis (eye (L)/R) (brain) spinal cord bone marrow (muscle) (skin) blubber

Lymph nodes: (submandibular) cranial cervical (prescapular) (axillary) (tracheobronchial) hilar gastric hepatic (mesenteric) colonic (sublumbar) inguinal

MICROBIOLOGY

☐ Lung

☒ Liver No growth at 48 hrs

☐ Brain

☒ Lymph node Rare coag. -ve staph.

☐

Gross necropsy abnormalities:

1) Nose - traumatic injury, smashed,
2) Teeth - worn, broken, old
3) Lymph nodes - generalized swollen, enlarged
Intestinal nodes - hemorrhagic, lymph decapitation
4) Lungs - congested, moist, diffuse, pos. livoides
5) Heart - myocardium pale streaking areas
6) Skin - pustular lesion on ventrum
7) Bladder/muscle - SQ emphysema, fat necrosis, (R) axillary region
small abscess in sternal muscles - 3cm x 4cm
8) Stomach - inflamed mucosa, ascarids >50
9) Kidneys - bilateral, swollen, purple, loss of differentiation
10) Brain - red mengies, pituitary - red-purple

*All lymph nodes swollen, enlarged

TOPOGRAPHY	MORPHOLOGY	ETIOLOGY
1 Nose	lesion - trauma induced	trauma
2 myocardium	Focal pattern	unknown
3 Brain	Seizures	unknown
4		
5		

Cause of death (preliminary diagnosis): Euthanasia - Suspect domoic acid toxicosis

The Marine Mammal Center
Marin Headlands, GGNRA
Sausalito, CA 94965

GROSS NECROPSY REPORT

Acc#	CSL 4162
Name	Abby / DOA
Tag#	—
Species	Zalophus californianus

Form completed by	J Gulland		
Strand location	Monterey Bure		
Strand county	Monterey	Euthanasia	
Strand date	8-25-98	☐ Yes	☒ No
Admit date	8-25-98		
Death date	8-25-98	Time 17:00	
Post mortem date	8-27-98	Time 13:00	

Carcass classification: (2) - fresh
(3) - fair, decomposed, organs intact
4 - poor, advanced decomposition
5 - mummified

Sex	F	SL 166 cm	BD mm
Age	Adult	AG 87 cm	UG 79 cm
Weight	73 kg. (estimate/actual)		
SON	emaciated 1 (2) 3 4 5 6 7 obese		

Clinical signs/diagnosis	Dead on arrival
Antibiotics given	—
Pertinent lab results	—

Photos ☒

Radiographs ☐

HISTOLOGY SAMPLES

(lung)	gonad
trachea	prostate
(heart)	(uterus)
aorta	penis
pulmonary artery	eye (L / R)
thymus	brain
salivary gland	spinal cord
thyroid	bone marrow
tonsil	muscle
tongue	skin
oesophagus	blubber
stomach	
duodenum	Lymph nodes:
jejunum	submandibular
ileum	cranial cervical
colon	prescapular
pancreas	axillary
spleen	tracheobronchial
(liver)	hilar
gall bladder	gastric
(adrenal)	hepatic
(kidney)	mesenteric
ureter	colonic
urinary bladder	sublumbar
urethra	inguinal

OTHER: mass

MICROBIOLOGY

☐ Lung

☐ Liver

☐ Brain

☐ Lymph node

☐

Gross necropsy abnormalities:

- Abscess 10x20x15 cm in (L) mammary tissue
- Kidneys swollen, severe loss of renal definition
- Adrenals enlarged, cortex : medulla 2:1
- Ovoid mass ~ 12cm x 8cm adhered to omentum containing fetal skeletal remains and liquid pus
- Omentum deep red, scattered fetal skeletal parts adhered to omentum
- (L) uterine horn has fibrosed scar ~ 2cm long, presumed site of rupture
- urinary bladder empty
- no follicles on ovaries
- GI tract empty

TOPOGRAPHY	MORPHOLOGY	ETIOLOGY
1 Kidney	Inflammation	Leptospira sp.
2 Omentum	Foreign body (fetus)	fetus
3 mammary gland	Abscess	bacteria
4 Uterus	Rupture	unknown
5		

Cause of death (preliminary diagnosis): Interstitial nephritis - suspect leptospirosis
- previous intra abdominal delivery of fetus

The Marine Mammal Center
Marin Headlands, GGNRA
Sausalito, CA 94965

GROSS NECROPSY REPORT

Acc#	CSL 4209
Name	Alice
Tag#	13487
Species	ZALOPHUS CALIFORNIANUS

Sex	F	SL 180 cm	BD 4 mm
Age	Adult	AG 98 cm	UG 87 cm
Weight	73 kg. (estimate/actual)		
SON	emaciated 1 (2) 3 4 5 6 7 obese		

Form completed by	L. HAULENA	
Strand location	MONASTERY BEACH	
Strand county	MONTEREY	Euthanasia ☐ Yes ☑ No
Strand date	10/10/98	
Admit date	10/10/98	
Death date	10/16/98	Time 13:05
Post mortem date	10/16/98	Time 13:10

Carcass classification: (2) fresh
3 - fair, decomposed, organs intact
4 - poor, advanced decomposition
5 - mummified

Clinical signs/diagnosis	SEIZURES, ACUTE DEATH DURING SEIZURE
Antibiotics given	AMOXICILLIN
Pertinent lab results	

Photos ☑

Radiographs ☐

HISTOLOGY SAMPLES

lung, trachea, heart, aorta, pulmonary artery, thymus, salivary gland, thyroid, tonsil, tongue, oesophagus, stomach, duodenum, jejunum, ileum, colon, pancreas, spleen, liver, gall bladder, adrenal, kidney, ureter, urinary bladder, urethra

gonad, prostate, uterus, penis, eye (L / R), brain, spinal cord, bone marrow, muscle, skin, blubber

Lymph nodes: submandibular, cranial cervical, prescapular, axillary, tracheobronchial, hilar, gastric, hepatic, mesenteric, colonic, sublumbar, inguinal

OTHER:

MICROBIOLOGY

☐ Lung

☐ Liver

☐ Brain

☐ Lymph node

☐

Gross necropsy abnormalities:

TUMOUR - MASS LOCATED IN (R) SUBLUMBAR REGION OF ABDOMINAL CAVITY FIRMLY ADHERED TO DORSAL MUSCULATURE ~ 13x14x8cm DIAMETER, ENCAPSULATED WITH IRREGULAR SURFACE, FILLED WITH PALE YELLOW M3 NECROTIC DEBRIS, MULTICAVITATING, M/P EXUDATE, TUMOUR RUNS THROUGH RETROPERITONEAL MUSCULATURE AND AFFECTS THE LUMBOSACRAL SPINE CAUSING MULTIFOCAL FRACTURES, OSTEOLYSIS, AND MULTIPLE LOOSE OSTEITIC FRAGMENTS

URETER - M3+ DILATION OF (R) URETER TO 6cm DIAMETER ALONG ENTIRE LENGTH, FORTH

KIDNEY - (R) M3 HYDRONEPHROSIS, SHRUNKEN, MULTIFOCAL UP TO 1.5cm DIAMETER SUBCAPSULAR FLUID FILLED CYSTS, M3 FLUID-FILLED DISTENDED RENAL PELVIS

(L) M1 LOSS OF RENAL DIFFERENTIATION, M1 PALLOR

LUNG - M3 MULTIFOCAL, GENERALIZED, FIRM, PALE YELLOW, RAISED NODULES ~ 5mm DIAMETER

MEDIASTINUM - M2-3 FIRM, YELLOW, MULTIFOCAL MASSES UP TO 1.5 cm DIAMETER

UTERUS - M1-2 CERVICAL HYPERPLASIA

SEE ATTACHED...

TOPOGRAPHY	MORPHOLOGY	ETIOLOGY
1 Lymph nodes	carcinoma	unknown
2 ureter	obstruction & blockage	carcinoma
3 kidney	hydronephrosis	carcinoma
4 lung	carcinoma	unknown
5 cervix	hyperplasia	carcinoma

Cause of death (preliminary diagnosis): METASTATIC CARCINOMA

The Marine Mammal Center
Marin Headlands, GGNRA
Sausalito, CA 94965

GROSS NECROPSY REPORT

Acc#	CSL 4209 cont'd
Name	ALICE
Tag#	
Species	

Sex		SL cm	BD mm
Age		AG cm	UG cm
Weight	kg. (estimate/actual)		
SON	emaciated 1 2 3 4 5 6 7 obese		

Form completed by	M. HAULENA	
Strand location		
Strand county		Euthanasia ☐ Yes ☐ No
Strand date		
Admit date		
Death date		Time
Post mortem date		Time

Carcass classification:
2 - fresh
3 - fair, decomposed, organs intact
4 - poor, advanced decomposition
5 - mummified

Clinical signs/diagnosis	
Antibiotics given	
Pertinent lab results	

Photos ☐

Radiographs ☐

HISTOLOGY SAMPLES

lung	gonad
trachea	prostate
heart	uterus
aorta	penis
pulmonary artery	eye (L / R)
thymus	brain
salivary gland	spinal cord
thyroid	bone marrow
tonsil	muscle
tongue	skin
oesophagus	blubber
stomach	
duodenum	Lymph nodes:
jejunum	submandibular
ileum	cranial cervical
colon	prescapular
pancreas	axillary
spleen	tracheobronchial
liver	hilar
gall bladder	gastric
adrenal	hepatic
kidney	mesenteric
ureter	colonic
urinary bladder	sublumbar
urethra	inguinal
OTHER:	

MICROBIOLOGY

☐ Lung

☐ Liver

☐ Brain

☐ Lymph node

☐

Gross necropsy abnormalities:

BRAINSTEM - M2-3 CONGESTION OF VESSELS ON VENTRAL SURFACE OF BRAIN

HEART - M1-2 DISTENSION, FLACCID MYOCARDIUM, M2 DILATATION OF PULMONARY ARTERY

PERICARDIAL SAC - ~ 20 ml SEROSANGUINOUS FLUID

LIVER - 4+ ZALOPHATREMA, M2 BILE DUCT HYPERPLASIA

TOPOGRAPHY	MORPHOLOGY	ETIOLOGY
1		
2		
3		
4		
5		

Cause of death (preliminary diagnosis):

~~The~~ Marine Mammal Center
Marin Headlands, GGNRA
Sausalito, CA 94965

GROSS NECROPSY REPORT

Acc#	CSL 4210
Name	Gill
Tag#	—
Species	Z. californianus

Form completed by	J Gulland		
Strand location	Marina State Beach		
Strand county	Monterey	Euthanasia	
Strand date	10/10/98	☐ Yes	☒ No
Admit date	10/10/98		
Death date	10/11/98	Time overnight	
Post mortem date	10/11/98	Time 12-00	

Sex	F	SL 160 cm	BD 30 mm
Age	Adult	AG 109 cm	UG 90 cm
Weight	95 kg. (estimate/actual)		
SON	emaciated 1 2 3 4 5 (6) 7 obese		

Carcass classification: (2) fresh
3 - fair, decomposed, organs intact
4 - poor, advanced decomposition
5 - mummified

Clinical signs/diagnosis	Seizures, flat out on arrival at TMMC, comatose
Antibiotics given	penicillin
Pertinent lab results	—

Photos ☐

Radiographs ☐

MICROBIOLOGY

☐ Lung

☐ Liver

☐ Brain

☐ Lymph node

☐

HISTOLOGY SAMPLES

(lung)	gonad
trachea	prostate
(heart)	(uterus)
aorta	penis
pulmonary artery	(eye) (L)
thymus	(brain)
salivary gland	spinal cord
(thyroid)	bone marrow
tonsil	muscle
tongue	skin
oesophagus	blubber
(stomach)	
duodenum	Lymph nodes:
jejunum	submandibular
(ileum)	cranial cervical
(colon)	prescapular
pancreas	(axillary)
(spleen)	tracheobronchial
(liver)	hilar
(gall bladder)	gastric
(adrenal)	hepatic
(kidney)	(mesenteric)
ureter	colonic
(urinary bladder)	sublumbar
urethra	inguinal

OTHER:

Gross necropsy abnormalities:

- gastric mucosa had multiple erosions + 5 volcanic ulcers
- stomach + ileum empty. Dry feces in colon + rectum
- urinary bladder distended with ~ 200 cc urine - golden yellow
- creamy opaque fluid in uterine horns. No pregnancy detected. Cervix tightly closed
- Adrenal C:M 2:1
- gallbladder distended: ~ 100 cc golden yellow bile
- ~ 50 cc blood tinged fluid in pericardium
- Myocardium pale orange
- mucosa around commissures of mouth
- mammary glands well developed, no milk detected

TOPOGRAPHY	MORPHOLOGY	ETIOLOGY
1 Brain	Seizures	Domoic acid
2		
3		
4		
5		

Cause of death (preliminary diagnosis): suspect domoic acid toxicity

The Marine Mammal Center
Marin Headlands, GGNRA
Sausalito, CA 94965

GROSS NECROPSY REPORT

Acc#	CSL 4214
Name	Mossy
Tag#	
Species	13451 Zalophus californianus

Sex	F	SL 155 cm	BD 14 mm
Age	Adult	AG 109 cm	UG 79 cm
Weight	77.5 kg. (estimate/actual)		
SON	emaciated 1 2 3 4 5 (6) 7 obese		

Form completed by	M. Paulena		
Strand location	Mahoneys Restaurant		
Strand county	~~Santa Cruz~~ Monterey	Euthanasia	
Strand date	10-11-98	☐ Yes	☒ No
Admit date	10-11-98		
Death date	10-15-98	Time 2330	
Post mortem date	10-16-98	Time 1200	

Carcass classification: (2) - fresh
3 - fair, decomposed, organs intact
4 - poor, advanced decomposition
5 - mummified

Clinical signs/diagnosis	Seizures, anorexia
Antibiotics given	Dual Pen
Pertinent lab results	within normal limits

Photos ☐

Radiographs ☐

HISTOLOGY SAMPLES

lung	gonad
trachea	prostate
heart	uterus
aorta	penis
pulmonary artery	eye (L / R)
thymus	brain
salivary gland	spinal cord
thyroid	bone marrow
tonsil	muscle
tongue	skin
oesophagus	blubber
stomach	
duodenum	Lymph nodes:
jejunum	submandibular
ileum	cranial cervical
colon	prescapular
pancreas	axillary
spleen	tracheobronchial
liver	hilar
gall bladder	gastric
adrenal	hepatic
kidney	mesenteric
ureter	colonic
urinary bladder	sublumbar
urethra	inguinal

OTHER:

MICROBIOLOGY

☐ Lung

☐ Liver

☐ Brain

☐ Lymph node

☐

Gross necropsy abnormalities:

MAMMARY TISSUE - LACTATING
STOMACH - MZ GASTRIC ULCERATION, MULTIFOCAL, UP TO 1cm DIAMETER, 2+ ANISAKIS
→ NON-VOLCANIC
UTERUS - (L) HORN, MILD FOCAL DILATION ~ 2cm DIAMETER, MILD HEMORRHAGE ON CUT SURFACE

TOPOGRAPHY	MORPHOLOGY	ETIOLOGY
1 Brain	Seizures	Domoic acid
2 ~~[illegible]~~	~~[illegible]~~	
3		
4		
5		

Cause of death (preliminary diagnosis): ~~OPEN~~ Domoic acid toxicity

The Marine Mammal Center
Marin Headlands, GGNRA
Sausalito, CA 94965

G SS NECROPSY REPORT

Acc#	CSL 4218
Name	Erica
Tag#	13465
Species	Zalophus californianus

Form completed by	Diane Paschall		
Strand location	Marina St. Bch.		
Strand county	Monterey	Euthanasia	
Strand date	10-15-98	☐ Yes	☒ No
Admit date	10-16-98		
Death date	10-20-98	Time found early am	
Post mortem date	10-20-98	Time 1130	

Sex	F	SL 153 cm	BD 11 mm
Age	Adult	AG 91 cm	UG 75 cm
Weight	66 kg. (estimate/actual)		
SON	emaciated 1 2 (3) 4 5 6 7 obese		

Carcass classification: (2) - fresh
3 - fair, decomposed, organs intact
4 - poor, advanced decomposition
5 - mummified

Clinical signs/diagnosis	Seizures, jaw misaligned, found dead @ pool bottom.
Antibiotics given	Amoxicillin, Dual Pen
Pertinent lab results	Within normal limits

Photos ☐

Radiographs ☒

MICROBIOLOGY

☐ Lung

☐ Liver

☐ Brain

☐ Lymph node

☐

HISTOLOGY SAMPLES

(lung)	(gonad)
(trachea)	prostate
(heart)	(uterus)
(aorta)	penis
(pulmonary artery)	eye (L / R)
(thymus)	(brain)
(salivary gland)	(spinal cord)
(thyroid)	bone marrow
tonsil	muscle
(tongue)	skin
(oesophagus)	blubber
(stomach)	
(duodenum)	Lymph nodes:
(jejunum)	submandibular
(ileum)	cranial cervical
(colon)	prescapular
(pancreas)	(axillary)
(spleen)	(tracheobronchial)
(liver)	(hilar)
(gall bladder)	(gastric)
(adrenal)	hepatic
(kidney)	(mesenteric)
ureter	colonic
(urinary bladder)	sublumbar
(urethra)	inguinal
OTHER:	

Gross necropsy abnormalities:

Hilar, tracheobronchial lymph nodes gelatinous, enlarged, dark.
Lungs - severe interstitial edema, fluid in bronchi & trachea
Kidneys - (R) kidney dark purple (almost black) on cut surface
Urinary bladder - empty
Uterus - small yellow nodule on connective tissue (R) of uterus, vessels around uterus engorged.
Adrenals - cortex striated, thickened.
Stomach - Small amount of thick yellow fluid, one piece of styrofoam, otherwise empty.
Mandible - fracture (L) side, misplaced one inch off normal alignment, lower (L) canine broken @ gum line

TOPOGRAPHY	MORPHOLOGY	ETIOLOGY
1 Brain	seizures	unknown
2 mandible	fracture	trauma
3 Lungs	edema	unknown
4		
5		

Cause of death (preliminary diagnosis): Possible domoic acid toxicity. Seizures. Fractured mandible

The Marine Mammal Center
Marin Headlands, GGNRA
Sausalito, CA 94965

GROSS NECROPSY REPORT

Acc#	CSL 4220
Name	Cookie
Tag#	13447
Species	Zalophus californianus

Sex	F	SL 152 cm	BD 10 mm
Age	Adult	AG 93 cm	UG 68 cm
Weight	56.5 kg. (estimate/actual)		
SON	emaciated 1 2 3 4 5 6 7 obese		

Form completed by	Liane Paschali	
Strand location	Cambria	
Strand county	SLO	Euthanasia ☐ Yes ☒ No
Strand date	10-17-98	
Admit date	10-17-98	
Death date	10-20-98	Time 1515
Post mortem date	10-21-98	Time 1000

Carcass classification: (2) - fresh; 3 - fair, decomposed, organs intact; 4 - poor, advanced decomposition; 5 - mummified

Clinical signs/diagnosis	Seizure, underweight, depressed.
Antibiotics given	Dual Pen
Pertinent lab results	WBC=22.5 x10³, Na Cl 144, PCV 10.07, BUN 72.7

Photos ☒

Radiographs ☐

HISTOLOGY SAMPLES

lung	gonad
trachea	prostate
heart	uterus
aorta	penis
pulmonary artery	eye (L / R)
thymus	brain
salivary gland	spinal cord
thyroid	bone marrow
tonsil	muscle
tongue	skin
oesophagus	blubber
stomach	
duodenum	Lymph nodes:
jejunum	submandibular
ileum	cranial cervical
colon	prescapular
pancreas	axillary
spleen	tracheobronchial
liver	hilar
gall bladder	gastric
adrenal	hepatic
kidney	mesenteric
ureter	colonic
urinary bladder	sublumbar
urethra	inguinal
OTHER:	

MICROBIOLOGY

☐ Lung

☐ Liver

☐ Brain

☐ Lymph node

☐

Gross necropsy abnormalities:

* brain removed 10/20/98 1530
lungs - abscesses throughout, 3+ Parafilaroides
pancreas - thickened; pancreatic l.n enlarged, black
spleen - one small pinpoint nodule, yellow
mesentery - small yellow nodule
sublumbar l.n - 3cm x 2.5cm, hard, thick pasty pus, tumor?
adrenals - enlarged, cortex dark
All abdominal lymph nodes enlarged.
kidneys - sl. enlarged, small nodule on surface of (R) kidney
uterus - (R) horn thickened, cervix open

TOPOGRAPHY	MORPHOLOGY	ETIOLOGY
1 Brain	seizure	unknown
2 "	hemorrhage	"
3 Lymph node	neoplasia	unknown
4 Lung	abscesses	"
5 Spleen	" /neoplasia?	"

Cause of death (preliminary diagnosis): Verminous pneumonia. Cerebellar hemorrhage, Early carcinoma?

The Marine Mammal Center
Marin Headlands, GGNRA
Sausalito, CA 94965

ROSS NECROPSY REPORT

Acc#	NFS123
Name	Mothra
Tag#	—
Species	Callorhinus ursinus

Form completed by	J Gulland		
Strand location	Pajaro Dunes		
Strand county	Santa cruz	Euthanasia	
Strand date	5/24/98	☒ Yes	☐ No
Admit date	5/24/98		
Death date	5-26-98	Time	0900
Post mortem date	5-26-98	Time	0900

Carcass classification: (2) fresh
3 - fair, decomposed, organs intact
4 - poor, advanced decomposition
5 - mummified

Sex	F	SL 118 cm	BD 2 mm	
Age	1-2 yr	AG 62 cm	UG 47 cm	
Weight	25 kg. (estimate/actual)			
SON	emaciated 1 (2) 3 4 5 6 7 obese			

Clinical signs/diagnosis	Ataxia, weakness progressing to coma
Antibiotics given	—
Pertinent lab results	—

ARCHIVES	
Bullets	#
Pellets	#
Gillnet/Line/Hooks/Rocks	

STORED SAMPLES			
Tissue blub, muscle, liv, kid, bm, bile	Test tox	Sent to TMMC	
Tissue lung, liver, kidney	Test virol	Sent to "	
Tissue stomach, urine, feces	Test biotoxins	Sent to "	

HISTOLOGY SAMPLES	
(lung)	(gonad)
trachea	prostate
(heart)	uterus vagina
aorta	penis
(pulmonary artery)	eye (L / R)
thymus	(brain)
(salivary gland)	spinal cord
(thyroid)	bone marrow
(tonsil)	(muscle) - masseter
tongue	skin
(oesophagus)	blubber
(stomach)	
duodenum	Lymph nodes:
(jejunum)	(submandibular)
ileum	cranial cervical
(colon)	prescapular
(pancreas)	axillary
(spleen)	(tracheobronchial)
(liver)	hilar
(gall bladder)	(gastric)
(adrenal)	hepatic
(kidney)	(mesenteric)
ureter	colonic
(urinary bladder)	sublumbar
urethra	inguinal
OTHER:	

ANCILLARY DIAG	MICROBIOLOGY
☐ Photos	☐ Lung
☐ Kidney smear	☒ Liver g-ve rod
☒ Tooth for aging	☐ Intestine
☐ Radiographs	☐ Lymph node
☐ Parasites	☐ Brain
	☒ Uterus g+ve rod

Gross necropsy abnormalities:

- Ulcers on nasoseptum, black tarry feces, pale masseter muscle
- ~~[illegible]~~ cyst 3cm x 2cm on mesovarium of left ovary
- ~~[illegible]~~
- adrenal c:m = 2:1
- kidneys - swollen, pale tan renal cortices
- green pus in vagina.
- GI tract empty - large volcanic ulcer in stomach ~~[illegible]~~ containing nematode larvae

TOPOGRAPHY	MORPHOLOGY	ETIOLOGY
1 Brain	Seizure	unknown
2 Ovary	cyst	unknown
3 vagina	suppurative inflammation	unknown
4 stomach	ulcer	Anisakis
5		

Cause of death (preliminary diagnosis): ?? Toxicosis

APPENDIX 6: HISTOPATHOLOGY REPORTS

COLORADO VETERINARY DIAGNOSTIC LABORATORY
College of Veterinary Medicine and Biomedical Sciences
Colorado State University, Fort Collins, CO 80523
Phone 970-491-1281 Fax 970-491-0320

DL#: 978-38161
Date: 6/98

Vet/Clinic: Francis Gulland/Marine Mammal Center
Owner: Marine Mammal Center
Animal ID: Mothra/#NFS123 **Date Specimen Taken:** 5-26-98
Species: Callorhinus ursinus **Breed:** NFS **Age:** A **Sex:** F

History: Ataxia, weakness, progressing to coma.

DIAGNOSIS: 1/Neuronal necrosis with edema, severe, hippocampal region and cuneate nucleus, amygdaloid nuclear complex, and thalamus, brain.

2/Mild cardioedema, multifocal with myocardial degeneration, mild, heart.

3/Biliary stasis, moderate, diffuse, acute, subacute, liver.

4/Multifocal necrosis, acute, cortex, adrenal gland.

5/Ulcerative dermatitis, flipper.

COMMENTS: The primary lesions in this animal are the neuronal necrosis and edema of the neuropil with extensive intramyelinic edema of the brain. Primary lesions of neuronal necrosis include hippocampus and amygdaloid nuclear complex. Evidence of severe neuronal degeneration are found within the deep layers of the cortical gray roof nuclei of the cerebellum, a few in the Purkinje cell layer, and severe degeneration with edema within the ventral caudal lateral and central caudal medial nuclei of the thalamus, and with the nucleus of the habenular interpeduncular tract nucleus. This animal also had myocardial edema with an extremely early myocardial degeneration as found in the California Sea Lions. This animal also had multifocal areas of necrosis of the adrenal cortex. The cause of these was not determined and intranuclear inclusions were not observed. This animal did have diffuse bile stasis and an ulcer of the flipper.

GROSS NECROPSY: This animal has an ulcer on the nasal septum and black tarry feces with pale macideric muscles of the head. There is a 3x2cm cyst on the mesoovarium of the left ovary. The adrenals are normal. The kidneys are slightly swollen and there is green exudate within the vagina. The GI tract is empty. There is one volcanic ulcer in the stomach containing nematodes.

HISTOPATHOLOGY: 1/This section is at the level of the caudate nucleus. The cingulate gyrus is normal. The caudate nucleus appears to be normal. The olfactory stria and olfactory nuclear area is within normal limits. The septal nuclei are normal. There is a mild degree of intramyelinic edema of the internal capsule in this region. Corpus callosum in this area is normal.

2/Hypothalamus - The cingulate gyrus and corpus callosum are normal within this region. There is a mild degree of edema within the thalamus in this region and there are a few necrotic neurons, especially in the rhomboid nucleus of the thalamus, the medial dorsal nucleus, the anterior medial nucleus and in the medial dorsal nucleus of the thalamus. The number of neurons that are necrotic are few and there is a mild degree of edema, especially within these nuclei also. Intramyelinic edema can also be found within the internal capsule in this region. The hypothalamus is within normal limits. A cross-section of the optic chiasm in this area does show a few axons that have intramyelinic edema. No evidence of lymphocytic cuffing is found in any of these areas. The corpus callosum and fornix of the hippocampus are normal within this region. The distal end of the globus pallidas is normal within this area.

3/Thalamus/habenular nucleus - The nuclei of the thalamus in this region show extremely mild edema and a few necrotic neurons, whereas if intra caudal lateral and ventral caudal medial nucleus in this region show extensive edema and neuronal vacuolization and degeneration. Another interesting finding in this section is that the neurons of the habenular nucleus are relatively normal, although there is an extremely small amount of edema within this nucleus. However, many of the neurons of the nucleus of the habenulopeduncular tract are necrotic. This section also contains a portion of hypothalamus and pituitary stalk, of which are within normal limits. Only an occasional axon within the corporus colosum is found with intramyelinic edema.

4/Thalamus/habenular nucleus/mamillary body - The mamillary body in this region is within normal limits. Nuclei of the habenular nucleus are normal. There is extensive edema and neuronal

degeneration within the ventral caudal lateral and ventral caudal medial nuclei of the thalamus. Extensive intramyelinic edema is also found within this region. True intramyelinic edemas is also found in the internal capsule in this area. The cingulate gyrus in this region is considered within normal limits.

5/Brain stem/level of superior colliculus/exit of ocular motor nerve/tail C4 of the hippocampus - The superior colliculus in this region is within normal limits. The gray substance is also normal. The ocular motor nucleus does have evidence of a small degree of neuropil edema but no significant lesions are observed. The interstitialis nucleus is normal. This nucleus is just adjacent to the ocular motor nucleus. The large white tracts of the ocular motor nucleus and part of the ocular motor nerve are relatively normal. The red nucleus and the substantia nigrà are relatively normal. This section contains just the tail of the caudal lateral, poster caudal lateral, and poster caudial medial nucleus of the thalamus; these areas are affected by severe edema and neuronal degeneration.

This section contains hippocampus, probably in the C3 region or at least posterior half of the hippocampus. Extensive necrosis is found within the large parametal cell layer. Nearly all of these neurons are necrotic. Extensive edema is also found within this region. Extensive necrosis of nearly all of the neurons of the molecular cell layer are necrotic. The degree of edema that is found within the stratum radiatum in the California Sea Lions is not as evident in this section of hippocampus from this first seal. There is also necrosis and edema within this section of amygaloid nuclear area.

6/Brain stem/superior colliculus/anterior aspect of pontine area - The corpus of the superior colliculus, central gray substance, the trochlear nucleus, the substantia nigra, and red nucleus are all within normal limits. There is a mild degree of intramyelinic edema within the fibers of the pons, but the pontine nuclei are relatively normal. The intrapeduncular nucleus in this region is considered normal. The overall amount of intramyelinic edema through this section of brain is extremely minimal as compared to the thalamic area.

7/Cerebrum - This section contains extensive edema of the gray matter and moderate intramyelinic edema of some of the white matter tracts. Neuronal degeneration is present within the deep cortical gray but acute neuronal necrosis was not observed.

8/This section contains areas of hippocampus, more in the middle region. No lesions are found in this area. The laterogeniculate body in this region does contain a small area of edema with vessels that are cuffed with lymphocytes. Neuronal necrosis is not observed. The cerebrum in this region also shows mild edema of the neuropil. This region is most likely the amygdaloid nuclear complex.

9/Brain stem/pons - This is in the mid-pontine nuclear area. There is an extremely mild degree of edema within the central gray substance but no evidence of neuronal necrosis or degeneration. There is mild intramyelinic edema throughout the pons, but the neurons are relatively normal.

10/Pineal body - This section is within normal limits.

Obex - This section is characterized by no lesions observed in the dorsal vagus nucleus and the hypoglossal nucleus, or the raphe and the olive nuclei. The nucleus of the spinal tract of the trigeminal nerve and the axons of this nucleus appear to be relatively normal. However, there are many large vacuolated areas, some of which contains edema, within the cuneate nucleus and just surrounding the cuneate nucleus, probably in some of the tracts in this region.

Spinal cord - Section of spinal cord is from C1 region. This section is within normal limits. The large white tracts for proprial seption are all normal within this area, so evidently, this affect of a ventral caudal lateral medial nucleus of the thalamus and the cuneate nucleus is relatively restricted to these regions, and does not extend into the white matter tracts of proprial seption, at least of the anterior cord.

11/Cerebellum - The molecular layer is normal. There is no edema in the Purkinje cell layer but there is an occasional Purkinje cell that appears to be undergoing necrosis. The granular cell layer is normal. There is a mild to moderate degree of intramyelinic edema within the white matter tracts. There is moderate edema and neuronal degeneration within the axons of the roof nuclei.

Lungs - No significant lesions (NSL).

Thyroid gland - The follicles of the thyroid gland are within normal limits. There is one small cyst within this section that contains a few papillary projections of hyperplastic follicular cells. This is considered an incidental finding.

Stomach - This section contains a large gastric ulceration that extends down into the submucosa. Numerous large nematodes are present within this section. The inflammation around this area is composed primarily of lymphocytes, plasma cells, a few macrophages and neutrophils. Often times, small degenerated cuticle material is found deep within this lesion and these are often surrounded more by mononuclear cells. This lesion does not extend to the serosa.

Esophagus - NSL.

Pharyngeal epithelium - NSL.

Kidneys - NSL.

Small intestines - Multiple sections are examined and all are within normal limits. No lesions are found within the myenteric plexus in this animal.

Stomach - This section is within normal limits.

Myocardium - There are a few small focal areas of myocardial edema and early myocardial degeneration scattered throughout this section. No evidence of inflammation is found within these small areas of edema and early myocardial degeneration.

Esophagus - The epithelium of the esophagus is normal. There are a few skeletal muscle cells within the esophagus that are undergoing acute degeneration.

Liver - There are a few extra lymphocytes within the adventitia of hepatic portal triad regions. This is minimal and not considered significant. There is a moderate degree of yellow/brown pigment within biliary canaliculi suggesting a moderate degree of bile stasis is present throughout this section of liver.

15/Liver - This section is identical to what was previously described. The hepatocytes are relatively small and atrophied, suggesting this animal is perhaps emaciated.

Large intestines - There is a slightly increased number of lymphocytes and plasma cells within the lamina propria of this section of ileum and cecum. There is one cross-section of a tapeworm in this region. There are also a few other dilated crypts containing cellular debris. These lesions are typical of the intestinal tract associated with mild parasitism.

Mesenteric lymph node - This lymph node is relatively active, however, there is one nodule within the mesentery that is composed of several cross-sections of a nematode associated with an extensive infiltration of inflammatory cells. This nematode is an adult male. This is identified by the size of the intestinal tract and reproductive tract, and the cross-section through two spicules.

Flipper - There is an ulcer on the flipper of this animal. This ulcer is characterized by extensive necrosis of the epithelial layer and there is an extensive infiltration of lymphocytes, plasma cells and macrophages underneath the bed of the ulcer. There is no evidence of ballooning degeneration in this lesion.

16/Gall bladder - NSL.

Tonsil - This section contains numerous active follicles. There is one small abscess within the tonsil that is composed of numerous neutrophils associated with a small amount of edema.

Adrenal gland - This adrenal gland is within normal limits.

Mesenteric lymph node - This lymph node is within normal limits.

Aorta - NSL.

Skeletal muscle - This section is within normal limits.

Small intestines - NSL.

Large intestines - This section does contain one cross-section of a parasite, probably a tapeworm; otherwise, this section is within normal limits.

18/Spleen - The lymphoid tissue is quiescent but within normal limits. There are a few areas of siderotic plaque formation within this section of spleen.

Lungs - There is one small focus of inflammation but otherwise, the lungs are considered to be within normal limits.

Adrenal gland - There are multifocal areas of acute coagulative necrosis within the adrenal gland cortex. These lesions are relatively similar to what is observed in Harbor Seals with herpes virus infection, however, intranuclear inclusions were not found in these areas of necrosis. Hemorrhage is also present in several of these areas of acute coagulative necrosis.

19/Stomach - NSL.

Thyroid - Follicles of this section of thyroid are within normal limits.

21/Hippocampus - This area of hippocampus is characterized by extensive neuronal necrosis and the edema of the neuropile within the parameter cell layer and within the molecular cell layer.

22/Hippocampus - This section of hippocampus is also characterized by extensive necrosis within the parameter cell layer with severe edema of the neuropil in this region. The degree of edema within the stratum radiatum is present but not as prominent as in the California Sea Lions. Necrosis and edema are present within the molecular cell layer.

Cerebellum/roof nuclei - This section is similar to what was previously described where there is edema and severe cellular and nuclear degeneration within the roof nuclei. The degree of intramyelinic edema of the white matter tracts in this area is minimal compared to other slides.

Terry Spraker, DVM/PhD

Typed: 6-18-98 ml

DEPARTMENT OF DEFENSE
ARMED FORCES INSTITUTE OF PATHOLOGY
WASHINGTON DC 20306-6000

REPLY TO ATTENTION OF

August 12, 1998

2632310-5 00
ANIMAL, PINNIPEDIA SEA LION
CSL 3690 T "JAKARTA"
TPL/BHW/BHS/mab

Dr. Frances Gulland
The Marine Mammal Center
Marin Headlands, GGNRA
Sausalito, CA 984965

AFIP DIAGNOSIS:

CSL 3690 1. Brain, hippocampus: Neuronal loss, segmental, mild, with gliosis, California sea lion (*Zalophus californianus*), pinniped.
2. Heart, myocardiocytes: Necrosis, multifocal, with moderate neutrophilic myocarditis.
3. Vagina; cervix; uterus: Intraepithelial neoplasia.
4. Stomach: Ulcer, focally extensive.
5. Liver: Necrosis, centrilobular, multifocal.
6. Adipose tissue, multiple sites: Atrophy, diffuse, moderate.
7. Lung: Pneumonia, interstitial, histiocytic and eosinophilic, multifocal, mild to moderate, with occasional intrabronchial nematodes and edema.
8. Brain and spinal cord, meninges: Meningitis, lymphocytic, multifocal, mild with multifocal hemorrhage and hemosiderosis.
9. Esophagus: Esophagitis, subacute and suppurative, with underlying salivary duct ectasia.
10. Mitral valve; aorta; salivary gland; small intestine; large intestine; urinary bladder; pancreas; gallbladder; mammary gland; adrenal gland; thyroid gland; skeletal muscle; kidney; ovary; pituitary gland: No significant lesions.

COMMENT: The lesions in the hippocampus and heart are similar to those observed in other sea lions and believed to be caused by domoic acid poisoning. The intraepithelial neoplasia in the genital tract is a premalignant change. Neither invasive nor metastatic genital carcinoma was observed. The atrophy of adipose tissue indicates that this animal was in poor nutritional condition. The most likely cause of the centrilobular hepatic necrosis is hypoxia resulting from terminal circulatory collapse.

Thomas P. Lipscomb, DVM, DACVP
LTC, VC, USA
Chief, Division of Veterinary Pathology

for Bruce H. Williams, DVM, DACVP
Department of Veterinary Pathology

Department of Veterinary Pathology, Building 54, Room G-117, 14th St. and Alaska Ave NW, Washington, D.C. 20306-6000
Phone: 202-782-2600 DSN: 662-2600 fax: 202-782-9150 Email: afipvet@email.afip.osd.mil

Printed on Recycled Paper

DEPARTMENT OF DEFENSE
ARMED FORCES INSTITUTE OF PATHOLOGY
WASHINGTON DC 20306-6000

REPLY TO
ATTENTION OF

June 22, 1998

2632308-9 00
ANIMAL, PINNIPEDIA SEA LION
CSL 3691 T. "ANGELO"
TPL/LAM/TWB/mab

Dr. Frances Gulland
The Marine Mammal Center
Marin Headlands, GGNRA
Sausalito, CA 984965

AFIP DIAGNOSIS:

CSL 3691 1. Brain, area of the hippocampus: Meningoencephalitis, lymphoplasmacytic, multifocal, moderate, with neuronal loss, gliosis and rare neuronal necrosis, California sea lion, (*Zalophus californianus*), pinniped.
2. Lymph nodes, multiple sites: Lymphoid necrosis, germinal centers, multifocal, extensive, with follicular and paracortical lymphoid hyperplasia.
3. Liver: Necrosis, multifocal, with neutrophilic inflammation.
4. Heart, cardiomyofibers: Necrosis, multifocal, with neutrophilic inflammation.
5. Lung: Congestion, acute, diffuse, moderate, with alveolar and interstitial edema.
6. Lung: Pneumonia, interstitial, lymphoplasmacytic, chronic, multifocal, mild, with intra-alveolar adult nematodes, etiology consistent with *Parafilaroides decorus*.
7. Kidney: Nephritis, interstitial, lymphoplasmacytic, multifocal, mild.
8. Uterus: Metritis, lymphoplasmacytic and histiocytic, chronic, multifocal, mild to moderate, with mucosal congestion, edema, and hemosiderosis.
9. Pancreas: Islet cell tumor.
10. Stomach; colon: Nematode parasites.
11. Spleen; salivary gland; fibroelastic artery; adrenal gland; urinary bladder; thyroid gland; pituitary gland; skeletal muscle; ovary; cervix; vagina: No significant lesions.

COMMENT: This is one of approximately fifty sea lions affected by a seizure disease that died or were euthanized over a ten day period. The cause of the brain lesions in the area of the hippocampus is not evident; it may be a result of domoic acid poisoning. The lymphoid and myocardial necrosis may also be associated with this toxin. Although the islet cell tumor is very small, if it was functional, it might have contributed to seizures. The other lesions are incidental findings.

Thomas P. Lipscomb, DVM, DACVP
LTC, VC, USA
Chief, Division of Veterinary Pathology

for Lu Ann McKinney, DVM, DACVP
LTC, VC, USA
Division of Veterinary Pathology

Department of Veterinary Pathology, Building 54, Room G-117, 14th St. and Alaska Ave NW, Washington, D.C. 20306-6000
Phone: 202-782-2600 DSN: 662-2600 fax: 202-782-9150 Email: afipvet@email.afip.osd.mil

Printed on Recycled Paper

DEPARTMENT OF DEFENSE
ARMED FORCES INSTITUTE OF PATHOLOGY
WASHINGTON DC 20306-6000

REPLY TO ATTENTION OF

August 25, 1998

2632315-4 00
ANIMAL, PINNIPEDIA SEA LION
CSL3692 T "JORDAN"
TPL/LDY/mab

Dr. Frances Gulland
The Marine Mammal Center
Marin Headlands, GGNRA
Sausalito, CA 984965

AFIP DIAGNOSES:

CSL3692 1. Brain, hippocampus: Necrosis, neuronal, multifocal, moderate numbers of neurons, with moderate diffuse lymphoplasmacytic meningoencephalitis, California sea lion *(Zalophus californianus)*, pinniped.
2. Cerebrum and cerebellum: Meningitis, lymphoplasmacytic, multifocal, mild.
3. Spleen, white pulp; lymph node, multiple sites, follicles: Lymphoid depletion, diffuse, moderate, with follicular lymphoid necrosis.
4. Lung: Bronchopneumonia, neutrophilic and histiocytic, subacute, multifocal, mild.
5. Small intestine: Enteritis, neutrophilic and histiocytic, multifocal, mild.
6. Liver: Hepatitis, portal, chronic-active, diffuse, moderate.
7. Thymus: Interlobular edema, diffuse, moderate.
8. Vagina: Vaginitis, neutrophilic and histiocytic, subacute, multifocal, mild, with mucopurulent exudate and rare intraluminal metazoan parasite eggs and rare microfilaria.
9. Cervix: Cervicitis, neutrophilic and histiocytic, subacute, multifocal, mild, with neutrophilic exudate.
10. Heart; stomach; large intestine; skeletal muscle; urinary bladder; gallbladder; adrenal gland; kidney; thyroid gland; uterus; spinal cord; and pituitary gland: No significant lesions.

COMMENT: The neuronal necrosis in the hippocampus and the lymphoid depletion and necrosis may have been caused by domoic acid poisoning; similar findings have been noted in sea lions believed to have died from that intoxication. The cause of the inflammation in the brain and meninges is undetermined. RT-PCR testing for morbilliviral RNA is negative. The causes of the other lesions are not evident. The presence of parasite eggs and microfilaria in the vaginal lumen is unusual.

Thomas P. Lipscomb, DVM, DACVP
LTC, VC, USA
Chief, Division of Veterinary Pathology

Department of Veterinary Pathology, Building 54, Room G-117, 14th St. and Alaska Ave NW, Washington, D.C. 20306-6000
Phone: 202-782-2600 DSN: 662-2600 fax: 202-782-9150 Email: afipvet@email.afip.osd.mil

Printed on Recycled Paper

DEPARTMENT OF DEFENSE
ARMED FORCES INSTITUTE OF PATHOLOGY
WASHINGTON DC 20306-6000

REPLY TO
ATTENTION OF

June 29, 1998

2632682-7 00
ANIMAL, PINNIPEDIA SEA LION
CSL 3699 T "SALLEE"
TPL/ES/mab

Dr. Frances Gulland
The Marine Mammal Center
Marin Headlands, GGNRA
Sausalito, CA 984965

AFIP DIAGNOSES:

CSL 3699 1. Cerebrum, hippocampus: Necrosis, neuronal, diffuse, with diffuse spongiosis and minimal to mild lymphoplasmacytic encephalitis and choriomeningitis, California sea lion (*Zalophus californianus*), pinniped.
2. Heart: Edema, interstitial, multifocal, mild to moderate, with individual myofiber necrosis and mild subacute inflammation.
3. Heart, epicardium: Hemorrhage, acute, focally extensive, moderate, with fibrin deposition.
4. Small intestine: Enteritis, neutrophilic, lymphoplasmacytic, and eosinophilic, multifocal, moderate, with multifocal fibrin thrombi and submucosal edema.
5. Placenta: Necrosis, multifocal, with hemorrhage and mild acute inflammation.
6. Lung: Bronchopneumonia, granulomatous and eosinophilic, multifocal, mild, with intrabronchiolar metastrongylid nematodes, etiology consistent with *Parafilaroides decorus*.
7. Small intestine: Trematodes, mucosal, multiple.
8. Small intestine, submucosal: Enteritis, granulomatous, multifocal, mild, with nematode larvae.
9. Adipose tissue, multiple sites: Atrophy, mild.
10. Liver: Hepatitis, granulomatous and eosinophilic, random and portal, multifocal, mild, with larval nematodes.
11. Kidney: Cyst, focally extensive, with adjacent atrophy, fibrosis and mild chronic inflammation.
12. Kidney: Hydronephrosis, mild.
13. Tonsil: Cyst, focal.
14. Aorta; trachea; lymph nodes, multiple; pancreas; tongue; salivary gland; esophagus; stomach; skeletal muscle; urinary bladder; spleen; haired skin; ovaries; uterus; thyroid gland; adrenal glands; pituitary gland; spinal cord: No significant lesions.

Department of Veterinary Pathology, Building 54, Room G-117, 14th St. and Alaska Ave NW, Washington, D.C. 20306-6000
Phone: 202-782-2600 DSN: 662-2600 fax: 202-782-9150 Email: afipvet@email.afip.osd.mil

Printed on Recycled Paper

COMMENT: There is necrosis of neurons of all segments of the hippocampus. While neuronal necrosis is often caused by hypoxia and ischemia, and may be a nonspecific change associated with seizures, the relatively diffuse involvement of the hippocampus and the sparing of neurons that tend to be susceptible to hypoxic/ischemic injury in other areas of the brain, combined with the history of probable exposure supports domoic acid poisoning as the likely cause of the necrosis. Experimentally, similar hippocampal lesions have been found in rats injected with domoic acid. While the cardiac lesions are probably due to ischemia, they may have been potentiated by the hemodynamic affects of the hyperstimulated hippocampal neurons. The hippocampus plays an important role in regulating heart rate and arterial pressure, and myocardial lesions have been found in rats injected with kainic acid, an excitotoxin very similar to domoic acid. The cause of the placental necrosis is not evident; it may be secondary to seizures. The other lesions listed above include parasite-associated inflammatory lesions and other incidental findings.

Thomas P. Lipscomb, DVM, DACVP
LTC, VC, USA
Chief, Division of Veterinary
Pathology

Department of Veterinary Pathology, Building 54, Room G-117, 14th St. and Alaska Ave NW, Washington, D.C. 20306-6000
Phone: 202-782-2600 DSN: 662-2600 fax: 202-782-9150 Email: afipvet@email.afip.osd.mil

DEPARTMENT OF DEFENSE
ARMED FORCES INSTITUTE OF PATHOLOGY
WASHINGTON DC 20306-6000

REPLY TO
ATTENTION OF

July 7, 1998

2632681-9 00
ANIMAL, PINNIPEDIA SEA LION
CSL 3699F T "FETUS"
TPL/FYS/TJ/jmk

Dr. Frances Gulland
The Marine Mammal Center
Marin Headlands, GGNRA
Sausalito, CA 984965

AFIP DIAGNOSIS:

CSL3699F Lung; trachea; pancreas; heart; aorta; lymph node; thymus; duodenum; stomach; gall bladder; colon; jejunum; ileum; tongue; salivary gland; diaphragm; spleen; kidney; uterus; ovary; tonsil; esophagus; pituitary; thyroid gland; parathyroid gland; urethra; umbilicus; cerebrum; hippocampus; cerebellum: No significant lesions, California Sea Lion (*Zalophus californianus*), pinniped.

COMMENTS: The mother of this fetus was euthanized. The submitted tissues are well preserved and there is no evidence of infectious or toxic disease.

Thomas P. Lipscomb, DVM, DACVP
LTC, VC, USA
Chief, Division of Veterinary Pathology

F. Yvonne Schulman, DVM, DACVP
Division of Veterinary Pathology

Department of Veterinary Pathology, Building 54, Room G-117, 14th St. and Alaska Ave NW, Washington, D.C. 20306-6000
Phone: 202-782-2600 DSN: 662-2600 fax: 202-782-9150 Email: afipvet@email.afip.osd.mil

Printed on Recycled Paper

DEPARTMENT OF DEFENSE
ARMED FORCES INSTITUTE OF PATHOLOGY
WASHINGTON DC 20306-6000

REPLY TO
ATTENTION OF

August 26, 1998

2632684-3 00
ANIMAL, PINNIPEDIA SEA LION
CSL 3700 T "ALEXANDRA"
TPL/HG/mab

Dr. Frances Gulland
The Marine Mammal Center
Marin Headlands, GGNRA
Sausalito, CA 94965

AFIP DIAGNOSES:

CSL 3700 1. Brain, hippocampus: Neuronal necrosis, segmental and multifocal, extensive, California sea lion (*Zalophus californianus*), pinniped.
2. Heart, ventricles: Myofiber necrosis, multifocal, extensive, with diffuse neutrophilic myocarditis.
3. Heart, epicardium: Fibrin deposition, focally extensive, severe.
4. Eye, right: Corneal fibrosis, diffuse, severe, with corneal neovascularization, diffuse anterior synechia, and retinal detachment.
5. Lung: Pneumonia, lymphoplasmacytic and eosinophilic, multifocal, mild, with rare larval nematodes.
6. Liver: Hepatitis, portal and multifocal, granulomatous, lymphoplasmacytic, and eosinophilic, multifocal, mild, with rare parasite remnants.
7. Liver: Microfilaria, intrasinusoidal, few.
8. Spleen: Splenitis, granulomatous and eosinophilic, subcapsular, focal, mild.
9. Lymph node: Granulomas, eosinophilic, multiple, with rare intralesional larval nematodes.
10. Lung: Congestion and edema, acute, multifocal, mild.
11. Trachea: Tracheitis, lymphoplasmacytic, multifocal, mild.
12. Small intestine: Enteritis, lymphoplasmacytic, diffuse, mild.
13. Colon, submucosal artery: Arteritis, granulomatous, necrotizing, segmental, moderate.
14. Lymph node: Hyperplasia, follicular, lymphoid, moderate.
15. Adipose tissue: Atrophy, mild.
16. Salivary gland; tongue; aorta; esophagus; stomach; pancreas; adrenal glands; thyroid glands; kidney; urinary bladder; ovary; cervix; haired skin; skeletal muscle; pituitary gland: No significant lesions.

Department of Veterinary Pathology,Building 54,Room G-117,14th St. and Alaska Ave NW,Washington, D.C. 20306-6000
Phone: 202-782-2600 DSN: 662-2600 fax: 202-782-9150 Email: afipvet@email.afip.osd.mil

Printed on Recycled Paper

COMMENT: This animal was one of a number of sea lions that presented with seizures during a period when a domoic acid-producing algal bloom was present in the area. The histopathologic findings in the hippocampus are consistent with the effects of domoic acid poisoning in other species. Special stains and electron microscopic examination did not demonstrate the cause of the heart lesions. Some of the other sea lions that died during this outbreak had similar heart lesions and myocardial necrosis is associated with some other excitotoxins; thus, we suspect that the cardiac lesions are due to domoic acid poisoning. The lesions affecting the right eye were very likely the result of a penetrating traumatic injury to the cornea; this eye would have been blind. Lesions in lung, liver, spleen and lymph node were probably caused by parasitism. The remaining lesions were probably of little clinical significance.

Thomas P. Lipscomb, DVM, DACVP
LTC, VC, USA
Chief, Division of Veterinary
Pathology

Veterinary Medical Teaching Hospital
University of California, Davis

23Nov98 at 11:51am.

PATHOLOGY BIOPSY
FINAL REPORT

CLINIC NO.:
SPECIES: OTHER SMALL ANIMAL
BREED: SEA LION
SEX: M **LIFESTAGE:** JUVENILE
TAG NO.: CSL #3707 (FRANKEY)
CLINICIAN: No Doctor #
OWNER: MARINE MAMMAL CNTR ATTN: EILEEN ECONOMY
ADDRESS: Golden Gate Nat'l Rec Area Bldg 1044
Sausalito, CA 94965

PATHOLOGY NO.: 98B 1283
DATE REQUESTED: MAY 26, 1998
RESIDENT: L.J. LOWENSTINE, DVM,PhD

****

SPECIMEN: BIOPSY TISSUE **PRESERVATIVE:** FORMALIN **DATE REPORTED:** NOV 20, 1998

****

PATHOLOGIC DIAGNOSIS:

1) SEIZURES SECONDARY TO DOMOIC ACID INTOXICATION (CONFIRMED BY DETECTION IN URINE)
2) BRAIN, ANTERIOR VENTRAL HIPPOCAMPUS/RHINOENCEPHALON: ACUTE, SEVERE, DIFFUSE NEURONAL NECROSIS DENTATE GYRUS AND CA3 WITH MULTIFOCAL NEURONAL NECROSIS CA4, CA2, AND CA1, PYRIFORM CORTEX, AMYGDALA AND CLAUSTRUM (COMPATIBLE WITH DOMOIC ACID INTOXICATION)
3) BRAIN: MARKED VACUOLATION IN PYRIFORM CELL LAYERS AND STRATUM RADIATUM HIPPOCAMPUS, MAMMILARY BODIES, VENTRAL NUCLEI AND TRANSVERSE FIBERS OF PONS, INTERNAL CAPSULE, PERIVENTRICULAR AREAS OF THALAMUS, DORSOMEDIAL FASCICLES OF THE ANTERIOR CERVICAL CORD AND CAUDAL MEDULLA AND NEUROPIL IN VENTRAL RHINOENCEPHALON AND THE PITUITARY PONS NERVOSA
4) BRAIN: NONSUPPURATIVE MENINGOENCEPHALITIS WITH MILD, MULTIFOCAL GLIOSIS
5) LUNG: MILD, MULTIFOCAL, SUPPURATIVE BRONCHOPNEUMONIA
6) LUNG: SEVERE, ACUTE PASSIVE CONGESTION WITH MULTIFOCAL ATELECTASIS AND MULTIFOCAL, ACUTE HEMORRHAGE
7) ILEOCOLIC JUNCTION: MULTIFOCAL, SUPPURATIVE ILEOCOLITIS WITH CRYPT HERNIATION AND ABSCESSATION
8) COLON: ACUTE, SUPERFICIAL, FOCALLY SEVERE COLITIS WITH ATTACHING BACTERIA SUPERFICIAL LAMINA PROPRIAL FIBRIN THROMBI
9) HEART: MILD MYOCARDIUM AND EPICARDIAL EDEMA AND MINIMAL, MULTIFOCAL MYOFIBER DEGENERATION WITH MINIMAL MYOCARDITIS
10) GALLBLADDER, BILE DUCT: MILD TO MODERATE, LYMPHOCYTIC CHOLEDOCHITIS AND CHOLECYSTITIS
11) LIVER: PERICHOLANGIAL FIBROSIS
12) LIVER: MARKED PASSIVE CONGESTION WITH PERIPORTAL FATTY CHANGE
13) KIDNEYS: MILD, MULTIFOCAL, LYMPHOCYTIC INTERSTITIAL NEPHRITIS AND FOCAL, MODERATE, LYMPHOCYTIC PYELITIS (ONE RENICULUS)
14) STOMACH: MILD, MULTIFOCAL, SUPERFICIAL CONGESTION

NOV 1998
DISTRIBUTED TO CLINICIAN

AND HEMORRHAGE IN FUNDUS AND MILD, LYMPHOCYTIC GASTRITIS IN PYLORUS
15) SPLEEN, INTESTINES, AND LYMPH NODES: MARKED LYMPHOID FOLLICULAR HYPERPLASIA
16) SMALL INTESTINE: LUMINAL NEMATODE (ASCARID-LIKE)
17) COLON: TREMATODIASIS (SINGLE TREMATODE IN CRYPT)
18) TESTES: MILD SPERMATOGENESIS
19) THYMIC ATROPHY
20) TONGUE: MILD, MULTIFOCAL, LYMPHOCYTIC AND FOCAL GRANULOMATOUS GLOSSITIS
21) TONSIL: SUPPURATIVE TONSILITIS WITH CRYPT ABSCESSATION, CRYPT EPITHELIAL NECROSIS AND INTRALESIONAL BACTERIA

LINICAL ABSTRACT:

This is a California Sea Lion #3707 named Frankey. This animal is one of everal California Sea Lion with neurologic signs which have been stranded on cean Dunes in San Luis Obispo County. This animal had dilated pupils and Grand al seizures. He had a white count of 11,600 of which 13% were eosinophils. This as a sub-adult male California Sea Lion with a standard length was 151cm, lubber depth is 28mm, axillary girth is 89cm, umbilical girth is 71cm.. He was tranded at Oceano Dunes, San Luis Obispo County on 5/20/98 and admitted to the arine Mammal Center the same day. He was euthanized the following day 5/21/98 t 8:00 a.m. and a postmortem was begun the same day at 12:00 noon.

ROSS NECROPSY:

Gross necropsy findings by Dr. Frances Gulland included blood-tinged gray ucus and about 20 Anasakids in the stomach. The myocardium was pale and all hambers of the heart were engorged with blood. There was about 5cc of clear range fluid in the pericardial sac. The lungs were mildly congested. The tongue nd esophagus appeared congested. No other abnormalities were detected.

ROSS DESCRIPTION:

specimen consists of a single large tub of formalin labelled "CSL 3707 rankey" 5/21/98, in which are present multiple formalin fixed tissues including he entire right side of the brain. Other tissues include: Four pieces of liver, wo of gall bladder, one piece of kidney, two pieces of testes, the tip of the adder, two pieces of duodenum plus pancreas and three other pieces of andular tissue (? Pancreas, salivary gland, thymus). Two pieces of lung, two eces of diaphragm, five pieces of heart, two pieces of spleen, four lymph des, two pieces of thyroid, one piece of adrenal, pituitary and twelve pieces intestine tract, laryngeal tissue with tonsils and two pieces from tongue. presentative sections of each were submitted for histology.

STOPATHOLOGICAL SUMMARY:

The following tissues were examined microscopically: (T1) kidney, liver; 2) lung, thymus; (T3) heart; (T4) lymph nodes X4; (T5) amygdala; (T6) alamus, hippocampus; (T7) pons, cerebellum; (T8) pons, cerebellum, cortex; 9) C1/medulla; (T10) adrenal, thyroid, pituitary; (T11) ileocolic junction, llbladder, small intestine; (T12) tongue, esophagus, diaphragm; (T13) heart; 14) liver X4; (T15) pancreas, spleen; (T16) bile duct, tonsil; (T17) stomach, ophagus, colon; (T18) testes, mixed salivary gland, small intestine; (T19) rebral cortex, frontal lobe; (T20) pyriform lobe, rhinoencephalon.

MMENT:

The vacuolar lesions and acute ischemic necrosis in the brain are similar to that which has been seen in other animals with Domoic acid intoxication. Analysis of the urine from Frankey revealed a high concentration of Domoic acid. Heart lesions have also been seen in other animals from this unusual mortality event. Histologically, the lesions in Frankey are relatively mild and consist of edema and some evidence of myocardial fiber necrosis. In some of these small foci, there are a few inflammatory cells mostly mononuclear. In addition to the lesions presumed to be from the Domoic acid and seizures, there is also a nonsuppurative meningoencephalitis similar to that which has been seen in other sea lions in this unusual mortality event. No specific etiologic agent was identified for this lesion. The ileitis and colitis may have become clinically significant and a source of sepsis had the animal suffered. The acute bronchopneumonia may be secondary to aspiration during seizures. Other lesions were probably incidental with the marked lymphoid hyperplasia in the spleen, intestines, and lymph nodes being a reaction to the inflammatory bowel disease. The kidney lesions were undoubtedly sub-clinical and they represent past bouts of pyelonephritis or leptospirosis.

msl

Linda J. Lowenstine

L.J. LOWENSTINE, DVM, PhD

Veterinary Medical Teaching Hospital
University of California, Davis

07Oct98 at 4:37pm.

PATHOLOGY BIOPSY
FINAL REPORT

CLINIC NO.:
SPECIES: OTHER SMALL ANIMAL
BREED: SEA LION
SEX: F LIFESTAGE: ADULT
TAG NO.: CSL #3709 (DEAN)
CLINICIAN: No Doctor #
OWNER: MARINE MAMMAL CNTR ATTN: EILEEN ECONOMY
ADDRESS: Golden Gate Nat'l Rec Area Bldg 1044
Sausalito, CA 94965
COMMENT: WEIGHT: 76 KG.

PATHOLOGY NO.: 98B 1284
DATE REQUESTED: MAY 26, 1998
RESIDENT: L.J. LOWENSTINE, DVM,PhD

****

SPECIMEN: BIOPSY TISSUE PRESERVATIVE: FORMALIN DATE REPORTED: SEPT 25, 1998

****

PATHOLOGIC DIAGNOSIS:

1) SEIZURES SECONDARY TO DOMOIC ACID INTOXICATION (CLINICAL DIAGNOSIS)
2) BRAIN: MARKED LAMINAR MICROVESICULAR VACUOLATION NEUROPILE OF VENTRAL ROSTRAL HIPPOCAMPUS, STRATUM RADIATUM
3) BRAIN: MILD VACUOLATION WITHIN PYRAMIDAL CELL LAYERS OF CA1, CA3 AND CA4 ASSOCIATED WITH MULTIPLE DARK SHRUNKEN NEURONS IN CA3 AND CA4 AND RARE INDIVIDUALLY NECROTIC HYPEREOSINOPHILIC NEURONS IN CA1 OF THE HIPPOCAMPUS
4) BRAIN: LYMPHOCYTIC MENINGITIS AND CHOROIDITIS WITH RARE INTRAPARENCHYMAL PERIVASCULAR CUFFS
5) VESSELS, MULTIPLE ORGANS INCLUDING BRAIN, KIDNEY, THYROID: AMYLOIDOSIS
6) KIDNEY: MILD TO MODERATE GLOMERULAR AND VASCULAR AMYLOIDOSIS AND MILD MEMBRANOUS GLOMERULONEPHRITIS
7) KIDNEY: CHORNIC MILD LYMPHOCYTIC INTERSTITIAL NEPHRITIS
8) LUNG: PULMONARY NEMATODIASIS (PARAFILAROIDES PRESUMPTIVE)
9) LUNG: MILD MULTIFOCAL HISTIOCYTIC AND GIANT CELL PNEUMONIA ASSOCIATED WITH INTRALESIONAL FOREIGN MATERIAL
10) LUNG: MILD MULTIFOCAL LYMPHOPLASMACYTIC AND OCCASIONALLY EOSINOPHILIC INTERSTITIAL PNEUMONIA (PRESUMED PARASITIC)
11) LIVER: CHRONIC LYMPHOCYTIC PROLIFERATIVE CHOLEDOCHITIS AND CHOLECYSTITIS ASSOCIATED WITH INTRADUCTAL TREMATODES (ZALOPHATREMA HEPATICUM PRESUMPTIVE)
12) TONSILS: MARKED LYMPHOLYSIS
13) STOMACH: CHRONIC ULCERATIVE GRANULOMATOUS AND NECROTIZING PARASITIC GASTRITIS (PRESUMED ANASAKIS SP. AND CONTRACAECUM SP.)
14) SMALL INTESTINE: MILD TREMATODIASIS WITHIN CRYPTS
15) HEART: MILD INTERSTITIAL VACUOLATION (EDEMA ?) AND MINIMAL LYMPHOCYTIC MYOCARDITIS WITH MYOFIBER LIPOFUSCINOSIS
16) BODY AS A WHOLE; MULTIPLE ORGANS INCLUDING BRAIN,

OCT 1998
DISTRIBUTED
TO
CLINICIAN

ADRENALS, HEART: LIPOFUSCINOSIS
17) LYMPH NODES: MULTIFOCAL GRANULOMATOUS LYMPHADENITIS ASSOCIATED WITH REACTIVE LYMPHOID HYPERPLASIA (PRESUMED PARASITIC MIGRATION)

CLINICAL ABSTRACT:

This is one of several California Sea Lions that beached with neurologic signs. She was an aged adult female with a standard length of 159cm, axillary girth of 100cm, umbilical girth of 86cm, blubber depth of 17mm and a weight of 76kg with a somatic index score of 3/7. She stranded at Oceano Dunes in San Luis Obispo County on 5/20/98. Seizures were observed and she was admitted to the Marine Mammal Center that same day. She died at 2300 on 5/20/98 and postmortem was performed at 1300 on 5/21/98 by Dr. Francis Gulland.

GROSS DESCRIPTION:

Gross abnormalities included pale pink oral mucous membranes, worn incisors with absences of two upper incisors. There was red mucoid material in the oropharynx and the nasal mucosa was red and congested as was the mucosa over the arytenoids. Submandibular lymph node was congested and enlarged. The lungs were diffusely mildly congested with slight interstitial edema. The myocardium was pale and there was hemorrhage in the wall of the left ventricle extending 2mm from outer surface into the myocardium. All chambers of the heart were engorged. The gall bladder was distended with thick black orange bile and Zalophatrema flukes were present in the bile duct and canaliculi of liver. The spleen was contracted. The rugae of the stomach were swollen red and there was mild erosion of the rugae and two volcanic ulcers with anasakid larvae in the center. There are about 50 anasakids in the stomach. The kidneys were swollen. The renal cortices were pale tan and the left uterine wall had a thickened area about 2cm x 2cm. Multiple tissues were saved for toxin analysis, virology, etc.

HISTOPATHOLOGICAL SUMMARY:

The following tissues were examined: (T1) Heart x 2; (T2) kidney x 2; (T3) lung x 3; (T4) adrenals, pituitary and thyroid; (T5) heart; (T6) lymph node; (T7) stomach x 2, small intestine and thyroid; (T8) liver; (T10) liver and bile ducts, pancreas, tonsil, bladder; (T9) liver, bile ducts; (T11) ovary, tongue, uterus; (T12) brain, hippocampus; (T13) brain; (T14) cerebral cortex; (T15) frontal cortex and choroid plexus; (T16) cervical spinal cord.

COMMENT:

This old adult California Sea Lion was suffering from seizures and died within 24 hours of rescue by the Marine Mammal Center. There was no overt neuronal necrosis as was seen in other animals in this unusual mortality event. However, there was marked laminar vacuolation of the stratum radiatum of the hippocampus which has been a feature in the other animals. There were numerous incidental findings in this animal consistent with the worn teeth and advanced age suspected clinically.

la

Linda J. Lowenstine
L.J. LOWENSTINE, DVM, PhD

DEPARTMENT OF DEFENSE
ARMED FORCES INSTITUTE OF PATHOLOGY
WASHINGTON DC 20306-6000

REPLY TO ATTENTION OF

August 26, 1998

2632680-1 00
ANIMAL, PINNIPEDIA SEA LION
CSL 3709 T "DEAN"
TPL/HG/mab

Dr. Frances Gulland
The Marine Mammal Center
Marin Headlands, GGNRA
Sausalito, CA 984965

AFIP DIAGNOSES:

CSL 3709 1. Lymph nodes, site not specified, multiple; spleen: Necrosis, lymphoid follicles, multifocal, California sea lion (*Zalophus californianus*), pinniped.
2. Kidney: Hyalin material, glomerular, periglomerular and interstitial, multifocal, moderate.
3. Adipose tissue: Atrophy, diffuse, severe.
4. Duodenum: Duodenitis, neutrophilic, multifocal, moderate.
5. Lung: Pneumonia, lymphoplasmacytic and eosinophilic, multifocal, mild, with metastrongyle nematodes, etiology consistent with *Parafilaroides decorus*.
6. Stomach: Gastritis, ulcerative, chronic-active, focally extensive, moderate, with embedded parasite remnants, etiology consistent with *Anisakis* sp.
7. Liver: Hepatitis, granulomatous, lymphoplasmacytic and eosinophilic, multifocal, mild, with focal intralesional microfilaria.
8. Heart, ventricles: Edema, interstitial, multifocal, mild.
9. Lymph node: Lymphadenitis, granulomatous, multifocal, moderate, with intrahistiocytic anthracosilicotic pigment.
10. Esophagus; thyroid gland; salivary gland; small intestine; adrenal gland; skeletal muscle; urinary bladder: No significant lesions.

COMMENT: This sea lion had seizures and died during a disease outbreak believed to have been caused by domoic acid toxicosis. Brain was not received with these samples. The lymphoid necrosis is similar to that seen in other sea lions believed to have been affected by the toxicosis. The hyalin material in the kidney is suggestive of amyloid; after a special stain for amyloid has been examined, an addendum report will be sent to you. The atrophy of adipose tissue indicates negative energy balance. Although the cause of the duodenitis is not evident, the predominance of neutrophils suggests bacterial infection. The pulmonary, gastric and hepatic lesions are parasitic and probably of little clinical significance. The cardiac edema is probably a terminal change. The pigment accumulation in the lymph node is an incidental finding.

Thomas P. Lipscomb, DVM, DACVP
LTC, VC, USA
Chief, Division of Veterinary Pathology

Department of Veterinary Pathology, Building 54, Room G-117, 14th St. and Alaska Ave NW, Washington, D.C. 20306-6000
Phone: 202-782-2600 DSN: 662-2600 fax: 202-782-9150 Email: afipvet@email.afip.osd.mil

Printed on Recycled Paper

COLORADO VETERINARY DIAGNOSTIC LABORATORY
College of Veterinary Medicine and Biomedical Sciences
Colorado State University, Fort Collins, CO 80523
Phone 970-491-1281 Fax 970-491-0320

DL#: 978-41862
Date: 6/98

Vet/Clinic: Francis Gulland/Marine Mammal Center
Owner: Marine Mammal Center
Animal ID: CSL3721/Toe #13070 **Date Specimen Taken:** 6-3-98
Species: Zalophus californianus **Breed:** NA **Age:** A **Sex:** F

History: Found seizuring on the beach 5-21-98. Animal was brought into the rehab center and continued to seizure, was anorectic and was euthanatized on 6-3-98.

DIAGNOSIS: 1/Non-suppurative encephalomyelitis, moderate, brain.

2/Protozoan cyst, single, brain.

3/Protozoan cyst, two, myocardium.

4/Mild multifocal myocarditis, heart.

5/Pneumonia, multifocal, chronic active, lungs, associated with parasitism.

6/Gastritis, ulcerative, stomach, associated with nematodes.

7/Mild fibroplasia, corticomedullary junction, adrenal gland.

8/Rhabdomyelitis, minimal, skeletal muscle.

COMMENTS: This is somewhat of a confusing case. This adult female had clinical signs suggestive of domonic acid poisoning as with the other animals brought in during this timeframe, however, the histological lesions do not confirm this problem. The only other lesions found was the presence of protozoan cysts, one in the brain and two in the myocardium; however, the reaction around these cysts was negligible. The other findings in this animal are incidental and common in California Sea Lions. My impression is that this animal probably did suffer from some type of perhaps neural toxin from ingesting fish that may have been slightly different from domoic acid, but yet still caused convulsions and early brain edema which lead to this animal being euthanatized. However, domoic acid intoxication could not be confirmed on histopathology in this case.

GROSS NECROPSY: This is an adult female in fair body condition. The heart valves may be just slightly thickened. The right uterine horn is thickened as if this animal had a fetus a week or so ago. There are 4+ nematodes in the stomach and seven gastric ulcers. There is a small diverticulum in the mid-region of the small intestines that is suggestive of a remnant of Meckels diverticulum. Numerous gall bladder flukes are present in the bile ducts.

HISTOPATHOLOGY: 1/Olfactory stria/rhinocephalon - There is a mild degree of lymphocytic cuffing in vessels of the olfactory tracts and cortical tissue. Only an occasional hole is found within the cortex of the rhinocephalon. Several vessels within the caudate nucleus near the internal capsule are cuffed with lymphocytes but the neuropil and neurons of the caudate nucleus are within normal limits.

2/Caudate nucleus/internal capsule - At this level, the corpus callosum is relatively normal, cingulate gyrus is normal, and septal nuclei are within normal limits. The neuropil and neurons of the caudate nucleus are normal except there are numerous vessels within the caudate nucleus that have a mild to moderate degree of lymphoplasmacytic cuffing. There is also an occasional hole within the neuropil but it does not appear to be significant. There are a few holes throughout the internal capsule suggesting previous intramyelinic edema. Many of these holes do not have axons in them, suggesting perhaps there was also previous axonal degeneration.

3/Hypothalamus - Nuclei of the hypothalamus are within normal limits. Optic chiasm and optic tract are within normal limits. There is a moderate degree of gliosis and lymphoplasmacytic cuffing within the medial dorsal nucleus of the thalamus. A few holes suggesting neuronal dropout is also present within this nucleus. Mild lymphocytic cuffing is also found within the thalamic adhesion. One unusual finding is that within the dorsal medial nucleus, that the majority of the lesions are on the left side and the right side has relatively minimal lesions, so this does not appear to be a bilateral condition. There are a few holes and mild lymphocytic cuffing within the internal capsule. The putamen and globus palatus in this region are within normal limits.

4/Mid-thalamus/hypothalamus with pituitary gland stalk - The pars anterior of the pituitary gland is normal. The pituitary gland stalk pars nervosa is normal. Hypothalamic nuclei are normal.

Extensive gliosis and lymphoplasmacytic vascular cuffing are found within the thalamic adhesion, the medial dorsal nucleus and the medial central nucleus of the thalamus. There are a few holes in these nuclei but for the most part, the nuclei and neuropil is relatively normal except for right around the large cuffed vessels, especially in the central medial nucleus and the medial dorsal nucleus. There are numerous neurons in what appears to be the ventral lateral nucleus, that are undergoing early degeneration and have a lacy texture to the cytoplasm. The nuclei in this particular nucleus appears to be intact in some cases, but in other neurons, they appear to be undergoing early lysis. This may also be the anterior aspect of the ventral caudal lateral and ventral caudal medial nuclei propria struction of the thalamus. There are a few holes and early lymphocytic cuffing within the internal capsule as seen in other cases. The crus cerebrai in this region is relatively normal.

5/Thalamus at the level of the habenular nucleus - The habenular nucleus is within normal limits, however, within the nucleus of the tract of the habenulointerpeduncular nucleus there is an extensive degree of lymphocytic cuffing and gliosis. There is also lymphoplasmacytic cuffing throughout this region. Neurons in this area are within normal limits. The ventral caudal lateral and caudal ventral medial nuclei of the thalamus in this region does contain a few holes but the number of holes and evidence of intramyelinic edema is minimal. A few holes are found the crus cerebelli and within these holes, axons are missing suggesting axonal degeneration. There is one nuclear mass right adjacent to the tip of the infundibular stalk which is probably the nucleus of the periventricus arcuatus and the nucleus of premamillaris. Within these two nuclei, there is an extensive degree of vacuolation within the neuropil and mild gliosis is present throughout this area, but the neurons appear to be within normal limits. The meninges are all through this area, thus having an increased infiltration of lymphocytes and plasma cells. The amygdaloid nuclear complex is within normal limits. Section of hippocampus is characterized by a fairly normal pyramydial cell layer and stratum radiatum. But, there are several large areas of gliosis and lymphoplasmacytic cuffing within the molecular cell layer. Meninges covering the hippocampus are moderately infiltrated with lymphocytes and plasma cells. Neuronal necrosis is not present within this section of hippocampus. This section is more towards the posterior aspect or tail of the hippocampus.

Thalamus/pineal body - The corporus callosum in this region has a few holes within the axons. The choroid plexus is within normal

limits. There are a few concentric mineralized foci within the pineal body but otherwise it is within normal limits. The lateral posterior thalamic nucleus, pulvinar and optic radiations are within normal limits. Posterior commissure is normal. The anterior aspect of the substantia nigra is normal. Ventral gray matter is normal. The oculomotor nucleus is normal and ocular motor nerve is normal.

7/Thalamus/anterior hippocampus - This section of corporus colosum also contains a few holes and loss of neurons. The cingulate gyrus does contain a moderate degree of lymphoplasmacytic cuffing and gliosis. There is extensive lymphoplasmacytic infiltration within the meninges over the head of the hippocampus and within the meninges and choroid plexus in this region. This section of hippocampus is probably the CA1 area. There is an extremely mild degree of gliosis in this area, but there is no evidence of neuronal loss or neuronal necrosis. There is an extremely mild degree of edema or holes within the neuropil that appear to be probably edema within astrocytic processes. It is relatively mild, however. The central gray substance and reticular formation in this region is considered normal. However, there is extensive lymphoplasmacytic vascular cuffing than the lateral geniculate body. There is also gliosis and a few extra holes and a few neurons that have this lacy change within this area within the lateral geniculate body. The superior caniculus is within normal limits. There are at least three holes in the posterior aspect of the ocular motor nucleus but the red nucleus and substantia nigra are within normal limits. There is one sarcocyst pseudocyst to what appears to be the white tracts of the capsule of the red nucleus. This cyst is actually located between the red nucleus and the substantia nigra. This sarcocyst is of the small bradyzoite variety. There is a mild degree of inflammation including a mild lymphoplasmacytic cuffing and a few lymphocytes and plasma cells in between axons in this area. It is difficult to tell whether the parasite is causing the inflammation because this type of inflammation is present throughout most of these brain sections. There are specifically no lymphocytes or plasma cells adjacent to this protozoan cyst.

8/Hippocampus - This section contains two sections of hippocampus within the middle region of the organ. Both of these sections are similar. There is an extremely minimal gliosis within these organs. There is a moderate infiltration of lymphocytes and plasma cells within the vessels of the leptomeninges over the organs and within the choroid plexus. The number of pyramidal cells and molecular cells are within normal limits. A few

vessels within the substantia radium are cuffed with lymphocytes and plasma cells. Dentate gyrus is within normal limits. The surrounding white matter tracts and cortical tissue is also within normal limits. The second section of hippocampus is similar except that there is more lymphocytic cuffing and gliosis in this region, especially within and around the molecular layer. Neuronal necrosis is not found in this area with either the pyramidal cell layer or the molecular cell layer.

Brain stem/superior colliculus/pons - There is a mild degree of central chromolysis of the Purkinje cells. The molecular and granular layers are within normal limits. The white matter tracts in this section of cerebellum is within normal limits. The interior caniculus is within normal limits. There is a moderate degree of lymphoplasmacytic cuffing within the tegmental nucleus and an area that is compatible with the tectospinal tract. There is no evidence of neuronal necrosis in this area, but the primary lesion is lymphoplasmacytic cuffing with lymphocytes and plasma cells within the parenchyma. No evidence of malacia or necrosis was found within this area. Nerve fibers and nuclear areas of the pontine nucleus are within normal limits.

10/Cerebellum/roof nuclei - This section of cerebellum is within normal limits. There are a few vessels that are cuffed adjacent to the roof nuclei and a few holes within this region, but the number of holes and lesions are minimal.

Trigeminal ganglion/nerve - Within normal limits. However, there is a moderate accumulation of lymphocytes and plasma cells within the adventitia covering this nerve and there are several extremely small accumulations of inflammatory cells between axons.

11/Pituitary glands - The pars nervosa and pars interior are within normal limits. There are just a few capillaries within the pars nervosa that are cuffed with a few lymphocytes and plasma cells.

Spinal cord - No significant lesions (NSL).

Obex - This section is characterized by multiple small lakes or holes within the cuneate nucleus bilaterally but the dorsal vagus nucleus and the hypoglossal nucleus and olive nuclei and large white matter tracts within this region and the nucleus of the spinal tract of the trigeminal nerve with its adjacent white matter tracts are all within normal limits. Also within the

cuneate nucleus are a few capillaries that are cuffed with a few lymphocytes and plasma cells. Spinal nerves of spinal cord are within normal limits.

Small intestines - This section contains a few crypts that are just slightly dilated and contain cellular debris but this is within normal limits. There is one small focus of lymphocytes, plasma cells, and eosinophils that are present within and between the muscular layers. This small inflammatory focus is probably associated with parasitic activity.

12/Cerebrum - There is an increased number of lymphocytes and plasma cells within the meninges covering this section of cerebrum of the parietal lobe. A few vessels within the white matter tracts and cortex are also cuffed with a mild cuffing of lymphocytes and plasma cells.

13/Adrenal gland - There is a moderate degree of fibrosis at the corticomedullary junction but the adrenal cortex is relatively normal.

Ciliac ganglion - NSL. One odd finding, though in the ciliac ganglion, is a small focus of adrenal medullary cells.

Small intestines - This section has undergone moderate autolysis but is otherwise within normal limits.

14/Lung - Several sections are examined and all are similar. There are areas of consolidation characterized by infiltration of lymphocytes, plasma cells, a few neutrophils, and an occasional macrophage. This infiltration is present, both within alveolar spaces, alveolar walls, and terminal bronchioles. A moderate degree of edema is present within some of these foci. Several cross-sections of immature nematodes are found adjacent and within some of these foci. In other sections of lung, adult lungworms are also present within terminal bronchioles and alveolar ducts.

15/Thyroid gland - NSL.

Heart - For the most part, the myocardium appears to be relatively normal. There may be a few small areas where there is mild separation of myocardial fibers, but it is relatively minor. There is one small protozoan cyst in the myocardium. The protozoan cyst is of the small bradyzoite type. There are also several small focal accumulations of lymphocytes and plasma cells within the myocardium, especially near the epicardium. There is

at least one other protozoan cyst found in the heart of this animal within the second section of heart adjacent to the large coronary vessels. No inflammation is immediately surrounding these protozoan cysts.

16/Liver - There is a mild atrophy of the hepatocytes and a mild inspissation of bile within biliary canaliculi.

Spleen - The lymphoid tissue of the spleen is within normal limits. The red pulp is slightly congested but of normal cellularity.

Skeletal muscle - There are a few fibers which are swollen and have fragmentation and cleavage of the contractile sarcoplasm. Occasionally, there are a few lymphocytes and neutrophils within these areas of acute rhabdomyolysis. These lesions may be associated with either capture or the continual problem with convulsions.

17/Bile ducts - This section of bile duct is markedly infiltrated with lymphocytes and plasma cells, and the mucosal layer is markedly disrupted. A cross-section of a large fluke is present within the lumen. There is a mild degree of fibroplasia around this large bile duct.

Hepatic lymph node - The lymphoid tissue is relatively active and sinusoids are relatively clean except for a moderate accumulation of black fluke pigment.

Thymus - The lymphoid tissue of the thymus is totally depleted.

Pancreas - NSL.

Esophagus - There is a small accumulation of lymphocytes and plasma cells underneath the squamous epithelial layer but otherwise this is considered to be within normal limits.

18/Mesenteric lymph nodes - These lymph nodes are active and within normal limits. There are a few small focal areas of what appear to be scarring in these nodes and this is probably from previous small granulomas or abscesses associated with parasites. This is an incidental finding and is relatively common.

Peripheral lymph node - This lymph node is also active but within normal limits. There appears to be though a depletion of small lymphocytes and follicles but otherwise, no other lesions are observed.

19/Kidneys - The kidneys are within normal limits.

Urinary bladder - NSL.

Stomach - This section contains a portion of a large ulcer. This ulcer does penetrate deep into the submucosa and is surrounded by an extensive infiltration of lymphocytes, plasma cells, macrophages, and a few neutrophils. Several cross-sections of nematodes are found within this gastric ulcer.

20/Ovary/uterus - One section of ovary contains a large degenerating corporus luteum. Section of adrenal gland contains a small degree of fibroplasia at the corticomedullary junction. One section of uterus is inactive, the other section does contain edema and hemorrhage within the endometrium, and an extensive infiltration of lymphocytes and plasma cells throughout. This uterus is involuting and the animal probably had a fetus several weeks prior.

Terry Spraker, DVM/PhD

Typed: 6-19-98 ml
6-22-98 ml

Veterinary Medical Teaching Hospital
University of California, Davis

04Dec98 at 2:59pm.

PATHOLOGY BIOPSY
FINAL REPORT

CLINIC NO.:
SPECIES: OTHER SMALL ANIMAL
BREED: SEA LION
SEX: U
TAG NO.: CSL #3724 (THREE)
CLINICIAN: No Doctor #
OWNER: MARINE MAMMAL CNTR ATTN: EILEEN ECONOMY
ADDRESS: Golden Gate Nat'l Rec Area Bldg 1044
Sausalito, CA 94965

PATHOLOGY NO.: 98B 1285
DATE REQUESTED: MAY 26, 1998
RESIDENT: P. SILVAGNI, DVM
PATHOLOGIST: L.J. LOWENSTINE, DVM,Ph

****

SPECIMEN: BIOPSY TISSUE **PRESERVATIVE:** FORMALIN **DATE REPORTED:** DEC 4, 1998

****

PATHOLOGIC DIAGNOSIS:

1) BRAIN, DENTATE GYRUS: SEVERE, ACUTE, DIFFUSE ISCHEMIC NECROSIS
2) BRAIN, HIPPOCAMPUS: MARKED PYKNOSIS AND NECROSIS OF NEURONS; CA4 GREATER THAN CA3 GREATER THAN CA2, CA1
3) BRAIN, HIPPOCAMPUS: SEVERE, DIFFUSE MICROVESICULATION OF THE STRATUM RADIATUM
4) BRAIN, PIRIFORM LOBE: MODERATE, ACUTE, MULTIFOCAL ISCHEMIC NEURONAL NECROSIS
5) BRAIN: MILD, CHRONIC, LYMPHOCYTIC AND PLASMACYTIC MENINGITIS AND CHOROIDITIS
6) LUNGS: MINIMAL NEMATODIASIS
7) LUNG: MODERATE CONGESTION AND HEMORRHAGE
8) BLOOD VESSELS: MILD MICROFILAREMIA
9) COLON: MILD CRYPT ECTASIA AND FILAMENTOUS BACTERIAL OVERGROWTH
10) STOMACH: SEVERE, FOCAL ULCERATIVE GASTRITIS, PARASITIC WITH INTRALESIONAL CLOSTRIDIUM
11) LYMPH NODES: LYMPHOCYTOLYSIS WITH LYMPHOID DEPLETION AND SYNCYTIAL CELL FORMATION

CLINICAL ABSTRACT:

This is a California Sea Lion #3724 named Three. This adult female California Sea Lion was found stranded at Oceano Dunes in San Luis Obispo Count on 5/21/98 and was admitted to the Marine Mammal Center on the same day. She died on 5/22/98 at 6:00 a.m. and the postmortem was performed the following day at 12:00 noon. This was a 99.5kg animal with a standard length of 174cm, blubbe depth is 21mm, axillary girth is 111cm, and umbilical girth is 111cm. Her somatic index is 5 out of 7. Clinically she had had seizures and was treated with penicillin.

GROSS NECROPSY:

Gross necropsy was performed by Dan Fletcher revealed the following abnormalities. All lymph nodes to be hemorrhage and some with multifocal necrosis. She had a full term fetus with foci of placental necrosis. The kidney had surface and severe loss of vernacular differentiation. The myocardium was very pale. The adrenal medulla was very pale and the cortex was striated. The lungs were dark purple and there was red foam in the trachea and bronchi. Pinpoint ulcers were present on the hard palate. Her fetus weighed 10kg and had a 77cm standard length, an axillary girth of 48cm, umbilical girth of 50cm. Fetal tissues were labelled "3724F" and were not submitted along with the femal

FEB 1999
DISTRIBUTED
TO
CLINICIAN

issues.

GROSS DESCRIPTION:

The specimen consists of a single tub of formalin with multiple pieces of issue including the brain minus portions of the left hemisphere and left erebellum. 45 other pieces of tissue from visceral organs are submitted ecognizable as portions of G.I. tract, respiratory, cardiac, urogenital tracts.

ISTOPATHOLOGICAL SUMMARY:

The following tissues were examined microscopically: (T1) diencephalon; T2) cortex; (T3) lung; (T4) cortex, hippocampus; (T5) spinal cord, pineal land; (T6) lymph node, kidney, liver, thymus; (T7) hippocampus, dentate gyrus; T8) brain, cortex; (T9) brain, medulla, cerebellum; (T10) palatine tonsil, lacenta; (T11) bladder, small intestine, cord, stomach; (T12) spleen, lymph ode, ovary; (T13) mammary gland, urethra, small intestine; (T14) heart, keletal muscle; (T15) tongue, adrenal, pituitary, thyroid; (T16) lymph node, ammary gland, spleen, diaphragm, skeletal muscle; (T17) heart, skeletal muscle.

OMMENT:

This sea lion had severe ischemic necrosis of the pyramidal cells of the entate gyrus. Within the hippocampal sectors, the pyramidal cells vary from yknotic to necrotic. In addition, there was severe vesiculation of the stratum adiatum of the hippocampus. These lesions are consistent with a excitotoxic amage (domoic acid, presumptive). Some of the neuronal necrosis may also be econdary to seizure induced hypoxia. However, the most severely affected cells here the pyramidal cells of the dentate gyrus which are relatively hypoxia esistant. The meningitis and choroiditis were chronic incidental lesions. The ther lesions were incidental and likely of little or no clinical significance.

a

P. SILVAGNI, DVM

Veterinary Medical Teaching Hospital
University of California, Davis

23Nov98 at 11:36am

PATHOLOGY BIOPSY
FINAL REPORT

CLINIC NO.:
SPECIES: OTHER SMALL ANIMAL
BREED: SEA LION
SEX: F **LIFESTAGE:** ADULT
TAG NO.: CSL #3725 (TWO)
CLINICIAN: No Doctor #
OWNER: MARINE MAMMAL CNTR ATTN: EILEEN ECONOMY
ADDRESS: Golden Gate Nat'l Rec Area Bldg 1044
Sausalito, CA 94965
COMMENT: WEIGHT: 93 KG.

PATHOLOGY NO.: 98B 1290
DATE REQUESTED: MAY 26, 1998
RESIDENT: L.J. LOWENSTINE, DVM,PhD

****

SPECIMEN: BIOPSY TISSUE **PRESERVATIVE:** FORMALIN **DATE REPORTED:** NOV 23, 1998

****

PATHOLOGIC DIAGNOSIS:

1) SEIZURES SECONDARY TO DOMOIC ACID INTOXICATION (CLINICAL DIAGNOSIS)
2) BRAIN: MILD VACUOLATION (MICROVESICULAR) NEUROPIL OF THE AMYGDALA
3) BRAIN (MEDULLA): MARKED SYMMETRICAL VACUOLATION C DORSAL NUCLEI (DORSAL MOTOR NUCLEUS OF VAGUS OR CUNEATUS, PRESUMPTIVE)
4) BRAIN: MENINGEAL HYPERPLASIA AND MILD, LYMPHOCYTI MENINGITIS AND CHOROIDITIS
5) LUNG: SEVERE, ACUTE CONGESTION WITH PATCHY ATELECTASIS AND MILD, ACUTE HEMORRHAGE
6) HEART: ACUTE MYOFIBER DEGENERATION WITH CONTRACTION BAND FORMATION
7) LUNG: MILD, MULTIFOCAL, ACUTE TO SUBACUTE, INTERSTITIAL PNEUMONIA WITH OCCASIONAL LARVAL NEMATODES (FILARID-TYPE LARVA COMPATIBLE WITH METASTRONGYLE)
8) GRAVID UTERUS (GROSS DIAGNOSIS) WITH MILD, MULTIFOCAL, ACUTE PLACENTAL NECROSIS
9) KIDNEYS: MARKED CONGESTION AND FOCALLY EXTENSIVE, ACUTE HEMORRHAGE
10) STOMACH: MILD, MULTIFOCAL, ACUTE, SUPERFICIAL HEMORRHAGE
11) MAMMARY GLAND: MILD, CHRONIC, LYMPHOCYTIC MASTITIS
12) LIVER: DIFFUSE CONGESTION
13) LIVER: MILD, MULTIFOCAL, NODULAR HYPERPLASIA WITH FATTY CHANGE
14) BLOOD VESSELS: MICROFILAREMIA
15) TONGUE: MILD LYMPHOCYTIC GLOSSITIS
16) TRACHEA: MILD LYMPHOCYTIC TRACHEITIS
17) TONSILS: UNILATERAL SUPPURATIVE TONSILITIS AND UNILATERAL TONSILLAR CYST

CLINICAL ABSTRACT:

This is a California Sea Lion #3725 named Two. This adult female Californi Sea Lion was found stranded at Post Four on Oceano Dunes in San Luis Obispo County on 5/21/98 and was admitted to the Marine Mammal Center on the same day. She died on 5/22/98 overnight and was examined the following day 5/23/98 @ 3:00 p.m.. She had a standard length of 167cm, blubber depth is 22mm, axillary girt is 110cm, umbilical girth is 118cm, and a weight of 98kg. Her somatic index was

NOV 1998
DISTRIBUTED
TO

6 out of 7. Clinical diagnoses included seizures, unresponsive to valium.

GROSS NECROPSY:

Gross necropsy was performed by Dr. Frances Gulland and the following abnormalities were noted. She had 1mm diameter ulcers over the hard palate and was pregnant with an 8kg male fetus with a 70cm standard length, 41cm axillary girth and 43cm umbilical girth. The fetus was estimated to be at term. The females masseter muscles and myocardium were pale. The kidneys were swollen and hemorrhagic on cut surface. There was blood tinged foam in the trachea and bronchi, and mild congestion of lungs. Multiple volcano ulcers were present in the stomach and all lymph nodes appeared congested. Fetal tissue was labelled "3725F".

GROSS DESCRIPTION:

Fetal tissues were not received. The specimen consists of the brain missing most of the left cerebrum and part of the left cerebellum. There are seven pieces of digestive tract, five pieces of lung, six pieces of heart, a piece of kidney, two pieces of liver, a piece of spleen, four pieces of muscle, gall bladder, great vessel, three lymph nodes, two ovaries, a piece of tongue, three pieces of glandular tissue, pieces of adrenal and thyroid and several other unidentifiable bits of tissue. Portions of each were submitted for histology. All tissues appear slightly autolyzed.

HISTOPATHOLOGICAL SUMMARY:

The following tissues were examined microscopically: (T1) muscle, lymph node, liver, kidney, pituitary; (T2) ventral brain, hippocampus, pyriform lobe; (T3) thalamus, hypothalamus; (T4) medulla, C1; (T5) brain, thalamus, ventral frontal lobe; (T6) lungs; (T7) cerebellum, pons; (T8) cerebellum; (T9) muscle, salivary gland, lymph node, kidney; (T10) spleen, placenta, lymph node; (T11) muscle X2, pancreas; (T12) heart; (T13) colon, small intestine, stomach; (T14) esophagus, mammary gland, liver, tongue; (T15) tonsil, ovary; (T16) midbrain; (T17) tonsils, adrenals, lymph nodes, ovary.

COMMENT:

All tissues are mildly to moderately autolyzed which compromises interpretation of vacuolar changes in the brain. In the one section of hippocampus examined, there is no evidence of neuronal necrosis and minimal vacuolation of dentate gyrus and hippocampal sectors. There is, however, microvesicular vacuolation of the neuropil in the amygdala which is similar to that seen in other sea lions with better brain preservation and more significant lesions. Similar to other sea lions dying in the early stages of this unusual mortality event there is myocardial degeneration. This animal is notable for the number of contraction bands present within myofibers. No lesions were seen in the masseter muscles to account for the pallor observed grossly and therefore, the pallor is thought to be due to muscle contraction causing expression of blood from the tissues. Congestion and hemorrhage seen throughout the body may be secondary to seizures. Other lesions are incidental.

msl

Linda J. Lowenstine

L.J. LOWENSTINE, DVM,PhD

COLORADO VETERINARY DIAGNOSTIC LABORATORY
College of Veterinary Medicine and Biomedical Sciences
Colorado State University, Fort Collins, CO 80523
Phone 970-491-1281
Fax 970-491-0320

DL#: 978-39393
Date:

Vet/Clinic: Francis Gulland
Owner: The Marine Mammal Center
Animal ID: CSL3726 **Date Specimen Taken:**
Species: Z. californias **Breed:** **Age:** Adult **Sex:** F

History: This is an adult female California sea lion number CSL 3726, tag number 13021. This animal was found seizuring on 5/21/98 and brought into the marine mammal center and was euthanized on 6/2/98 because it had not improved. This animal had a damoic acid level of 2.4 micrograms per ml in the urine.

DIAGNOSIS:

1. Non-suppurative lymphoplasmacytic encephalopathy especially of the amygdaloid nuclear complex, thalamus, hippocampus with neuronal loss, brain.
2. Lymphoid atrophy, moderate, tonsil.
3. Bile duct hyperplasia with fibrosis, liver, probably associated with liver flukes.
4. Pneumonia, multifocal, mild to moderate lung associated with heavy infestation of parafilaroides.
5. Interstitial nephritis, mild to moderate, chronic cortex, kidney.

REMARKS: The lesions in this animal especially the neuronal necrosis and edema with malacia are probably the result or healing phase of this acute neuronal necrosis found in these California sea lions that died within a day or so after arrival at the marine mammal center. The lesions that are observed in these animals are believed to be the resolution of the earlier lesions.

HISTOPATHOLOGY: Slide 1: Rhinencephalon, olfactory stria and rhinencephalon with adjacent cortex: The olfactory stria and olfactory nuclei have numerous vessels that are cuffed with lymphocytes. There is one large area of malacia within the posterior aspect of the olfactory nuclei that is filled with large gitter cells. Many of the vessels in this area are cuffed with lymphocytes. The adjacent olfactory cortex has numerous holes within the cortex. These holes appear to be markedly swollen astrocytes. Some of the neurons have large vacuoles

around the edges of them also suggesting large or extensive swelling of astrocytes in these regions. The meningeal vessels in this region are also slightly cuffed with a thin cuff of lymphocytes. The caudate nucleus is unremarkable in this case. Numerous areas of gliosis are also found within the olfactory cortex.

Slide 2: Hypothalamus: This section contains a posterior aspect of the caudate nucleus which is relatively normal. The internal capsule does contain an extremely small degree of edema. There is extensive lymphocytic cuffing of vessels of the amygdaloid nuclear complex. Extensive gliosis is present throughout this region. Neurophagia is occasionally observed throughout this area. The edema and acute neuronal necrosis is not present in this section but a few eosinophilic globs, which are probably dead neurons, are still observable. The corpus callosum within normal limits but meningeal vessels between the corpus callosum and the cingulate gyrus are markedly cuffed by lymphocytes. The medial dorsal nucleus of the thalamus does contain vessels that are cuffed with lymphocytes and a slight degree of gliosis throughout and several glial nodules and several neurons that are surrounded by lymphocytes and probably mild neuronal phagia. The overall lesions in this nucleus is considered moderate. There is a small amount of nuclear dropout throughout the thalamus that is especially prominent in the areas where there is extensive lymphoid cuffing.

Slide 3: Level of the thalamus and the pituitary gland stock: There is a moderate degree of lymphocytic cuffing within the nuclei of the hypothalamus and thalamus especially within the medial dorsal nucleus of the thalamus. There is extensive lymphoid cuffing and gliosis within the amygdaloid nuclear complex. Section of pituitary gland attached to the brain at the hypothalamus appears to be relatively normal. Both pars nervosa and the adenohypothesis is present for examination. There is extensive lymphocytic cuffing within the hypothalamus and mild gliosis throughout this region. There are some areas in which edema can be found within the VR spaces especially of some of the larger vessels. Scattered holes are found throughout the remaining thalamus suggestive of neuronal dropout. Occasionally axons throughout the thalamus have mild intramyelinic edema but the majority of the edema has dissipated within this section of thalamus. The medial dorsal nucleus of the thalamus is characterized by extensive lymphoid cuffing and gliosis. The internal capsule is relatively normal except for just a few axons that have intramyelinic edema but the edema is much reduced compared to the previous acute cases. There is extensive lymphoplasmacytic cuffing and gliosis and early malacia within the amygdaloid nuclear complex. There appears to be a marked reduced number of neurons and an occasional eosinophilic neuron can still be found. Neuronal phagia is present within this

section. In some areas there is an extensive degree of nuclear cellular debris in areas of malacia. These areas of malacia or necrosis are surrounded by an extensive accumulation of glial cells, lymphocytes, and plasma cells. An occasional gitter cell can be found within these areas of malacia. Vessels of the meninges over the amygdaloid complex are surrounded by lymphocytes and plasma cells.

Slide 4: This section is of thalamus at the level of mamillary body. In this slide there is extensive lymphocytic cuffing and gliosis in the medial dorsal nucleus of the thalamus and lymphocytic cuffing also within the caudal hypothalamic nuclei. Cuffing is also present within the mamillary bodies. The remaining thalamus has mild cuffing with mild spongy texture to the neurons. There is also mild to moderate gliosis within the anterior aspect of the ventral caudal lateral and ventral caudal medial nuclei of the thalamus. Many of these nuclei appear to be degenerating. The internal capsule in this area does contain a mild degree of intramyelinic edema. There is a mild gliosis within the globus palates but there is extensive lymphocytic cuffing gliosis and malacia within the adjacent amygdaloid nuclear complex. In some areas the degree of inflammation is overwhelming. Necrotic neurons with a marked eosinophilic to the cytoplasm can be found within this area. There is also a relatively large area of inflammation within the clostrum. Necrosis and malacia with gitter cell accumulation is also found within the amygdaloid complex. In some areas neutrophils can also be found within the areas of malacia. There still appears to be edema within this area of severe inflammation. Organisms or inclusion bodies are not found in these areas of extensive inflammation.

Slide 5: Thalamus at the level of the habenular nucleus: Lymphocytic cuffing is found within the habenular nucleus and within the nuclei surrounding the habenular nucleus. Especially in the medial dorsal nucleus of the thalamus which is just lateral to the habenular nucleus. There is diffuse gliosis throughout the remaining thalamus in this region. Mild gliosis is also found within the habenula mammary tract. The central medial nucleus of the thalamus appears to be relatively normal except for the increased gliosis. Small section of amygdaloid nuclear complex is present on this slide and it is similar to the remaining sections including extensive malacia with gliosis and extensive lymphoplasmacytic cuffing with the malacia and necrotic neurons. Neuronal phagia is occasionally found in these sections. Some of the neurons within this region are markedly swollen especially within the nucleus. These neurons are probably still undergoing phases of degeneration and will eventually die.

Slide 6: Cerebrum at the level of the parietal lobe: There is extensive lymphocytic cuffing within the choroid plexus in this region. There is a slightly increased number of what appear to be astrocytes or mild gliosis throughout the area but it is extremely mild and the mild gliosis is more prominent in the deeper cortical layers. Neurons for the most part are within relatively normal limits. There is an extremely mild increased infiltration of lymphocytes within the leptomeninges. A few holes are present throughout the matter perhaps the residuum of the intramyelinic edema of the white matter found in the more acute cases.

Slide 7: Brain stem at the level of pons with cerebellum: For the most part the molecular and granular cell layers are normal. It appears that many of the Purkinje cells are still present but many of them are characterized by central chromolysis. There are a few extra holes in the white matter tracts suggesting perhaps early intramyelinic edema but these areas have now resolved. Superior cuniculus in this region is considered to be within normal limits. The central gray matter is also normal. In area that is probably the interpeduncular nucleus is characterized by a moderate degree of lymphocytic cuffing and mild gliosis. There are a few extra holes in this area probably the result of previous neural edema. There is also gliosis within this nucleus. Many of the vessels in this section of brain and in the other areas of brain in which are surrounded by lymphocytes and plasma cells, the endothelium of these vessels are markedly hyperplastic. There is one vessel in this region that has at least three small basophilic structures within endothelial cells. It is difficult to tell whether these are actually small artifacts or perhaps protozoa. The pontine nuclear area does contain a few extra holes throughout but overall is relatively normal.

Slide 8: Cerebellum with roof nuclei: The cerebellar folia are similar to what has previously been described. There are a few extra holes and mild gliosis within the roof nuclei and it seems like many of the neurons have undergone central chromolysis. The holes appear to be areas of nuclear dropout.

Slide 9: Cerebellar folia and obex: This section of cerebellum is similar to the other ones especially in the presence of Purkinje cells that appear to be undergoing central chromatolysis. This may be associated with the continual problem with convulsions. Otherwise the molecular and granular layers are normal. The white matter tracts within this region are also relatively normal. In this section of obex there is extensive degree of lymphocytic cuffing of what appears to be edema of the neuropil and a small nucleus just dorsal and slightly anterior and medial to the dorsal nucleus of the vagus. This may be the

commissuralis nucleus. There are also several lakes of edema in the medial aspect of what is considered to be the medial cuneate nucleus. The remaining nuclei in this region are within normal limits.

Slides 10 and 11: These slides are both of hippocampus. There is extensive lymphoplasmacytic cuffing of vessels and gliosis with malacia and neuronal loss within the amygdaloid nuclear complex. This change is also present within the hippocampus and dentate gyrus with malacia. Numerous neuronal necrosis are present throughout this region. One unusual finding in this area is there is a mild infiltration of eosinophils. This is first time that eosinophils have been found within the brain parenchyma. There is also areas of necrosis and malacia within the hippocampus. The lateral geniculate does have a mild degree of edema within it.

Slide 13: Lung: This section of lung contains multiple areas of inflammation and numerous cross sections of parasites. Most of the parasites are adults. There are also several areas in which degenerated parasites are found and there is extensive inflammation around the dead parasites.

Slide 14: Heart: There are a few small areas of myocardial degeneration and early interstitial edema. There is also areas of what appears to be early myocardial fibrosis. The large coronary vessels and valves on these sections are within normal limits.

Slide 15: Lymph node: This is probably a mesenteric node. This node is relatively active and within normal limits.

Adrenal lymph node: This lymph node is normal.

Celiac ganglion: No significant lesions.

Adrenal gland: A few holes are found in the zona glomerulosa but otherwise the adrenal gland is within normal limits.

Pancreas: No significant lesions.

Slide 16: Kidney: There are multifocal areas of lymphoplasmacytic infiltration within the kidneys. These lesions are primarily within the cortex and around some of the medium to larger vessels.

Urinary bladder: This section is within normal limits.

Skeletal muscle: No significant lesions.

Slide 12: Thyroid gland: There are several large cysts in the thyroid gland but otherwise the gland appears to be within normal limits.

Tonsil: The lymphoid tissue of the tonsil is relatively depleted and small and the overall amount of tissue appears to be atrophied.

Submandibular salivary gland: No significant lesions.

Pancreas: No significant lesions.

Spinal cord: There is a mild degree of gliosis around the central canal and an occasional axon that has degenerated and appears to have swollen myelinic sheath. A few of the vessels within the meninges are slightly cuffed but the spinal nervès are relatively normal.

Slides 13, 14 and 15:

Slide 16: This section is of primary bile ducts. There is a mild degree of fibrosis and moderate infiltration of lymphocytes and plasma cells both within the lamina propria and submucosal areas of these ducts. Some of these ducts also have large dilated crypts. All of these lesions are most likely associated with the presence of flukes. Cross sections of flukes are not present on this particular slide.

Liver: This section of liver is relatively normal. Several of the bile ducts in this area are slightly dilated and filled with bile and are surrounded by lymphocytes again associated with parasitism.

Slide 17: Small intestines: Multiple sections of small intestines are examined and these are all within normal limits. Myentery plexus are also normal.

Pancreas: No significant lesions. There is a mild degree of fibroplasia around some of the ducts and a mild infiltration of lymphocytes. This is probably associated with the hepatic duct flukes.

Large intestines: No significant lesions.

Slide 18: Sublumbar lymph node and peripheral lymph node: Both of these nodes are within normal limits. The sublumbar lymph node does contain a small amount of hemorrhage and edema within the sinusoids.

Slide 19: Stomach: This section of stomach is of a large volcanic ulcer. This ulcerated area does go down to the superficial layer of the submucosa. This ulcerated area is surrounded by an extensive infiltration of lymphocytes, plasma cells with an occasional macrophage and neutrophil. However, the predominate cell is lymphocytes and plasma cells. There are also a few pieces of degenerated cuticle within this area and these areas are also surrounded by lymphocytes, plasma cells and macrophages. Numerous cross sections of parasites are present within this ulcerated area.

Slide 20: Ovary: One section of ovary does contain a large corpus luteum that appears be undergoing early degeneration. The other section of ovary contains corpus albecans. Two sections of uterus are present. One is characterized by extensive edema of the lamina propria and hemorrhage. This is probably an old attachment site for the placenta. Some of the crypts are dilated and filled with cellular debris. The other section of uterus is from the other horn and is contracted, inactive and normal.

Slide 21: Eyes: Two sections of eyes are examined, slides A and B. Slide A is of retina unfortunately most of the retina on this slide fell off the slide and was not present for examination. The section of the ciliary body and cornea are examined from slide B. These sections are relatively normal. A small section of retina is present on these slides and these sections of retina are within normal limits. A cross section of optic nerve is present and is also within normal limits.

Terry R. Spraker/DVM, PhD

Typed: 6/19/98 lm

COLORADO VETERINARY DIAGNOSTIC LABORATORY
College of Veterinary Medicine and Biomedical Sciences
Colorado State University, Fort Collins, CO 80523
Phone 970-491-1281
Fax 970-491-0320

DL#: 978-39392
Date:

Vet/Clinic: Francis Gulland
Owner: The Marine Mammal Center
Animal ID: Andromeda CSL3729 **Date Specimen Taken:**
Species: Z. californias **Breed:** **Age:** **Sex:**

History: This is a California sea lion number CSL3729 name is Andromeda, tag number 13193. This animal was found stranded on 5/22/98 admitted and then had convulsions and progressively went down hill and was euthanized on 6/1/98. The primary gross lesions it he animal is in fair body condition, flukes are present in the bile duct with severe bile duct hyperplasia. A few acanthocephetes are found in the small intestines, tapeworms are found in the ileum and cecum. Several large plaques of fibrin are found on the surface of the epicardium of the left ventricle. A small amount of fibrin is present in the left eye, subcutaneous edema is present over the chest.

DIAGNOSIS:

1. Non-suppurative leptomeningitis, diffuse characterized by lymphocytic cuffing of vessels within the brain and within the meninges, neuronal necrosis with dropout, severe hypothalamic nuclei and amygdala with neuropil edema, cuneate nucleus.
2. Myocardial fibrosis with edema, mild, multifocal heart.
3. Pneumonia, mild, multifocal, chronic active lungs associated with parasitism.
4. Interstitial nephritis, mild, multifocal cortex kidney.
5. Foci compatible with neoplastic cells within the lymphatics, urinary bladder.

REMARKS: This animal does show healing of the brain but also has extensive lymphocytic and plasmacytic cuffing of vessels of the brain both within the brain itself and within the leptomeningeal vessels. There is extensive neuronal dropout and necrotic neurons within the hippocampus and a few within the cerebral cortex and amygdaloid body. These are the primary lesions in the acute cases. A degree of neuronal edema and intramyelinic edema is present but these two phenomena's appear to be dissipated or have been resolved leaving the necrotic and dropout neurons. There is extensive gliosis and lymphocytic cuffing throughout the

brain in this animal. These are all reparative changes in the brain.

HISTOPATHOLOGY: Slide 1 is olfactory bulb/rhinencephalon, cortex. There is an extremely mild degree of edema within the olfactory nuclei and there is a mild accumulation of lymphoid cells within this region. Within the meninges covering the olfactory region and within the meninges over the frontal lobe there are an increased number of lymphocytes and plasma cells. There is an extremely mild degree of edema in a few necrotic neurons within the cortex of the frontal lobe. This is primarily within the deeper cortical lamellar regions. There is also a mild degree of lymphocytic cuffing around vessels of the cortex and a few areas of gliosis. The edema in some areas is quite extensive in this section of deep cortical lamellar tissues of the cortex.

Slide 2: Cross section caudate nucleus: Neovascularization and prominent capillaries with prominent endothelial cells with diffuse gliosis within a small segment of cingulate gyrus. Increased lymphocytes are also present within the meninges in this region. Corpus callosum does have a few axons that have undergone intramyelinic edema but it is not very severe. A few vessels within the caudate nucleus are surrounded by lymphocytes. A few of the vessels within the internal capsule also are cuffed with lymphocytes. A small section of globus palates is within normal limits except for a few vessels that have increased numbers of lymphoid cells. The olfactory nuclei are within normal limits.

Slide 3: Caudate nucleus, anterior commissure/hypothalamus: This section of cingulate gyrus is similar to what has previously been described. Corpus callosum in this area is within normal limits except for a few vessels that are cuffed with lymphocytes. A few axons appear to be edematous. Septal nuclei are normal. Anterior commissure is normal. Hypothalamic nuclei are normal. Olfactory tracts are normal. Pituitary stock and the anterior pituitary gland are normal. A few holes are found within the internal capsule but they are within normal limits. A few vessels are cuffed within the caudate nucleus.

Slide 4: Thalamus with amygdaloid nuclear complex: There is extensive cuffing of vessels throughout the amygdaloid nuclear complex. There is also moderate increased cellularity probably gliosis through this entire area. There are many eosinophilic blobs in this area that are degenerated or necrotic neurons. Neuronal phagia is not a prominent feature in this area. There are areas of gliosis within the amygdaloid area. The internal capsule in this region does show evidence of intramyelinic edema and there appears to be an increased number of small cells in

this region. These cells probably are lymphocytes. Many of the neurons, at least a portion of the neurons of the thalamus probably the inner rostral nucleus contain neurons that have edematous or lacy texture to the cytoplasm. Also within this nucleus there are a group of vessels that are cuffed by lymphocytes. There are also holes scattered throughout this nucleus and an occasional eosinophilic blob or an eosinophilic neuron that appears to be undergoing degeneration. Nuclei of the thalamic adhesion are normal.

Slide 5: Thalamus: This section is similar to slide 4. Similar lesions are found in the cingulate gyrus and minimal lesions are found within the corpus callosum. The fornices of the hippocampus are normal. A few areas of lymphocytic infiltration are present within the choroid plexus. The tail end of the caudate nucleus is normal. Numerous vessels throughout the thalamus especially in the medial dorsal nucleus of the thalamus and in the ventral rostral nucleus of the thalamus. In some areas of the thalamic adhesion area show evidence of gliosis with lymphocytic perivascular cuffing. The medial dorsal nucleus of the thalamus is the most severely affected in this slide. Necrotic neurons are characterized by eosinophilic areas and occasionally surrounded by a few glial cells. Mamillary body in this region is normal. Optic nerve in this region is considered to be normal. The amygdaloid in this region is similar to the one just described where there is a moderate amount of perivascular cuffing within the meninges and within vessels and there is a diffuse gliosis throughout this region. For the most part the neurons look fairly good in this particular section. There are two small plaques of eosinophilic fibrillar material located on the surface of the hapendima of the lateral ventricle. This may be small plaque of fibrin.

Slide 6: Slide 6 is relatively similar to slide 5. Lesions are present within the amygdaloid area and within the medial dorsal nucleus of the thalamus. Several vessels within the ventral caudal lateral and ventral caudal medial nuclei of the thalamus are cuffed with lymphocytes and there is a mild gliosis throughout this area but the neurons in this area appear to be relatively healthy.

Slide 7: Hippocampus and amygdaloid body: There is a mild gliosis within this section of hippocampus but the pyramidal and molecular cellular layer in this region is relatively normal. The dentate gyrus is also normal. A few vessels within the white matter of this section of cerebrum are cuffed with lymphocytes and there is an extremely mild gliosis within the cortex in this region but the neurons appear relatively healthy.

Slide 8: This section is of hippocampus, probably of the C-4 or posterior half area. The fornices in this area are relatively

normal. The tail of the hippocampus is characterized by extensive lymphocytic cuffing of vessels throughout. There is an extensive loss of neurons within the pyramidal cell layer and within the molecular cell layer. There is severe gliosis throughout all layers including the pyramidal cell layer, the stratum radiatum and the molecular cell layer and around the dentate gyrus. Within the pyramidal cell layer there is numerous eosinophilic tears that are most likely degenerated neurons and there are also holes in this area suggesting neuronal dropout. Neuronal phagia is not a prominent feature even though glial cells are present diffusely throughout these regions. The lateral geniculate body in this region does contain a few vessels with an extremely mild increase of lymphocytes within the adventitial tissues and there are lymphocytes within the leptomeninges covering the brain stem in this region and under the fornices of the hippocampus.

Brain stem/superior colliculus: This section of pineal body is within normal limits. Corpus callosum contains a few axons that are slightly edematous but otherwise within normal limits. A few vessels within the cingulate gyrus are cuffed with lymphocytes. A few vessels within the superior cuniculus are cuffed and a few vessels just lateral to the gray matter are cuffed but otherwise this section is relatively normal. The oculomotor nucleus in this area is normal.

Brain stem/pons: The tegmental nuclear area is normal. The pontine nuclear area and pontine fibers are all within normal limits. This section of cerebellum is also normal.

Slide 11: Cerebellum with roof nuclei and brain stem at the level of the dorsal vagus hypoglossal and caudate nucleus: The cerebellum in this region is within normal limits. The roof nuclei in this area also appear to be relatively clean at this time. The hypoglossal and dorsal nucleus of the vagus and nucleus of the spinal tract of the trigeminal nerve and olivary nuclei are all relatively normal. However, there are numerous large and lacy holes in the cuneate nucleus. Some of these holes appear to contain an eosinophilic fluid that is suggestive of edema. This may be the cells of edema in this area. There is one small circular focus in this area that contains numerous eosinophilic droplets that appear to be within a vessel. The etiology of these small eosinophilic droplets is not known, however they appear to be within a vessel surrounded by a small amount of fibrin. These specific structures do not appear to be protozoa because of the lack of any basophilia in the staining properties. However, a protozoan cannot be totally ruled out. There are neurons within the cuneate nucleus that have undergone degeneration and are just represented by eosinophilic material.

Slide 12: Pituitary gland: The pars nervosa of the pituitary gland does show extensive suppuration of the neural elements in one area suggesting edema. There is a mild degree of gliosis around this area of edema. The pars anteria appears to be within normal limits.

Obex region: This section of obex contains a dorsal and vagus nucleus and hypothalamus. These nuclei are all normal in this region. Even the cuneate nucleus in this region, which is further back from the area previously, described in slide 11. In this area cuneate nucleus only has a small amount of edema and holes.

Spinal cord: This section of spinal cord is from C-1 and it appears to be relatively normal. Spinal nerves in this region are also normal.

Slide 13: Kidneys: There is a mild degree of infiltration of lymphocytes and plasma cells within the interstitial cells of the kidney. The glomeruli for the most part are within normal limits.

Urinary bladder: The mucosa of the urinary bladder is within normal limits. However, there is one small focus deep within the muscular layer that is characterized by a small focus that is filled with large epithelial like cells with large round nuclei. In some areas the cells appear to be perhaps forming gland like structures. These cells appear to be within a dilated lymphatic vessel. This may be an extremely small focus of a carcinoma. In several areas there is an extremely small infiltration of lymphocytes underneath the transitional cell layer of the bladder.

Slide 14: Thyroid gland: No significant lesions.

Adrenal gland: No significant lesions.

Cilia and ganglia: There is a slight degree of hypercellularity to the ganglia but no specific lesions can be discerned.

Skeletal muscle: An occasional fiber has undergone necrosis within this section of skeletal muscle and these necrotic fibers are associated with a minimal degree of inflammation. Otherwise this section is within normal limits.

Slide 15: Multiple sections of heart are examined and several of these sections do contain areas of what appear to be interstitial edema with degeneration of myocardial cells with regeneration. These multifocal areas are scattered throughout the myocardium especially in the left papillary muscle. In several areas edema

and degeneration of myocardial cells is still evident whereas in the other areas it appears to be more of a reparative change.

Large cornea vessels and nerves within the epicardium are within normal limits.

Slide 16: Ileum: No significant lesions.

Colon/cecum: No significant lesions.
Small intestines: There is a cross section of a small fluke in this section of small intestines but otherwise it is considered to be within normal limits.

Mesenteric lymph nodes: These lymph nodes are relatively active but contain a relatively normal amount of lymphoid tissue.

Slide 17: Liver: This section of liver is characterized by mild atrophy of hepatocytes. A few of the bile ducts do contain a slightly increased amount of fibrosis around the adventitia. A large bile duct is also present on this slide. These bile ducts are atelectatic and have disruption of the mucosal layer with an extensive infiltration of lymphocytes and plasma cells. In one area it appears the mucosal layer of the bladder has ulcerated and numerous flukes that are in the lumen actually are in contact with the submucosa.

Slide 18: Mammary gland: This section of mammary gland is relatively active and the alveoli are filled with milk.

Lungs: There are a few multifocal areas of chronic active pneumonia associated with lungworms.

Slide 19: Spleen: The lymphoid tissue of the spleen is relatively normal. The red pulp is collapsed. There is one siderotic plaque in the spleen and a fracture through the spleen that has been replaced by fibrosis.

Pancreas: No significant lesions.

Spinal cord: This spinal cord is from the thoracic region and it is within normal limits.

Tonsil: The tonsil is extremely small and only has a few lymphoid follicles. These follicles are active and considered to be normal. No evidence of necrosis is found within these lymphoid follicles.

Slide 20: Ovaries: Two sections of ovaries are present, one from the right and one from the left ovary. One ovary does have a degenerated corpus luteum and the other ovary has developing

follicles. The ovaries are considered to be within normal limits.

Mediastinal lymph node: This section of lymph node is relatively active and considered to be within normal limits.

Aorta: No significant lesions.

Eye: Two sections of eye are present. Slides A and B: Section A is of the posterior retina. In this area the optic nerve is normal. The retina appears to be normal except for what may be edema or separation of the inner limiting membrane and nerve fiber layer. Because of this separation may be associated with edema. In fact in some areas there appears to be edema within this layer. In areas where there appears to be edema within the nerve fiber layer and the ganglion cell layer, in these areas there appears to be degeneration within the layer rods and cones and also edema within the outer molecular layer. Some of these lesions are difficult because of the sections of the eye, but there are areas in which the retina appears to have pulled away from the tapetum and have formed little rosettes or drusens. It is difficult to tell whether this folding of the retina is a true lesion or not. Further work will have to be done to verify this condition.

Slide B is of cornea and ciliary body: These sections appear to be within normal limits.

Terry R. Spraker/DVM, PhD

Typed: 6/19/98 lm

Veterinary Medical Teaching Hospital
University of California, Davis

23Nov98 at 11:43am

PATHOLOGY BIOPSY
FINAL REPORT

CLINIC NO.:
SPECIES: OTHER SMALL ANIMAL
BREED: SEA LION
SEX: M **LIFESTAGE:** JUVENILE
TAG NO.: CSL #3736 (EIGHT)
CLINICIAN: No Doctor #
OWNER: MARINE MAMMAL CNTR ATTN: EILEEN ECONOMY
ADDRESS: Golden Gate Nat'l Rec Area Bldg 1044
Sausalito, CA 94965
COMMENT: WEIGHT: 32 KG.

PATHOLOGY NO.: 98B 1287
DATE REQUESTED: MAY 26, 1998
RESIDENT: L.J. LOWENSTINE, DVM,PhD

****
SPECIMEN: BIOPSY TISSUE **PRESERVATIVE:** FORMALIN **DATE REPORTED:** NOV 20, 1998
****

PATHOLOGIC DIAGNOSIS:

1) SEIZURES DUE TO PRESUMPTIVE DOMOIC ACID TOXICITY (CLINICAL DIAGNOSIS)
2) BRAIN (HIPPOCAMPUS, PYRIFORM LOBE): MARKED VACUOLATION OF DENTATE GYRUS, CA4, CA3, AND CA1, PYRIFORM LOBE PYRAMIDAL CELL LAYERS AND NEUROPIL, ESPECIALLY STRATUM RADIATUM
3) BRAIN: EQUIVOCAL, ACUTE, NEURONAL NECROSIS DENTATE GYRUS CA3
4) BRAIN: VACUOLATION AND AXONAL SHEATH DILATATION ("INTRAMYELINIC EDEMA"), VENTRAL NUCLEI AND TRANSVERSE FIBERS OF THE PONS, MAMMILLARY BODY, VENTRAL WHITE MATTER OF MEDULLA
5) LUNGS: MODERATE, MULTIFOCAL, SUBACUTE AND GRANULOMATOUS INTERSTITIAL PNEUMONIA, PARASITIC, PRESUMPTIVE
6) LUNGS: MARKED, ACUTE CONGESTION
7) LIVER: MULTIFOCAL GRANULOMATOUS HEPATITIS, PARASITIC, PRESUMPTIVE
8) LYMPH NODES: MULTIFOCAL GRANULOMATOUS LYMPHADENITIS, PARASITIC, PRESUMPTIVE
9) LYMPH NODES, TONSIL AND ILEUM: REACTIVE LYMPHOID HYPERPLASIA
10) HEART: EQUIVOCAL EDEMA

CLINICAL ABSTRACT:

This is a California Sea Lion #3736 named Eight. This sub-adult male sea lion stranded at Grand Avenue, Oceano Dunes in San Luis Obispo County. The strand date is 5/22/98. He was admitted on that same day and died on 5/22/98 at 3:00p.m.. A postmortem was performed on 5/23/98 at 2:00p.m.. His standard length was 112cm, blubber depth was 24mm, axillary girth was 72cm, umbilical girth is 67cm, and he weight is 32kg. His somatic index is 3 out of 7. Clinical signs were seizures and a thick brown mucus from the mouth with labored breathing. He was treated with penicillin.

GROSS NECROPSY:

The gross necropsy performed by Dan Fletcher revealed congested lungs and interstitial edema. The kidneys were swollen with moderate loss of renule differentiation. There was a slightly pale myocardium and a bloody effusion in the pericardial sac. The cerebral vessels were congested.

NOV 1998
DISTRIBUTED
TO
CLINICIAN

GROSS DESCRIPTION:

Submitted is a single large formalin-filled jar which contains the left cerebrum, a portion of the right cerebrum, the cerebellum, one section of spleen, one section of kidney, three sections of liver, tongue, thyroid, urinary bladder, penis, both testicles, seven sections of GI tract, four sections of heart, a great vessel, gall bladder, five lymph nodes, skin, trachea, peripheral nerve, adrenal, and several other unidentified sections of tissue. Representative samples of tissue were cut and placed in biopsy cassettes.

HISTOPATHOLOGICAL SUMMARY:

The following tissues were examined microscopically: (T1) hippocampus, pyriform lobe; (T2) hippocampus, pyriform lobe; (T3) hippocampus; (T4) more caudal hippocampus; (T5) midbrain, pons, cerebellum; (T6) amygdala; (T7) medulla, C1; (T8) pons, cerebellum; (T9) great vessels, tongue, atrium of heart; (T10) trachea, spleen, lung; (T11) stomach, bladder; (T12) heart left side; (T13) salivary gland, lymph node, thyroids; (T14) liver, kidney, pancreas; (T15) liver, lymph nodes; (T16) lymph nodes, nerve, penis; (T17) spinal cord C1; (T18) lymph nodes; (T19) testicle; (T20) tonsil, colon, ileum, jejunum; (T21) skin; (T22) esophagus, stomach, pylorus, GI tract; (T23) adrenal, lymph nodes, salivary gland.

COMMENT:

Peracute changes in the brain are similar to those seen in other California sea lions dying acutely during this unusual mortality event. Although the myocardium was pale grossly, the histologic lesions are relatively unimpressive. Other findings are incidental and presumed secondary to parasitic migrations. There is no evidence of the lymphocytic meningoencephalitis seen in many of the other sea lions in this unusual stranding event.

msl

Linda J. Lowenstine

L.J. LOWENSTINE, DVM, PhD

Veterinary Medical Teaching Hospital
University of California, Davis

17Dec98 at 3:49pm.

PATHOLOGY BIOPSY
FINAL REPORT

CLINIC NO.:
SPECIES: OTHER SMALL ANIMAL
BREED: SEA LION
SEX: F **LIFESTAGE:** ADULT
TAG NO.: CSL#3741, LUMBERJACK, TAG#13180
CLINICIAN: No Doctor #
OWNER: MARINE MAMMAL CNTR ATTN: EILEEN ECONOMY
ADDRESS: Golden Gate Nat'l Rec Area Bldg 1044
Sausalito, CA 94965
COMMENT: WEIGHT: 79.5KG

PATHOLOGY NO.: 98B 1365
DATE REQUESTED: JUNE 4, 1998
RESIDENT: L.J. LOWENSTINE, DVM,PhD

****

SPECIMEN: CARCASS **PRESERVATIVE:** REFRIG. **DATE REPORTED:** DEC 16, 1998

****

PATHOLOGIC DIAGNOSIS:

1) SEIZURES ASSOCIATED WITH DOMOIC ACID TOXICITY (CLINICAL DIAGNOSIS)
2) BRAIN: SEVERE ASYMMETRICAL EDEMA (LEFT SIDE) WITH MARKED MIDLINE SHIFT EXTENDING FROM RHINENCEPHALC THROUGH THE MESENCEPHALON
3) BRAIN: SEVERE, ACUTE TO SUBACUTE LAMINAR CORTICAL NECROSIS, PIRIFORM AND FRONTAL LOBES, AND CINGULATE GYRUS WITH CAPILLARY PROLIFERATION
4) BRAIN, CEREBELLUM: SEVERE, MULTIFOCAL, ACUTE HEMORRHAGE IN CAUDAL VERMIS (EARLY HERNIATION)
5) BRAIN: MODERATE, NONSUPPURATIVE MENINGOENCEPHALITIS, MOST MARKED IN HIPPOCAMPUS AND RHINENCEPHALON
6) HEART: MILD, MULTIFOCAL, ACUTE, MYOFIBER NECROSIS AND VACUOLATION
7) EYE: UNILATERAL HYPOPION
8) EYE: BILATERAL, MILD VACUOLATION OF GANGLION CELL LAYER
9) LIVER: MILD, MULTIFOCAL, GRANULOMATOUS HEPATITIS, PARASITIC, PRESUMPTIVE
10) KIDNEY: MINIMAL LYMPHOCYTIC INTERSTITIAL NEPHRITIS
11) LYMPH NODES AND TONSILS: FOLLICULAR HYPERPLASIA
12) COLON: MILD COLITIS WITH SCATTERED CRYPT ABSCESSES AND COLONIZATION BY FILAMENTOUS BACTERIA
13) COLON: MILD CESTODIASIS
14) LUNGS: MILD PULMONARY NEMATODIASIS (PARAFILAROIDE , PRESUMPTIVE) ASSOCIATED WITH MILD, MULTIFOCAL, SUBACUTE INTERSTITIAL PNEUMONIA
15) UTERUS: GRAVID (GROSS DIAGNOSIS)
16) ADRENAL: HYPERPLASIA AND VACUOLATION OF ZONA GLOMERULOSA

CLINICAL ABSTRACT:

This adult, female, California Sea Lion tag #13180 was stranded on the Boar Walk in Monterey County on 5/23/98 and admitted to the Marine Mammal Center on the same day. She died on 5/29/98 overnight and was found in rigor mortis at 8:30 am on the 29th. Postmortem was performed by W.A. Mclellan at 10:00 in the morning. This adult female had a standard length of 143 cm, axillary girth 106 cm, umbilical girth 86 cm, blubber depth 34 mm and a weight of 79.5 kg actual at time of stranding. She had a 5/7 somatic index. At time of stranding, she was

ɔted to have seizures and had stranded during a time in which other sea lions ere also exhibiting seizures. Gross findings included very enlarged edematous aguinal lymph nodes, congested lungs and a female fetus 71 cm long with 43 cm xillary girth, 37 cm umbilical girth and a weight of 7 kg.

ROSS DESCRIPTION:

The specimen consist of a bucket with formalin and tissues recognized as one ece of kidney, one piece of esophagus, three pieces of intestines, one piece spleen, one piece of spinal cord, one piece of lung, one piece of trachea, e piece of pancreas, two pieces of stomach, one tonsil, two ovaries, five eces of adrenal, three pieces of heart, one piece of aorta, one piece of aphragm, one piece of liver, thirteen pieces of lymph nodes, one piece of erus, one piece of urinary bladder, the brain, two eyes, one piece of salivary r a total of 45 tissues. Tissues were trimmed on 10/7/98 by Hendrick Nollens, terinary extern. The brain was also sectioned by Dr. Nollens. Coronal sections fixed brain revealed a severe midline shift left to right from frontal lobe rough temporal area to mesencephalon. There was no real mass lesion, but the ft ventral side of the brain was softer than the right. Expansion of white tter is present. The lesion is thought to represent asymmetrical edema. There also softening and petechiation of the cerebellar vermis visible grossly thout much evidence of coning.

STOPATHOLOGICAL SUMMARY:

The following tissues were examined microscopically: (T1) spleen, liver, ng, pancreas; (T2) diaphragm, intestinal muscularis, bladder, heart; (T3) dney, salivary gland, adrenal; (T4) colon, ileocecocolic junction, small testine; (T5) stomach; (T6) five lymph nodes; (T7) two ovaries, tonsils, lymph de; (T8,T9) eyes; (T10) frontal lobe of brain; (T11) midbrain, pineal; (T12) dulla, cerebellum, C1; (T13) medulla; (T14) cerebellum, pons; (T15) ventral ppocampus, thalamus, piriform lobe; (T16) left ventral rhinencephalon (frontal rtex); (T17) thalamus at chiasm, cingulate gyrus.

MENT:

Lesions in hippocampus and cingulate gyrus were fairly mild consisting of ronal dropout and mild gliosis, the most severe lesion in the brain was the sive asymmetrical edema. This is an extremely interesting lesion, the exact se of which is uncertain. This is undoubtedly the lesion which resulted in animal's death. The impressive degree of edema and expansion of the white ter suggests vasogenic rather than cytotoxic etiology. Vasogenic edema ally results from a lesion such as an abscess or tumor, but no such lesion seen in this animal. Another possibility is brain contusion. Perhaps zures were violent enough to have resulted in the unilateral lesions. The inar cortical necrosis was symmetrical and compatible with those lesions seen other animals with domoic acid toxicity. Laminar cortical necrosis may also e been secondary in part to the seizures. The nonsuppurative ingoencephalitis is characterized by areas of nodular gliosis and is thought have antedated the other neurologic lesions. The cerebellar herniation is ubtedly the result of the cerebral edema. Its interesting that there is te myofiber necrosis and vacuolation in the heart. Most of the other animals h a course of four or more days post-stranding have had subacute lesions in heart. The acute lesions may have resulted from transient ischemia or ythmias during seizures. The bilateral vacuolation of retinal ganglion cell ers has been seen in other animals in this unusual mortality event. It is not tain whether this is directly due to the domoic acid. Other lesions are

fairly mild and probably clinically insignificant.

la

Linda J. Lowenstine
L.J. LOWENSTINE, DVM, PhD

COLORADO VETERINARY DIAGNOSTIC LABORATORY
College of Veterinary Medicine and Biomedical Sciences
Colorado State University, Fort Collins, CO 80523
Phone 970-491-1281
Fax 970-491-0320

DL#: 978-38154
Date:

Vet/Clinic: Francis Gulland
Owner: The Marine Mammal Center
Animal ID: CSL3743 **Date Specimen Taken:**
Species: Z. californias **Breed:** **Age:** Adult **Sex:** F

History: This is an adult California sea lion number CSL3743. This animal was brought into the Marine Mammal Center on 5/23/98 and died during the night. The animal was posted the next morning. The primary clinical signs included seizures. See gross necropsy report for detailed report.

DIAGNOSIS:
1. Neuronal necrosis and edema of neuropil, severe, hippocampus, mild, neurons of parietal cortex of cerebrum, Purkinje cell layer, roof nuclei of cerebellum, reticular formation of myelencephalon, olivary nuclei.
2. Moderate intramyelinic edema, white matter of cerebral cortex, septal nuclei, optic tracts, internal capsule, mesencephalon thalamus, cerebellum and brain stem.
3. Mild edema with early neuronal degeneration, myenteric plexus, small and large intestines.
4. Myocardial edema, mild with an occasional necrotic myocardial cell.
5. Pulmonary edema, severe, with autolysis and microfilaria, lung.
6. Lymphoid depletion, moderate, generalized, lymph nodes and spleen.

REMARKS: The primary lesions in this animal are associated with acute neuronal necrosis with severe edema of the hippocampus with mild neuronal necrosis and mild edema of the neuropil scattered throughout the brain especially within the amygdaloid nuclear complex. There is also a moderate degree of intramyelinic edema throughout the white matter tracts of the cerebrum, thalamus and brain stem. These lesions could account for the seizures and death of the animal. The cause of the mild myocardial edema may be associated with the seizures.

HISTOPATHOLOGY: Slide 1 is of corpus callosum, caudate nucleus, basal ganglian region: The only lesion found here is extremely mild intramyelinic edema within a few of the axons within the

internal capsule and the septal nuclei. The frontal cortex in this region is within normal limits.

Slide 2: Section of thalamus and hypothalamus with amygdaloid nuclear complex: There is extensive intramyelinic edema within the internal capsule in this region. There is also a moderate degree of edema of the neuropil within the amygdaloid nuclear complex and in the lateral nuclei of the thalamus probably the ventral rostral nucleus of the thalamus. Intramyelinic edema is also found within the optic tract in this region. Neurons of the amygdaloid nuclear complex do show evidence of chromatolysis and a few neurons are undergoing acute necrosis. The VR spaces in the amygdaloid nuclear complex are also markedly dilated correlating with the relatively severe edema of the neuropil in this region. Mild edema is found within the lateral nuclei of the thalamus but no evidence of nuclear necrosis is found within this specific region. Meningeal vessels are within normal limits.

Slide 3: Parietal lobe cortex: There is an extremely mild degree of edema within the neuropil of the cortex of the parietal lobe and an occasional neuron in the deep lamellar layer has undergone acute necrosis. Moderate intramyelinic edema is found throughout the white matter tracts of the parietal lobe.

Slide 4: Mesencephalon including pons oculomotor nucleus and superior colliculus: Cells of the pineal body appear swollen but no evidence of necrosis is observed. The superior colliculus do contain a few axons coursing through it that have intramyelinic edema but neuronal necrosis is not observed. The central gray substance, oculomotor nucleus and interpeduncular nucleus do contain a small degree of edema of neuropil and intramyelinic edema but no neuronal necrosis is not observed in these areas. The pons contain mild edema of the neuropil and intramyelinic edema. Mild chromolysis is observed in neurons but necrosis is not a prominent feature. Red nucleus and substantia nigra in this region also has extremely mild edema but no evidence of neuronal necrosis.

Slide 5 contains brain stem at the level of the tegmental nucleus and pons and a section of obex. The tegmental nucleus also shows mild edema but no evidence of neuronal necrosis. Pontine nuclei in this region is similar to what was observed in slide 4. The obex region contains the dorsal vagus nucleus and hypoglossal nucleus of which appear to be relatively normal. The nucleus of the spinal tract of the trigeminal nerve is also normal. There are large eosinophilic neurons within the reticularis nucleus (nucleus reticularis giganta). These large neurons have an eosinophilic cytoplasm and the nucleus is beginning to undergo lysis. Mild edema is also present within

this nucleus. Olivary nuclei also show mild edema and only an occasional neuron has undergone acute necrosis. Intramyelinic edema is found within the dorsal spinal cerebellar tract in this region of obex.

Slide 6: Cerebellum with cerebellar roof nuclei and hippocampus: A few of the Purkinje cells show early eosinophilia of the cytoplasm suggesting early neuronal necrosis. There is a mild degree of edema in the molecular layer and within the white matter tracts of the cerebellum. The granular cell layer appears to be relatively normal. Early neuronal necrosis and edema of the neuropil is also found within the dorsal roof nuclei of the cerebellum.

Alveolus/hippocampus: The white matter tracts under the ependyma covering the alveus are within normal limits. The polymorphous layer is relatively normal. Numerous neurons in the pyramidal layer have undergone acute necrosis and have eosinophilic cytoplasm. The neuropil within this region is also severely edematous. This layer appears to co-join in with the dentate gyrus in which neurons of the cortex of this region are also necrotic and severe edema of the neuropil is present. Mild gliosis is also present throughout this region. There is extensive spongy change within the stratum radiatum and this is most likely associated with severe edema within this area. Numerous neurons of the molecular layer are also eosinophilic and have undergone acute necrosis. The neurons in the molecular layer are a lamellar area of relatively small neurons. Severe edema is also present within this region.

Slide 16: Slide 16 is of hippocampus. This is more of the C-1 region whereas slide 6 was of the C-4 region. This section of hippocampus is identical to slide 6 showing extensive neuronal necrosis in the pyramidal cell layer and within the molecular cell layer and extensive edema of the stratum radiatum.

Slide 17: Cerebellum with roof nuclei and occipital cortex: This section of cerebellum does show mild edema within the Purkinje cell layer and an occasional Purkinje cell that is undergoing necrosis. The molecular layer is relatively normal. Mild edema is present within the white matter tracts in this area. There is one nucleus undergoing necrosis within the roof nuclei in this region and perhaps mild edema within this nucleus. There is moderate intramyelinic edema of the white matter tracts of the occipital cortex but the cortical gray in this region is relatively normal.

Slide 7: Placenta: There is a moderate degree of hemorrhage within this section of placenta, however this is a normal finding in placentas from sea lions. Vessels within the placenta appear to be congested and a few small areas of

necrosis associated with a few neutrophils are present. However, these inflammatory cells are primarily associated with the areas of hemorrhage and hemosiderin accumulation. These areas are all probably within normal limits.

Slide 8: Adrenal gland: No significant lesions.

Large intestines: This section has undergone autolysis of the mucosa but is within normal limits.

Small intestines: Several sections of small intestines are examined. The lumen does contain mucus and bacteria. There is an occasional crypt that is slightly filled with cellular debris but this is within normal limits. There may be edema within the mesentery plexus of the small intestines, however neuronal necrosis was not observed. What is observed is numerous holes in essentially the neuropil of the postganglionic ganglia.

Ureter: No significant lesions.

Lungs: This section of lungs has undergone relatively severe autolysis. Post partem bacteria are present throughout the lung. An occasional microfilaria can also be found within this section of lung. Several cross sections of parasites probably parafilaroides are present within this section of lung. This section of lung is also characterized by severe edema.

Slide 9: Heart: Sections of left ventricle/papillary muscle and atrium and right ventricle are examined. It does appear to be mild separation between the myocardial cells and a few holes within the myocardial cells suggesting diffuse myocardial edema, probably edema also within the cysterna within the heart. An occasional myocardial cell is necrotic but this change is relatively rare. Cross section of a coronary artery and vein are within normal limits.

Slide 10: Colon: The lymphoid follicles of the colon are relatively normal. Nerves within the colonic muscular wall appear normal in this region.

Colonic mucosa: Normal. Myentery plexus however between the muscular layers do show evidence of a spongy change and neuronal edema suggesting edema and early neuronal degeneration within the myenteric plexus of the colon.

Esophagus: The surface of the esophagus is relatively normal. The salivary tissue of the esophagus is normal. A few sarcocysts of the small bradyzoite variety are found within the musculature of the esophagus. An occasional aggregate of lymphocytes can also be found within this muscle. This muscle in this region of esophagus is skeletal muscle.

Lymph node: This lymph node shows a severe lymphoid depletion with moderate edema within sinusoids. Medullary rays are composed mostly of lymphocytes with a few plasma cells. Occasionally a few neutrophils can be found within sinusoids. There are also bits and pieces of material that appear to be parasite cuticle and splendorahephry reaction within this particular lymph node.

Slide 11: Liver: There is a mild degree of focal congestion especially within central veins within the liver but otherwise the hepatic cells are relatively normal.

Heart: This section of heart does contain a few small focal areas of lymphoid cells. Purkinje cells in this region are normal.

Cervix/vagina: Vessels of the bladder are severely congested but the transitional cell epithelial layer appears to be relatively normal.

Slide 12: Ovary: This section of ovary does contain a large corpora luteum, however a moderate number of the luteal cells appear to be undergoing necrosis. However, this is the normal time for parturition so this may be a normal process. Otherwise the ovary appears to be within normal limits.

Lymph node: This lymph node does contain mild lymphoid depletion. Sinusoids are filled with hemorrhage.

Spleen: The small follicular lymphoid tissue of the spleen is moderately depleted. The red pulp is slightly congested but is of normal cellularity.

Gastric mucosa: This section does contain areas in which the superficial gastric mucosa has undergone acute autolysis. Numerous bacteria are present on the surface of these small areas. These areas would appear as white plaques on the surface of the mucosa but are probably small focal areas of acute autolysis. However, they may be really early areas of erosion but if it is the lamina propria and mucosal cells are still intact. However there are many post mortem bacteria on the surface of these areas.

Slide 13: Adrenal gland: No significant lesions. Nerves around this section of adrenal gland are also within normal limits. The ciliate ganglia adjacent to the adrenal gland appears to be normal in this section.

Tonsil: The lymphoid tissue of the tonsil is somewhat depleted and many of the follicles show evidence of lymphoid necrosis. Vessels of the tonsil are also moderately congested.

Kidneys: No significant lesions.

Lymph node: This lymph node has undergone advanced autolysis. This is probably a mesenteric lymph node perhaps a gastric lymph node, however the autolysis is to such an extent that the node cannot be evaluated.

Slide 14: Two lymph nodes are present on this slide. Both are similar. There is a mild degree of follicular depletion but otherwise these nodes are considered to be relatively normal.

Urinary bladder: No significant lesions.

Pituitary gland: No significant lesions.

Liver: This section of liver is similar to the one previously described. This section however has one small focus of lymphoid cells probably due to some type of parasitic migration.

Slide 15: Thyroid gland: Follicles are of normal size and shape.

Placenta: This section of placenta is similar to the ones previously described.

Liver: This section of liver does contain three small focal areas of necrosis associated with lymphocytic infiltration. These sections of inflammation are primarily associated with bile ducts or within the parenchyma. These lesions are most likely associated with some type of parasitic activity.

Stomach: This section of stomach does contain several areas in which the mucosal cells has undergone acute necrosis and numerous bacteria are present on the surface. These areas would have appeared as white plaques on the gross exam. These areas of necrosis are extremely acute and are probably much larger due to autolysis but they may have been early or extremely erosions associated with either stress or some type of bacterial activity.

Terry R. Spraker/DVM, PhD

Typed: 5/18/98 lm

COLORADO VETERINARY DIAGNOSTIC LABORATORY
College of Veterinary Medicine and Biomedical Sciences
Colorado State University, Fort Collins, CO 80523
Phone 970-491-1281
Fax 970-491-0320

DL#: 978-38155
Date:

Vet/Clinic: Francis Gulland
Owner: The Marine Mammal Center
Animal ID: Reid - CSL3744 **Date Specimen Taken:**
Species: Z. callifornias **Breed:** **Age:** Adult **Sex:** F

History: This is an adult female California sea lion number CSL3744. This animal was found stranded on 5/23/98 and was taken to the Marine Mammal Center on that same day and died that evening. The animal was posted the next day. More detailed gross necropsy report see submitted papers.

DIAGNOSIS:
1. Neuronal necrosis, mild, cerebral cortex, amygdaloid nuclear complex, hippocampus, ventral caudal lateral and ventral caudal medial nucleus of the thalamus and Purkinje cell layer and reticular formation with mild to moderate edema of the neuropil, brain.
2. Intramyelinic edema, cerebral cortex, white matter of the internal capsule, corpus callosum, thalamus and brain stem region.
3. Mild myocardial edema, diffuse, right ventricle, heart.
4. Pneumonia, minimal, multifocal, lymphocytic/suppurative, lungs associated with parasites.
5. Lymphoid necrosis, moderate, follicular, acute tonsils.
6. Gastritis, ulcerative, severe, gastric mucosa associated with nematodes.

REMARKS: The lesions in this animal are mostly associated with neuronal necrosis, neuropil edema and intramyelinic edema of the brain. The other lesions other than the mild myocardial edema are incidental findings. The cause of the lymphoid necrosis of the tonsil was not determined but may be associated with a severe stress response. The blister like lesions in the esophagus do no have any evidence of inflammation around them. The cause of these lesions are not determined. Some considerations for the etiology of these small like blisters could possibly be a mild calici virus infection. There is a remote possibility that these are actually normal structures but if they are the only possible one they could be would be small orifices of salivary tissue from the esophagus, however they really do not look like these types of structures.

HISTOPATHOLOGY: Slide 1: This section is of the level of the caudate nucleus, corpora striatum, olfactory stria and septal nuclei. There is mild edema within the septal nuclei and the

cortical tissue around the olfactory stria. Caudate nucleus appears relatively normal. There is intramyelinic edema is present within the internal capsule.

Slide 2: Brain stem at the level of the superior colliculus and anterior aspect of pontine nucleus. Moderate to severe intramyelinic edema is found within the pons but no neuronal necrosis is not found. The remaining area in this section including the central gray substance the oculomotor nucleus and the superior cuniculus are all relatively normal. However, there are few axons that do show evidence of intramyelinic edema throughout this section.

Slide 3: Hippocampus and amygdaloid nuclear area. The nuclei of the hypothalamus are all within normal limits. The majority of the nuclei of the thalamus are normal except for the ventral, caudal lateral and ventral caudal medial nucleus, which is associated with proprial seption. Within these areas there is extensive edema and early neuronal degeneration and necrosis. The edema is extensive but the neuronal necrosis is considered mild. There is extensive edema of the neuropil of the amygdaloid nuclear area with mild early nuclear degeneration within this area. In some areas the nuclei appear to be swollen and in other areas they appear to be accumulating mineral and occasionally they will have a slight eosinophilia to the cytoplasm. Many of these neurons are showing central chromolysis.

Slide 4: Cerebellum with roof nuclei. The molecular layer is relatively normal. A few of the Purkinje cells are beginning to have an eosinophilic cytoplasm and there appears to be edema within this layer. The molecular layer is relatively normal. A moderate degree of intramyelinic edema is present within the white matter tracts. Extremely mild edema is found within the roof nuclei but neuronal necrosis is not found within the roof nuclei in this particular section.

Slide 5: Cerebral cortex: There is mild degree of edema within the deep laminar cortical areas of the cerebral cortex. A few of the neurons also are showing early neuronal necrosis. These areas are probably associated with edema and secondary deep cortical laminar necrosis.

Obex region: This section of obex contains vagus and hypoglossal nuclei, spinus tract of the trigeminal nerve and olivary nuclei and reticular nucleus. Occasional axons in this region is characterized by intramyelinic edema and a few eosinophilic neurons are found within the reticularis nucleus but otherwise this section has few lesions.

Pituitary gland: This section of pituitary is within normal limits.

Hippocampus: This section of hippocampus does contain mild neuronal necrosis and severe neuropil edema within the pyramidal. There is mild necrosis and edema in the molecular layer. An extensive degree of spongy change which is most likely edema is present in the stratum radiatum.

Slide 7: Papillary muscle, left ventricle: No significant lesions.

Skeletal muscle, diaphragm: This section is relatively fragmented but no lesions are found.

Atrium: This section appears to be relatively normal. There is some separation of fibers which may be associated with mild edema but this is difficult to discern.

Right ventricle: There is also separation of fibers here that may suggest early edema. Some of the myocardial cells in this section do appear slightly swollen.

Slide 8: Lungs: The capillaries of the lungs are moderately congested. There is a small amount of debris in many of the bronchioles, but this is within normal limits. There are a few areas in which alveolar spaces are filled with lymphocytes admixed with a few neutrophils. These are probably areas of parasitic migration and activity. In a few other areas alveolar spaces are partially filled with edema.

Slide 9: Skeletal muscle: This section of skeletal muscle is relatively normal.

Thymus and thoracic inlet lymph node: The thymus contains a normal amount of lymphoid cells. There is a moderate degree of hemorrhage within the medullary regions of the thymus. This is a relatively non-specific and relatively common finding.

Lymph nodes: These lymph nodes are thoracic and tracheal nodes. These nodes are characterized by follicular depletion however parafollicular cells are of normal amount. These nodes are considered to be within normal limits for a stressed wild or free-ranging animal.

Slide 10: Liver: This section of liver is within normal limits.

Tonsil: The tonsil has numerous active follicles. The tonsils are slightly hyperplastic but they are beginning to show evidence of small lymphocyte depletion. A moderate number of these follicles also show lymphocytic necrosis. Vessels throughout the tonsil are also congested. There is a mild degree of inflammation in some of the tonsillar crypts, however this is extremely common for free-ranging sea lions. However, the degree of necrosis is quite unusual.

Pancreas: This pancreas does show evidence of autolysis. No significant lesions are found.

Slide 11: Thyroid: The follicles of the thyroid gland are within normal limits.

Kidneys: Vessels throughout the kidneys are congested but the glomeruli and tubules are within normal limits.

Spleen: The spleen is slightly congested and lymphoid follicles are severely depleted.

Esophagus: There appears to be several small blister like structures within the esophagus. It is difficult to tell whether this is a real lesion or not. These areas however are characterize by what appears to be a blister like formation within the stratum spinosum. Keratocytes are present within this blister like structure but there is no evidence of inflammation or actual necrosis within this area. These blister like structures appear to be bacteria in them and in many areas the bacteria appear to be around cells. These blister like structures are suggestive of what has been observed with mild calici virus infections.

Slide 12: Small intestines: Several sections are examined. The surface is somewhat autolytic and the mesenteric plexus appear to be edematous however neuronal necrosis is not observed but there is some suggestion of really early stages of degeneration in some of the neurons. The nerves of the gastrointestinal tract appear to be normal. Occasional vessels within the serosa are surrounded by lymphoid cells. The lymphoid tissue of the small intestines is depleted. There is one small focus in one section of intestines that contains an extensive infiltration of eosinophils and neutrophils within the submucosa. This is most likely associated with a previous parasitic attachment site.

Stomach: This section of stomach does contain a large gastric ulcer that is characterized by extensive necrosis of the mucosa through the submucosa but does not penetrate any deeper. There is an extensive infiltration of lymphocytes, plasma cells and macrophages and fibrosis within this area. Numerous parasites or cross sections of parasites associated with numerous bacteria are found within the crater of this ulcer.

Slide 13: Adrenal gland: There is a moderate degree of edema between the cords of the adrenal cortex particularly in the zona fasciculata. Vessels of the adrenal gland are also congested especially at the cortical medullary junction. Many of the cells especially of the cortex have an eosinophilic cytoplasm but is difficult to tell whether these cells are actually undergoing necrosis or not. Perhaps this is a post mortem change in this particular animal.

Small intestines: Same as observed earlier.

Esophagus: This section of esophagus also has a few of those little blister like regions. These probably are not real blisters but the significance of them at the present time is not known. There are several cross sections of a nematode within the salivary gland of the esophagus.

Stomach: This section of stomach does contain a few areas of increased lymphocytes and lymphoid follicles within the lamina propria and submucosa. This section of stomach is taken from the pyloric region.

Slide 14: Lymph node: This is a large node, probably a gastric lymph node. Lymphoid follicles are large and active but appear to be undergoing early lymphoid depletion. Another lymph node, probably a mesenteric lymph node is relatively active and considered normal.

Large intestines: No significant lesions.

Spinal cord: No significant lesions.

Ovary: This section of ovary contains numerous small-developing follicles and is considered to be within normal limits.

Lymph node: This lymph node is relatively normal.

Uterus: This section of uterus does contain an extensive amount of hemorrhage. This is probably a site where a placenta was attached. The endometrium is considered to be within normal limits.

Liver: At least one focal area of necrosis with infiltration of inflammatory cells is found in the liver. This is most likely a parasitic migration site.

Slide 16: Cerebellum with cerebellar roof nuclei: The molecular layer is relatively normal. A few necrotic Purkinje cells are found within the Purkinje cell layer. These cells have eosinophilia to the cytoplasm. The molecular layer is relatively normal in this section. The white matter within the folia just occasionally will have a few axons that have intramyelinic edema. Neurons of the roof nuclei in this section are relatively normal and little to no edema is found in this particular section.

Thalamus: This section of thalamus does contain a few areas of intramyelinic edema and also intramyelinic is present in the edge of the internal capsule. Neuronal necrosis is not found in this particular section. Extensive neuropil edema and early neuronal necrosis is found within the amygdaloid nuclear complex in this region.

Slide 17: Brain stem at the level of superior cuniculus and pineal body: The pineal cells appear slightly swollen and have clear cytoplasm but no evidence of neuronal necrosis is found. A few large motor neurons within the oculomotor nucleus in this region are undergoing nearly necrosis. The superior cuniculi in this region are normal. The corpus callosum at this level does show evidence of moderate intramyelinic edema.

Terry R. Spraker/DVM, PhD

Typed: 6/18/98 lm

eterinary Medical Teaching Hospital
niversity of California, Davis

17Dec98 at 3:58pm.

PATHOLOGY BIOPSY
FINAL REPORT

LINIC NO.:
PECIES: OTHER SMALL ANIMAL
REED: SEA LION
EX: M BIRTHDATE: 1994
AG NO.: CSL #3745 (THIERAN) TAG #13158
LINICIAN: No Doctor #
WNER: MARINE MAMMAL CNTR ATTN: EILEEN ECONOMY
DDRESS: Golden Gate Nat'l Rec Area Bldg 1044
Sausalito, CA 94965
OMMENT: WEIGHT: 39 KG.

PATHOLOGY NO.: 98B 1718
DATE REQUESTED: JULY 14, 1998
RESIDENT: L.J. LOWENSTINE, DVM,PhD

****
PECIMEN: BIOPSY TISSUE PRESERVATIVE: FORMALIN DATE REPORTED: DEC 17, 1998
****

ATHOLOGIC DIAGNOSIS:

1) DEPRESSION ASSOCIATED WITH DOMOIC ACID INTOXICATION (CLINICAL DIAGNOSIS)
2) BRAIN, ANTERIOR VENTRAL HIPPOCAMPUS: BILATERAL, SEGMENTAL VACUOLATION OF DENTATE GYRUS WITH THE FORMATION OF SPHEROIDS; MILD PYKNOSIS AND VACUOLATION OF HIPPOCAMPAL SECTOR CA3; AND MILD LAMINAR VACUOLATION OF STRATUM RADIATUM
3) BRAIN, PIRIFORM LOBE: MARKED VACUOLATION AND LAMINAR PYKNOSIS OF VENTROMEDIAL PIRIFORM LOBE NEURONS WITH MILD, DIFFUSE MICROVESICULAR VACUOLATION OF NEUROPIL
4) LUNGS: SEVERE, CHRONIC, SUPPURATIVE VERMINOUS PNEUMONIA WITH SECONDARY BACTERIAL PNEUMONIA, PARAFILAROIDES PRESUMPTIVE AND KLEBSIELLA PNEUMONIAE CULTURED
5) STOMACH: SEVERE ULCERATIVE PARASITIC GASTRITIS WITH INTRALESIONAL ANASAKIDS
6) TONSIL: MARKED FOLLICULAR HYPERPLASIA WITH MULTIFOCAL, SUPPURATIVE TONSILITIS (MIXED GRAM POSITIVE, GRAM NEGATIVE AND ANAEROBIC BACTERIA CULTURED)
7) BILE DUCT: MARKED, LYMPHOCYTIC CHOLEDOCHITIS WITH TREMATODE EGGS, ZALOPHATREMA HEPATICUM PRESUMPTIVE
8) ILEOCECOCOLIC JUNCTION: MILD TYPHLOCOLITIS WITH MULTIFOCAL CRYPT HERNIATION AND MULTIFOCAL CRYPT ABSCESSES ASSOCIATED WITH A SINGLE LUMINAL ACANTHOCEPHALID AND MULTIPLE LUMINAL LUNGWORM LARVAE
9) ILEUM AND JEJUNUM: MODERATE TREMATODIASIS (PATENT INFECTION) ASSOCIATED WITH MILD EOSINOPHILIC ENTERITIS
10) EYE: VACUOLATION OF GANGLION CELL LAYER AND INNER MOLECULAR LAYER
11) LIVER: MILD, ACUTE, CENTRILOBULAR CONGESTION AND MILD, DIFFUSE KUPFFER CELL HEMOSIDEROSIS
12) LYMPH NODE, PRESUMED BRONCHOHILAR: MARKED REACTIVE HYPERPLASIA AND MILD LYMPHADENITIS ASSOCIATED WITH NEMATODE LARVAE IN LYMPHATICS
13) BODY AS A WHOLE: ATROPHY OF VISCERAL FAT
14) TONGUE: GROUPED MYOFIBER ATROPHY, DEGENERATION,

13 14 15 16 17 18 19 20 21 22 23 24 25 26 27 28 29 30 31
DISTRIBUTED
CLINICIAN

AND SACROLEMMAL PROLIFERATION

CLINICAL ABSTRACT:

This approximately three year old male California Sea Lion was stranded at Oceano Dunes in San Luis Obispo County on 5/22/98 and was admitted to the Marine Mammal Center the same day. It died on 6/12/98 at 10:00 PM and post mortem exa was performed the following day at 4:00 PM. There was early evidence of decomposition. The animal was emaciated with a standard length of 122 cm, an axillary girth of 72 cm, umbilical girth 64 cm, blubber depth 4 mm, and an actual weight of 39 kg. Clinical signs exhibited had been depression and anorexia, and the animal had been treated with Dual Pen. Postmortem was performed by J. Hoppran who found 4+ nematodes in the stomach and six large non-perforating volcanic ulcers. The bile ducts were patent but enlarged and t gallbladder distended with bile and there was 3+ bile staining in the abdomen. There was generalized lymphadenopathy with enlarged prescapular lymph nodes, a gastric lymph node 6 x 4 x 2 cm and a hilar lymph node 7.0 x 3.0 x 1.5 cm. The stomach was packed with nematodes and some were also present in the esophagus. The lung had 4+ Parafilaroides and multiple caseous nodules that oozed green-yellow mucoid material on cut section. Klebsiella pneumoniae was cultured from these nodules. The tonsils were enlarged and the crypts were filled with brown mucoid material from which Beta-Streptococcus, Enterococcus, E. coli, Pseudomonas aeruginosa, and Bacteroides fragilis were cultured.

GROSS DESCRIPTION:

The specimen consisted of a bag labelled "CSL 3745 - Thieran" containing formalin and tissue samples. Samples were recognized as brain, one eye, three pieces of heart, four pieces of liver, two pieces of kidney, four pieces of lung, one piece of urinary bladder, two adrenals, one testis, one piece of penis, one skin and blubber, four pieces of intestine, three pieces of stomach, two pieces of gallbladder and pancreas, one piece of salivary gland, one piece of muscle, one piece of diaphragm, one axillary lymph node, pieces of other lymph nodes, two tonsils, one thyroid, and one piece of tongue for a total of 43 tissue samples. The tissue was trimmed by Hendrick Nollens on 7/14/98 and the brain was also sectioned by Hendrick Nollens on 8/3/98.

HISTOPATHOLOGICAL SUMMARY:

The following tissues were examined microscopically: (T1) adrenal, bile duct, pancreas, lymph node, salivary gland; (T2) stomach X2, skin; (T3) 3X lym nodes, (T4) tonsil, penis with urethra, bladder; (T5) tongue, diaphragm, skeletal muscle, heart (T6) thyroid, 2X lymph nodes; (T7) kidney, lung, liver, spleen; (T8) colon, cecum, ileum, small intestine X2; (T9) eye; (T10) medulla, caudal medulla/C1, pituitary, pineal; (T11) pineal with midbrain; (T12) cerebellum, pons; (T13) two sections of ventral hippocampus; (T14) right side caudate nucleus and cingulate gyrus left and right.

COMMENT:

This juvenile, sub-adult, male, California Sea Lion had severe parasitism, but also had brain lesions compatible with domoic acid intoxication. Vacuolatic of ganglion cell layer in the eye is similar to that seen in other animals in this outbreak; however, this was the only animal examined, thus far, with degeneration of the inner molecular layer. This latter change is similar to tha described in rats with experimental domoic acid intoxication. Muscle fiber changes in the tongue are possibly neurogenic suggesting damage to hypoglossal or glossal pharyngeal nucleus. This is the only animal examined so far in which dentate gyrus damage has been characterized by the presence of round spheroids

which appear to be fragments of the pyramidal cells or their axons. Although this animal was in rehab for over three weeks, there is no evidence of neovascularization or of the mild, diffuse gliosis that has been seen in other animals in this outbreak. There is also no evidence of ongoing acute neuronal necrosis. Perhaps this animal was not seizuring and thus, the hypoxic lesions supraimposed on the initial domoic acid insult (as has been seen in many of the other animals) was not present.

la

Linda J. Lowenstine
L.J. LOWENSTINE, DVM, PhD

COLORADO VETERINARY DIAGNOSTIC LABORATORY
College of Veterinary Medicine and Biomedical Sciences
Colorado State University, Fort Collins, CO 80523
Phone 970-491-1281
Fax 970-491-0320

REVISED

DL#: 978-39394
Date: 6-1-98

Vet/Clinic: Dr. Francis Gulland
Owner: The Marine Mammal Center
Animal ID: 3746, Finnegan **Date Specimen Taken:** 5-22-98
Species: Z. californianus **Breed:** **Age:** Adult **Sex:** F

History: This is a California sea lion #CSL3746, named Finnegan. This is an adult female that was found seizuring and brought into the Marine Mammal Center of 22 May 1998. The animal was euthanized on June 1, 1988, therefore this animal probably had ingested this toxin 10-11 days prior to euthanasia.

DIAGNOSIS:
1. Encephalomalacia, severe amygdaloid nuclear complex with nonsuppurative encephalitis, brain
2. Neuronal loss, severe, hippocampus with severe gliosis.
3. Atrophy, mild, diffuse hepatocytes, liver.
4. Hepatitis, mild, multifocal, liver, compatible with parasitic activity.
5. Pneumonia, minimal, multifocal, lungs compatible with parafilaroides activity.
6. Mild fibroplasia and edema, heart.
7. Renal cyst, multiple renal cortex, kidney.
8. Granuloma, mammary gland.
9. Thymic atrophy, moderate, thymus.

REMARKS: The primary lesions in this animal appear to be the reparative or resolution changes within the brain especially of the hippocampus and the amygdaloid nuclear complex. Many of the neurons of the pyramidal cell layer and the molecular cell layer of the hippocampus are gone. There is also extensive lymphocytic infiltration and malacia within the amygdaloid nuclear complex. These two structures are the primary parts of the entire limbic system of the animal. There is also extensive neuronal loss and edema probably of astrocytes of the rhinencephalon. The mild myocardial lesions may be associated with this toxic problem, however, all of the other lesions found in this animal were considered incidental findings.

GROSS NECROPSY: There is a small 2 mm raised lesion in the proximal portion of the esophagus. Fibrin is present on the surface of the epicardium. The right kidney has a 2x1 cm renal cyst. One volcanic ulcer is present in the fundic region of the stomach. A few tapeworms and acanlocephalids are present in the small intestines. The animal is not pregnant and numerous flukes are found within thickened bile ducts.

HISTOPATHOLOGY: Slide 1 is from the olfactory area and rhinencephalon. The olfactory tubercle is relatively normal. There is infiltration of lymphocytes and mild lymphocytic cuffing within the olfactory nuclei. There is extensive vacuolization within the cortex of the rhinencephalon. There is also evidence of mild neuronal necrosis in this area. The exact location of the numerous large vacuoles within the rhinencephalon appears to be in astrocytes and not neurons, however, there are a few areas in which there does appear to be neuronal vacuolization, however, the predominant features appears to be large vacuoles surrounding neurons. This change appears to be most severe in the rhinencephalon but can be found on a more sporadic basis within the frontal cortex. There is also a mild degree of infiltration of lymphocytes within the meninges over the frontal cortical areas. There is also a mild gliosis within the white matter of the frontal lobe and rhinencephalon.

Slide 2/Caudate nucleus - The cingulate gyrus is within normal limits. There are few holes in the corpus colosum that were probably areas of intramyelinic edema. A section in this area is of rhinencephalon, the cortical region and this area does contain a few eosinophilic neurons with mild gliosis and lymphocytic cuffing. In a nuclear area on the floor of the caudate nucleus which is probably the accumbens septi nucleus do have numerous holes. The origin of these holes is not determined but as with the rhinencephalon is probably of astrocytic origin. An anterior section of putamen in this section also shows mild edema and central chromatolysis of neurons. The effect in this area is present but appears to be mild, however, few holes throughout suggestive of astrocytic edema and astrocytosis can be found. In one area, especially in the ventral aspect of the putamen moderate numbers of eosinophilic neurons are present, however, this area is extremely close and probably somewhat intermixing with the nucleus of the olfactory stria. There is a mild degree of gliosis in the optic tracts but no real evidence of edema in this particular area. Hypothalamic nuclei are within normal

limits. A few vessels cuffed by lymphocytes and holes and mild gliosis is found within thalamic adhesion. Moderate number of holes, neovascularization, and mild lymphocytic cuffing is especially present in the medial dorsal nucleus of the thalamus but the large interior medial nucleus of the thalamus only has minimal changes. Only an occasional hole is found within the internal capsule in this region. Evidently much of the thalamic lesions and intramyelinic edema of the corpus colosum and internal capsule has resolved in these latter cases.

Slide 4 is also of thalamus, hypothalamus, and pituitary gland - The only addition to Slide 4 as compared to Slide 3 is that this section does contain part of the anterior region of the amygdaloid nuclear complex. This region is characterized by mild lymphocytic cuffing of vessels and mild diffuse gliosis. A few eosinophilic neurons and holes can be found throughout this region.

Slide 5/This section is also taken from the thalamus at the mid-hypothalamic area containing the pituitary gland with pituitary gland stock. The pars anteria or the anterior pituitary gland appears to be within normal limits. Within the pars nervosa and the stock of the pars nervosa there are multiple large areas of eosinophilic lakes that may be suggestive of pooling of some of the neurosecretory substances normally found within the pituitary gland stock. There is one focus within the meninges at the junction of the pituitary gland and pituitary gland stock in the brain that is characterized by central core of mineralization surrounded by macrophages and multinucleated giant cells and fibrosis with extensive lymphoplasmacytic cuffing. This may be a sight of previous parasite activity but no organisms such as parasites are observed in this particular area. Cross section of ocular motor nerve is present on this slide and in this region the axons and schwann cells appear to be within normal limits. There is extensive lymphocytic cuffing and areas of malacia within the amygdaloid nuclear complex. This area of malacia is characterized by loss of neuropil with extensive infiltration of jitter cells. Numerous eosinophilic blobs which are degenerated and in remnants of neurons can be found within this region. A small segment of hippocampus is present on this slide. It is somewhat difficult to even identify because many of the cells of the pyramidal cell layer are gone and there is a moderate degree of gliosis throughout. Molecular cell layer is not found in this region of the tail of the hippocampus.

Slide 6/Thalamus level of habendular nucleus - The habendular nucleus and the nucleus of the habendulointerpeduncular tract have a few holes but not a significant number with mild gliosis, however, what appears to be probably the end of the medial dorsal nucleus of the thalamus contains numerous holes in the neuropil. Some of this vacuolization may also be in the posterior lateral nucleus of the thalamus. Many of the neurons of the ventral caudal lateral and ventral caudal medial nucleus of the thalamus have a lacy texture to the cytoplasm and it appears that there are fewer neurons than which should be observed in this area, however, holes are not found within this region.

Slide 7/Thalamus at the level of the pineal body - The corpus callosum is relatively normal. The pineal body appears to be normal. There is a mild diffuse gliosis in this region but extremely mild and really no evidence of holes. The central gray substance and ocular motor red nucleus are normal. There are just a few holes in the substantia nigra but they are considered minimal. The exit of the ocular motor nerves in this region are all within normal limits.

Slide 8/Hippocampus - This is probably more of the mid-region of the hippocampus, a longitudinal section. There is extensive loss of parietal cells and nearly a total loss of the granular cell layer. There is a moderate degree of neovascularization and gliosis with lymphocytic cuffing within this region. Numerous eosinophilic globs which is the remnant of neurons are present throughout this region. These numerous structures of necrotic neurons are not surrounded by neurophagia. In summary, at least in this section, probably 75-80% of the neurons of the pyramidal and molecular cell layer are missing, but it is patchy, they are small segments in which there is a relatively normal population of parietal cells. The adjacent tissue composed primarily of white matter tracts shows a few holes but not a significant number.

Slide 9/Hippocampus - This is a similar section of hippocampus just a slight degree deeper and the same lesions are found. In this section many of the neurons of the pyramidal cell layer are missing and the molecular cell layer is not discernible. Numerous small foci of remnants of neurons are present. Gliosis is present throughout but neuronal phagia is not a prominent feature. In this region probably 20-30% of the neurons of the pyramidal cell layer are missing. Lymphoplasmacytic cuffing is present throughout the hippocampus in this region. Gliosis and

perivascular cuffing is also found within the amygdaloid nuclear complex in this region.

Slide 10/Brainstem at the level of superior colliculus and pons - The cerebellum in this region does contain numerous Purkinje cells that appear to be characterized by central chromatolysis. Many of the Purkinje cells are affected with this change and there appears to be necrosis or at least loss of Purkinje cells in a few areas. The molecular and the granular cell layers appear to be relatively normal. A slightly increased number of lymphocytes and plasma cells can be found within the meninges over the cerebellum and the medullary belum. There is also a small structure at the edge of the medullary belum that contains an amphophilic ground substance with perhaps extremely small basophilic bodies. This may be a single protozoan cyst. However, there does not appear to be wall around this structure and there is no inflammation. So if this is truly a cyst it would be more of the pseudocyst-like structure suggestive of toxoplasmosis. However, this may be just an unusual large degenerated neuron. The tegmental nucleus is normal. The interpeduncular nucleus is also without lesions. A few holes are found within the pontene nuclear area but they are minimal. Essentially the pontene area is within normal limits.

Cerebrum at the level of the parietal lobe - There are a few extra lymphocytes and plasma cells within the meninges and a mild diffuse gliosis within the cortical gray but neuronal loss is not evident. A few extra holes are found in the white matter but not significantly so. However, there does appear to be a mild diffuse gliosis within the white matter tracts.

Cerebellum with root nuclei - Many of the Purkinje cells have undergone central chromolysis and a few eosinophilic neurons can be found. The molecular and granular layers and white matter tracts are within normal limits in this section.

Brainstem at the posterior aspect of the medullary belum and beginning of olive nuclei - No significant lesions (NSL).

Slide 13/Trigeminal ganglion and nerve - NSL.

Obex - A section of obex is within normal limits (WNL) including hypoglossal nucleus, parasympathetic nucleus of vagus nerve, cuniate nucleus, nucleus of the spinal tract of the trigeminal nerve, and olive nuclei - All of the white matter tracts in this

region also are relatively normal.

Slide 14/Liver - There are several focal areas of inflammation in the liver characterized by necrosis with hypertrophy Kupffer cells, macrophages, eosinophils, lymphocytes, and plasma cells. These small focal areas of hepatitis are most likely associated with parasitic activity. Hepatocytes are slightly atrophied and there is a mild retention of bile within biliary caniculi suggesting that this animal may not have eaten for the last week.

Skeletal muscle - NSL.

Heart - This section of heart does contain a mild infiltration of inflammatory cells within the epicardium. There are a few focal areas of lymphocytic infiltration within the myocardial interstitial tissues. There is perhaps a few small areas in which there is holes between the myocardial cells probably remnants of areas of edema within the T system of the heart. There are also a few areas where there is an increased number of cells with collapse of myocardial cells perhaps these are small areas of early fibrosis.

Small intestine - NSL.

Pancreas - NSL.

Lung - There is a mild multifocal accumulation of lymphocytes and plasma cells scattered throughout the section of lung both within alveolar spaces and within alveolar walls. Occasionally these areas of inflammation are associated with cross sections of parasites. These parasites are compatible in size and shape with parafilaroides. The remaining lung is collapsed and within normal limits.

Adrenal gland - NSL.

Thyroid gland - Follicles are of normal size and shape.

Skeletal muscle - NSL.

Spleen - The follicular lymphoid tissue is mildly depleted.

Mesenteric lymph node - This lymph node is relatively active and within normal limits.

Tonsil - The overall size of the tonsil is small but the few follicles that are present are considered to be normal. There are two small cysts within the tonsil which are actually cysts of the tonsilar crypts. The surrounding salivary tissue is within normal limits, however, some of the ducts appear to be atelactatic in this specific section.

Small intestines - NSL.

Kidney - This section of kidney does contain a large cyst within the medullary region. Otherwise there are few vessels that are surrounded by a few lymphocytes within the kidney but it is relatively minimal.

Urinary bladder - NSL.

Esophagus - NSL.

Gallbladder - There is extensive destruction of villi of gallbladder with a severe infiltration of lymphocytes and plasma cells within the lamina propria. There is also what appears to be increased fibrosis of the wall. These lesions are most likely associated with a heavy infestation of liver flukes.

Slide 18/Spinal cord - This section of spinal cord and spinal nerves are all within normal limits. The nodule within the subcutaneous tissues probably from the mammary gland, this small nodule is composed of numerous macrophages filled with small droplets of a clear to yellow staining oil-like material present within the cytoplasm of these macrophages. This section is thought to be of mammary gland in which the glands are totally inactive. This yellow material may be inspissated mammary gland secretions. No inflammation other than these macrophages are present.

Lymph node, probably a peripheral node - This lymph node is active and considered to be within normal limits.

Esophagus - NSL.

Vibrissa - The nerves of the vibrissa are within normal limits. The skin around the vibrissa are also normal.

Esophagus - NSL.

Slide 20/Ovary - One section of ovary does contain a degenerating corpus luteum and the other a corpus albicans. One section of uterus is fairly inactive whereas the other section does show many of the glands to be dilated and filled with cellular debris. This animal may have had a pup 3-4 months ago and had to abort it.

Terry R. Spraker, DVM/PhD

Typed: 06-18-98 em, 6-22-98 em

COLORADO VETERINARY DIAGNOSTIC LABORATORY
College of Veterinary Medicine and Biomedical Sciences
Colorado State University, Fort Collins, CO 80523
Phone 970-491-1281 Fax 970-491-0320

DL#: 978-39397
Date: 6/98

Vet/Clinic: Francis Gulland/Marine Mammal Center
Owner: Marine Mammal Center
Animal ID: CSL 3747/Iiona #13199 **Date Specimen Taken:** 6-2-98
Species: Z. californianus **Breed:** CSL **Age:** A **Sex:** F

History: This animal was found stranded on 5-22-98 and was admitted on that same day to the Marine Mammal Center. The animal continually had convulsions and was euthanatized on 6-2-98.

DIAGNOSIS: 1/Neuronal necrosis and loss, severe, hippocampus and amydaloid nuclear complex, with moderate cortical edema of the rhinencephalon, brain.

2/Multifocal moderate degeneration of myocardium.

3/Pneumonia, multifocal, chronic active, lung, associated with parafilaroides.

4/Bile duct hyperplasia, bile, associated with flukes.

COMMENTS: The lesions found in this animal are consistent with the lesions found in the other California Sea Lions with a suspected domoic acid toxicity. Lesions in this animal are healing but nevertheless, show extensive neuronal loss within the hippocampus.

GROSS NECROPSY: This animal is pregnant in the left uterus and there is severe edema within the body of the uterus. There is a 9cm rupture at the base of the right horn and the fetus has been delivered into the abdominal cavity. The placenta is dark, hemorrhagic and congested. The right ovary is small and inactive, and the left ovary has a large CL/seal. There is 7 volcanic ulcers of the stomach. The animal is in fair body condition.

HISTOPATHOLOGY: 1/Rhinencephalon with olfactory stria - There is extensive lymphoid cuffing and mild gliosis with holes throughout the neuropil of the nuclei of the olfactory stria. There is extensive accumulation of holes in the gray matter of the cortex of the rhinencephalon. These holes appear to be within astrocytes and around the periphery of neurons. There is also a mild degree of neuronal loss within this area, and some neurons appear to be undergoing later stages of degeneration. There are a few extra holes in the white matter in this region, suggesting intramyelinic edema. An occasional eosinophilic and necrotic neuron can be found in this region.

2/Caudate nucleus - This section is relatively normal. Septal nuclei are normal. Optic chiasm is normal. A mild degree of infiltration of lymphocytes are present within the meninges in this area. Internal capsule has a few holes suggesting previous intramyelinic edema, likewise, the corpus callosum.

3/Hippocampus/level of hypothalamus/optic chiasm - The optic chiasm is normal. Nuclei of the hypothalamus are within normal limits.

Tail of caudate nucleus, internal capsule - The medial dorsal nucleus of the thalamus does have a moderate degree of gliosis, a few holes, and a few structures that may be necrotic neurons. The anterior medial thalamic nucleus is relatively normal.

4/Mid-thalamus - The optic tract in this region is normal. There is a moderate degree of lymphoid cuffing and gliosis within the amygdaloid nuclear complex. Holes throughout this area and a few necrotic neurons are observed. A mild degree of neovascularization is also present in this slide, and one small area of early malacia is beginning to form with gitter cells. Gliosis is both diffuse and focal.

5/Thalamus/mid-level - In this region, the amygdaloid nuclear complex has undergone severe malacia with severe lymphoid cuffing, gliosis, and neuronal loss. The mamillary body in this region is considered normal. Habenular nucleus is normal. Some of the neurons of the ventral caudal lateral and ventral caudal medial nuclei are undergoing central chromolysis and there are a few axons that have undergone mild intramyelinic edema, but overall, the lesions in this animal are considered extremely mild.

6/Thalamus/lateral anterior nucleus/medial dorsal nucleus with corporus colosum/cerebral cortex - All of these sections are relatively normal.

Thalamus/level of pineal body - The cingulate gyrus is relatively normal. Corporus colosum and fornix of hippocampus are normal. Pineal body is normal. Central gray substance and ocular motor nucleus are within normal limits. Red nucleus and substantia nigra are normal. Posterior aspect of the thalamic nuclei are normal. Optic radiation in the pulvinar nucleus of thalamus are within normal limits. Ocular motor nerve is within normal limits.

Brain stem/level of superior colliculus/pons/cerebellum - All levels are normal including tegmental nucleus, interpeduncular nucleus, pontine nuclei and fibers are within normal limits. The Purkinje cells often have undergone central chromolysis but the molecular and granular layers are within normal limits. The white matter tracts of the cerebellum are also normal.

9/Cerebellum/roof nuclei - The Purkinje cells also show central chromotolysis but the other regions in this section of cerebellum are within normal limits.

Obex - The hypoglossal and dorsal vagus nucleus and olive nuclei are all within normal limits. There are a few small holes which is perhaps edema within or around the medial cuneate nucleus.

10/This is a section of hippocampus and dentate gyrus. The majority of the neurons of the pyramidal cell and within the molecular cell layer are all gone. There is a severe diffuse gliosis throughout this area and numerous small focal areas of degenerated neurons with neuronal dropout. In one area within the molecular cell layer, eosinophilic neurons can still be discerned. Lymphoplasmacytic cuffing is also present throughout this area.

11/Pituitary gland - No significant lesions (NSL).

Spinal cord - Section is from C1 or C2 and its within normal limits. The spinal nerves are also normal.

Trigeminal ganglion - NSL.

Adrenal gland - NSL.

Heart - There are a few small focal areas of edema and what appears to have been early myocardial degeneration and neurofibrosis. These are especially prevalent in the papillary muscle of the left ventricle. These are also especially prevalent in the septal muscle near the large left coronary artery and vein.

Lungs - This section of lungs is relatively collapsed but has a few small focal areas of chronic active pneumonia associated with parafilaroides. One adult parasite and several larvae are found within this section of lung.

14/Stomach - This section does contain a large volcanic ulcer that penetrates into the superficial submucosa. This ulcer is surrounded by extensive inflammation composed primarily of lymphocytes, plasma cells, and a few macrophages and neutrophils. Numerous bacteria and cross-sections of nematodes are present on the surface of this ulcer.

Small intestines - Several sections are examined and all are within normal limits.

Bladder - NSL.

Gall bladder - This section of gall bladder has a moderate degree of disruption of the villi with an extensive infiltration of lymphocytes and plasma cells. Numerous crypts are somewhat cystic.

Tonsil - The lymphoid tissue of the tonsil is relatively minimal and a few large cysts within the crypts are present. The follicles are within normal limits, but there just appear to be a few of them as if the tonsil has undergone atrophy.

Kidneys - NSL.

16/Bile ducts - These bile ducts are moderately hyperplasia and are infiltrated with a moderate number of lymphocytes and plasma cells. Several cross-sections of large flukes are present within this region. The surrounding liver tissue is characterized by hepatocytes that are slightly atrophied.

Small intestines - This section is within normal limits.

Colon - This section is normal.

17/Lymph node - This is probably mesenteric lymph nodes. These lymph nodes are within normal limits.

Skeletal muscle - NSL.

18/Pancreas - NSL.

Spleen - The lymphoid tissue is somewhat depleted and the red pulp is collapsed. There is one large splenic scar in this area with siderotic formation.

Fibrissi - NSL. The nerve and skin of this structure are all within normal limits.

Cervix - This section is extremely edematous and there is a mild infiltration of inflammatory cells within the edematous area.

Ovary - One section of ovary does contain a degenerating corporus albicans and the other ovary is relatively normal. The placenta is markedly congested and has undergone extensive autolysis. This is due to circulation failure following delivery of pup and placenta into the abdominal cavity.

Terry Spraker, DVM/PhD

Typed: 6-18-98 ml
-22-98 ml

COLORADO VETERINARY DIAGNOSTIC LABORATORY
College of Veterinary Medicine and Biomedical Sciences
Colorado State University, Fort Collins, CO 80523
Phone 970-491-1281
Fax 970-491-0320

DL#: 978-38156
Date:

Vet/Clinic: Francis Gulland
Owner: The Marine Mammal Center
Animal ID: Sixteen CSL3748 **Date Specimen Taken:**
Species: Z. callifornias **Breed:** **Age:** Adult **Sex:** F

History: This is an adult female California sea lion number CSL3748. This animal was found on the beach and was in convulsions. The animal was found stranded on 5/22/98, brought into the clinic on 5/22/98 and died in the evening on 5/23/98. Summary of gross lesions include nematodes in the stomach, small tags of fibrin on the surface of the pericardium. The pericardium appears to be white, lymph nodes are slightly swollen. Bile is present in the esophagus. Tonsils were enlarged. Lungs were wet and heavy. There was approximately 30 ml of stomach contents.

DIAGNOSIS:
1. Neuronal necrosis, severe, hippocampus and mild in cerebral cortex, Purkinje cell layer and olivary nucleus with mild to moderate intramyelinic edema and edema of the neuropil of the brain.
2. Mild lymphoplasmacytic cuffing, vessels, hippocampus.
3. Severe myocardial edema with myocardial degeneration and necrosis, acute, heart.
4. Fibrinous deposition, epicardium, left ventricle, heart.
5. Hepatitis, mild, multifocal, liver most likely associated with parasitic activity.
6. Pneumonia, mild, multifocal, chronic active with edema, lung most likely associated with parasitic activity.

REMARKS: The primary lesions in this California sea lion include neuronal necrosis especially of the hippocampus and mild neuronal necrosis and edema of the neuropil of the amygdaloid nuclear complex, olivary nuclei reticular formation of the myelencephalon pontine nucleus, oculomotor nucleus, thalamus and the deep lamellar gray matter of the cerebral cortex. There is also extensive intramyelinic edema throughout the brain. There is mild lymphoplasmacytic cuffing of vessels especially of the hippocampal region. This animal so had severe interstitial edema within the myocardium with degeneration and necrosis of myocardial cells. This probably accounted for the fibrinous deposition on the surface of the epicardium. The mild edema and

pneumonia and hepatitis found in this animal are probably incidental findings and are associated with parasitic activity.

HISTOPATHOLOGY: Slide 1: Rhinencephalon, olfactory stria, caudate nucleus and septal nucleus: There is mild edema in the rhinencephalon cortex and mild gliosis in this region. The edema is more of a deep laminar cortical edema and an occasional neuron has undergone necrosis. The white matter in these regions also have intramyelinic edema.

Slide 2: Hypothalamus/thalamus: There is an extremely mild degree of edema in the neuropil of the nuclei of the thalamus and there are a few neurons that are undergoing acute necrosis and have eosinophilic cytoplasm. The overall lesion in the thalamus is relatively low. There is extensive intramyelinic edema in the internal capsule in this region and in some of the white matter tracts around the edges of the thalamus. A few axons within the optic tract are also affected with intramyelinic edema. Lesions are not found within the hypothalamus.

Slide 3: Brain stem at the level of the pineal body and oculomotor nerve rootlets: Pineal body is normal. An extremely mild degree of lymphocytic cuffing is found around just a few of the vessels in this region. There is a moderate degree of edema in some of the large white matter tracts in this area of the brain stem. An occasional neuron is found that has undergone necrosis but only several. An extremely mild degree of edema of the neuropil is found within the oculomotor nucleus and the central gray substance is also considered normal except for a few of the VR spaces are slightly dilated.

Slide 4: Brain stem at the level tegmental nucleus and pontine nuclei: There is an extremely small amount of edema with the pontine nucleus but many of the fibers through the pontine nucleus do show evidence of intramyelinic edema. Intramyelinic edema is also found in several of the white matter tracts in this region. Neuronal necrosis is not a feature in this region.
Slide 5: Cerebral cortex, parietal lobe, cerebellum with roof nuclei: There is a mild to moderate degree of intramyelinic edema of the white matter in this section of cortex. There is perhaps an extremely mild degree of gliosis but very little. The cortex in this region is considered to be within normal limits. The molecular layer of cerebellum appears to be normal. There are a few Purkinje cells that have undergone necrosis but edema is not prevalent in this layer in this animal. The

granular layer is relatively normal. There is a moderate amount of intramyelinic edema of the white matter tracts of the cerebellum in this region. Only a small portion of roof nuclei are present on this slide. Intramyelinic edema is present in this region, but neuronal necrosis is not observed.

Slide 6: Obex and spinal cord: In the obex region the hypoglossal nucleus, dorsal nucleus vagus and cuneate nucleus are all within normal limits. There is an extremely mild degree of edema within the olivary nucleus and an occasional necrotic neuron within this nucleus also. There is also a mild degree of intramyelinic edema within the reticularis nucleus and an occasional necrotic neuron in this region. The spinal cord is considered to be within normal limits.

Slide 7: This section contains hippocampus, portions of the head and tail, probably C-1 and C-4: The area of the crus fornicis is considered normal. The polymorphous layer of the hippocampus in both of these regions is relatively normal. There is only an occasional neuron within the pyramidal layer in both of these regions that show evidence of necrosis. There are several layers in the molecular cell layer that do show evidence of necrosis and there are also several areas of neuronal phagia. There is also a mild degree of gliosis in this area. There are also a few plasma cells within the VR spaces of the hippocampus in this region. There is a moderate degree of edema of the neuropil, astrocytosis/gliosis and neuronal necrosis within the amygdaloid nuclear complex.

Slide 8: Lung: Alveolar capillaries throughout the lung are markedly congested. A few of the bronchioles do contain cellular debris. Edema and a small degree of cellular debris can be found in some of the alveolar spaces. There are a few areas in which alveolar walls are thickened due to edema and mild inflammation of neutrophils. An occasional cross section of nematode, probably parafilaroides can be found throughout the lung. In some areas alveolar spaces are filled with edema. There are also a few areas in the lung where alveolar spaces do contain neutrophils. These are usually associated with neutrophilic infiltration of the alveolar walls and also probably associated with previous parasitic activity.

Slide 9: Thyroid: The follicles of the thyroid are relatively small and appear to be relatively active. No evidence of inflammation or degeneration however is observed in this gland. Heart: Several sections of heart are examined and the myocardial cells show extensive separation due to an interstitial edema. There are a few small areas of myocardial degeneration with an associated mild infiltration of inflammatory cells primarily a few neutrophils and a few

lymphocytes. Occasionally small areas of interstitial hemorrhage is also found. IN another area especially in the left ventricular papillary muscle there are a moderate number of myocardial cells that have undergone degeneration and necrosis. The Purkinje cells in this heart appear to be unaffected. It appears that the more severe lesions are found more within the endocardial areas of the heart especially in the papillary muscle of the left ventricle. The epicardium in one section is covered with an extensive amount of fibrin. No evidence of inflammation is present in this area.

Slide 10: Spleen: The lymphoid tissue of the spleen is slightly depleted but the red pulp is of normal cellularity.

Liver: There are several small focal areas of accumulation of inflammatory cells within the liver parenchyma. These are often associated with hepatic portal triad regions and are probably associated with parasitic activity. These areas are characterized by necrosis associated with an infiltration of neutrophils and macrophages with a few lymphocytes and plasma cells. In some areas there appears to be edema of the spaces of disc throughout the liver.

Slide 11: Adrenal gland: No significant lesions.

Lymph node: The origin of this node was not determined but the shape is suggestive of a mesenteric node. The lymphoid follicles are mildly depleted but otherwise within normal limits.

Right ventricle, heart: This section of right ventricle contains similar lesions as described earlier but to a much milder degree. The most severe lesions are also towards and within the endocardial area of this section of heart.

Slide 12: Kidney: There are a few small focal areas of lymphoid accumulation within the interstitial tissues of the cortex but these are relatively mild and probably incidental findings. The tubules and glomeruli are within normal limits.

Small intestines: This section of small intestines is within normal limits, however it has undergone fairly extensive autolysis.

Esophagus: There are areas in which the squamous epithelial cells of the esophagus has undergone severe autolysis and is somewhat focal. This may be associated with the presence of bile being in the esophagus which was described on the gross exam. The presence of bile in the esophagus may cause small areas of necrosis and perhaps even blisters in the esophagus as

observed in other cases. Sarcocysts are not found in the musculature of this animal.

Slide 13: Small intestines: This section of intestines has undergone autolysis within the mucosal layer. There is also evidence of edema perhaps necrosis of the smooth muscle within the wall of the small intestines and edema of myentery plexus. Because of the degree of autolysis it is difficult to discern whether this is a real lesion or not but is probably associated with autolysis.

Lymph node: Probably peripheral lymph node: This node is moderately depleted of lymphoid cells especially lymphoid follicles. However, the node is quiescent and considered to be normal. Another lymph node is present on this slide but it has undergone sever and advanced autolysis. This is most likely a mesenteric lymph node. No lesions are found in this node and this node does not contain any evidence of neoplasia.

Slide 14: Salivary gland: This is a section of submandibular salivary gland. No lesions are observed.

Lymph node: Abdominal lymph node: This node has numerous depleted follicles and has undergone severe autolysis. Vessels around this node are congested.

Tonsil: The lymphoid tissue of the tonsil is depleted and there is evidence of follicular necrosis. A number of follicles do contain lymphocyte necrosis are relatively extensive.

Slide 15: Uterus: This section of uterus is normal and this section did not contain a fetus.

Ovary: This section of ovary does contain developing follicles.

Slide 16: Slide 16 is of hippocampus and has areas of C-1 and C-4. That it is it has areas of the head and the tail of the hippocampus. In this section edema, mild diffuse gliosis and neuronal edema can be found in the amygdaloid nuclear complex area. A mild degree of lymphoid and plasmacytic cuffing can be found within the hippocampus and mild gliosis and an occasional plasma cells can be found within the neuropil especially the C-4 region. There is perhaps a mild degree of edema of the molecular cellular layer in this region. There is an occasional necrotic neuron within the pyramidal cell layer. There is a moderate degree of edema in some of the white matter tracts adjacent to the hippocampus in this region.

Slide 17: Slide 17 is from the mid region of the hippocampus. In this particular slide the majority of neurons and the pyramidal cell layer have undergone severe acute necrosis.

There is also an extensive degree of edema within the neuropil in this region within the stratum radiatum.

Cerebellum: This section of cerebellum is similar to the one previously described in which a few of the Purkinje cells are undergoing necrosis. The white matter tracts in this particular region are relatively normal. This section was taken from the periphery of one of the cerebellar lobes not near the roof nuclei.

Terry R. Spraker/DVM, PhD

Typed: 6/18/98 lm

Veterinary Medical Teaching Hospital
University of California, Davis

07Oct98 at 4:31pm.

PATHOLOGY BIOPSY
FINAL REPORT

CLINIC NO.:
SPECIES: OTHER SMALL ANIMAL
BREED: SEA LION
SEX: F **LIFESTAGE:** ADULT
TAG NO.: CSL #3749 (SHAMUS)
CLINICIAN: No Doctor #
OWNER: MARINE MAMMAL CNTR ATTN: EILEEN ECONOMY
ADDRESS: Golden Gate Nat'l Rec Area Bldg 1044
Sausalito, CA 94965

PATHOLOGY NO.: 98B 1288
DATE REQUESTED: MAY 26, 1998
RESIDENT: L.J. LOWENSTINE, DVM,PhD
PATHOLOGIST: L.J. LOWENSTINE, DVM,PhD

****

SPECIMEN: BIOPSY TISSUE **PRESERVATIVE:** FORMALIN **DATE REPORTED:** OCT 5, 1998

****

PATHOLOGIC DIAGNOSIS:

1) SEIZURES SECONDARY TO DOMOIC ACID EXPOSURE (CLINICAL DIAGNOSIS)
2) HEART: MULTIFOCAL ACUTE MYOCARDIAL NECROSIS ASSOCIATED WITH INDIVIDUAL FIBER LYSIS, VACUOLATION OR FRAGMENTATION, INTERSTITIAL EDEMA, AND MILD LYMPHOCYTIC AND NEUTROPHILIC MYOCARDITIS WITH INTRALESIONAL ORGANISMS (POSSIBLE SARCOCYSTIS) AND MYOFIBER LIPOFUSCINOSIS
3) BRAIN, HIPPOCAMPUS: MODERATE TO MARKED VACUOLATION OF DENTATE GYRUS AND HIPPOCAMPAL SECTORS CA4 AND CA1 WITH RARE INDIVIDUAL NEURONAL NECROSIS IN CA1
4) BRAIN: MILD NONSUPPURATIVE CHOROIDITIS AND MENINGITIS
5) UTERUS: MILD ACUTE METRITIS AND ENDOMETRITIS WITH MODERATE ACUTE HEMORRHAGE
6) PLACENTA: MILD TO FOCALLY SEVERE ACUTE PLACENTAL NECROSIS WITH FIBRIN DEPOSITION, FOCAL THROMBOSIS AND INTRALESIONAL BACTERIA
7) TONSILS AND LYMPH NODES: LYMPHOID HYPERPLASIA WITH ACUTE GERMINAL CENTER LYMPHOLYSIS AND MARKED PLASMACYTOSIS
8) KIDNEYS: MILD LYMPHOCYTIC AND PLASMACYTIC PYELONEPHRITIS
9) LIVER: MILD MULTIFOCAL GRANULOMATOUS HEPATITIS (PARASITIC PRESUMPTIVE)
10) STOMACH: MILD LYMPHOCYTIC GASTRITIS WITH LAMINA PROPRIAL FIBROSIS (PARASITIC PRESUMPTIVE)
11) LUNG: MILD CHRONIC MULTIFOCAL LYMPHOCYTIC AND EOSINOPHILIC INTERSTITIAL PNEUMONIA (PARASITIC PRESUMPTIVE)
12) TERM FETUS, LUNGS: MARKED ASPIRATION OF AMNIOTIC SQUAMES AND INTERSTITIAL EDEMA
13) FETUS: MARKED AUTOLYSIS

CLINICAL ABSTRACT:

This is a California Sea Lion #3749 named Shamus. This animal is one of the "outbreak" of seizuring sea lions from San Luis Obispo County. She was stranded at Grand Avenue, Oceano Dunes in San Luis Obispo County. The strand date was 5/22/98. She was admitted to the Marine Mammal Center on that same day and died on 5/24/98. Postmortem was the same day at 4:00p.m. and was performed by DeGuise and Collin. This was a female with a standard length of 156cm, blubber depth

OCT 1998
DISTRIBUTED
TO
CLINICIAN

36mm, axillary girth 105cm, umbilical girth 87cm, and weight 107kg. Her somatic index is 6/7.

GROSS NECROPSY:

Postmortem findings included enlarged tonsils and pinpoint ulcers in the oral mucosa of the hard palate. There was 300ml of white frothy fluid in the stomach and hyperemia of the gastric mucosa. Superficially, on the tips of the rugae was brown discoloration. Five parasitic crateriform gastric ulcers 1-3cm in diameter were present. The gastric lymph node was enlarged and edematous on section with several foci of necrosis up to 2 x 3mm which were photographed. Mesenteric lymph nodes were edematous on cut section. The duodenum had several subserosal linear hemorrhages. There was no content in the small intestine. This was a gravid female containing a male fetus with a standard length of 75cm, blubber depth of 3mm, and which weighed 1kg. The fetus was mildly to moderately decomposed. In one area of the left ventricle, there was marbled pale myocardium surrounding a dark red area.

GROSS DESCRIPTION:

The specimen consists of multiple formalin-fixed tissues recognizable as: brain with portions of the left cerebral cortex removed and multiple sections from visceral organs including pieces of hallow viscous, uterus and placenta, multiple lymph nodes, liver, spleen, kidney, gall bladder. In a separate jar is submitted specimens from the fetus.

COMMENT:

This gravid adult female California Sea Lion suffered from seizures during an unusual mortality event that was due to harmful algael blooms with domoic acid production. There is marked vacuolation of the anterior ventral dentate gyrus but no overt neuronal necrosis. There are a few ischemic neurons in CA1, but these are probably secondary to the seizures. Myocardial regions are interesting in that in some areas they are peracute, consistent with duration of seizures, while in others there is a mixed inflammatory response suggestive of a duration of several days. In these later foci there are small organisms suggestive of protozoal tachyzoites. They were negative with immuno-staining for Toxoplasma and Sarcocystic neurona. (We do not have a stain for the sea lion sarcocystic and bradyzoites of sea lion Sarcocystis do not react with RS neurona immuno stain.)

The female had a term fetus which appeared to have died in utero. It suffered from in utero hypoxia as evidenced by distention of alveoli with amniotic squames, suggestive of reflex gasping. Fetal death may have arisen from premature placental separation or necrosis and maternal hypoxia during seizures. Bacteria and thrombi were present within the necrotic placenta, suggesting the possibility of an ascending infection.

la

Linda J. Lowenstine

L.J. LOWENSTINE, DVM, PhD

COLORADO VETERINARY DIAGNOSTIC LABORATORY
College of Veterinary Medicine and Biomedical Sciences
Colorado State University, Fort Collins, CO 80523
Phone 970-491-1281
Fax 970-491-0320

DL#: 978-38157
Date:

Vet/Clinic: Francis Gulland
Owner: The Marine Mammal Center
Animal ID: Twenty Six CSL3757 **Date Specimen Taken:**
Species: Z. callifornias **Breed:** **Age:** Adult **Sex:** F

History: This is an adult female California sea lion number CSL3757 that had repeated seizures. This animal was found stranded 5/23/98 and brought into the center on that day. It died that same day and was necropsied the following day. Primary gross lesions included hemorrhages on the placenta, enlarged purple tonsils, mild edema of the lung, the stomach contained swollen rugae and blood within the lumen. Mesenteric lymph nodes were enlarged. The liver had a reticulated pattern. Adrenals were slightly enlarged and had a pale myocardium.

DIAGNOSIS:
1. Neuronal necrosis, severe with edema of neuropil and intramyelinic edema, especially of the hippocampus, thalamus and brain stem, brain.
2. Myocardial degeneration with interstitial edema, moderate, left ventricle.
3. Pneumonia, multifocal, mild chronic active associated with parasitic activity, lung.
4. Hepatitis, multifocal, mild, subacute, liver compatible with parasitic activity.
5. Lymphoid necrosis, moderate, follicular areas, tonsil.
6. Focal encephalitis, thalamus, brain may be associated with protozoan infection of endothelial cells.
7. Gastritis, chronic active, stomach probably associated with parasitic activity.

REMARKS: The cause of death in this animal was most likely associated with the severe neuronal necrosis and edema especially of the hippocampus and amygdaloid nuclear complex. Mild neuronal necrosis and moderate neuropil edema was also found within the thalamus and menecephalon and myelencephalon. A few Purkinje cells were also found necrotic within the cerebellum. This animal also had myocardial degeneration and interstitial cell edema. The mild multifocal pneumonia and hepatitis were incidental findings and probably associated with the parasites. The lymphoid necrosis of the tonsil may be

associated with acute severe stress. The gastritis is also most likely associated with chronic parasitism.

HISTOPATHOLOGY: Slide 1: Brain at the level of the optic chiasm and hypothalamus. The caudate nucleus in this region is normal. The hypothalamic nuclei and anterior thalamic nuclei are considered to be within normal limits. Intramyelinic edema can be found within the white matter tracts of the anterior portion of the internal capsule in this region. The olfactory stria and nuclear cortex are within normal limits. The optic chiasm is normal in this region.

Slide 2: This section is of the posterior hypothalamus and mid region of thalamus. There is an area of extensive lymphoplasmacytic cuffing of vessels within what appears to be ventral rostral nucleus of the thalamus. In this region several vessels are cuffed by a wide zone of lymphocytes, plasma cells with a few macrophages. There is also gliosis within the neuropil and mild edema within this region. Intranuclear inclusion bodies were not found in any of the neurons or glial cells in this region, nor were any organisms such as protozoa. Nuclei of the hypothalamus in this region are normal. In other areas of the thalamus, especially the more dorsal regions of the ventral rostral nucleus of the thalamus and of the medial dorsal nucleus of the thalamus there is an extensive amount of edema of the neuropil and an occasional necrotic neuron. These neurons have small shrunken nuclei and are surrounded by an extensive amount of brightly eosinophilic cytoplasm. Choroid plexus of this region is within normal limits. The white matter forming the commissure of the fornices of the hippocampus are normal in this region. A few axons within the corpus callosum do show evidence of intramyelinic edema. The fibers of the internal capsule show evidence of intramyelinic edema. There is a focal area within the ventral rostral nucleus of the thalamus that contain several vessels that are cuffed with a thick zone of lymphocytes, plasma cells and a few macrophages. There is also gliosis and astrocytosis in this region of encephalitis. Occasionally a neuron appears to be undergoing early degeneration in this area. In one of the vessels that has the thickest coat of lymphocytes and plasma cells. There appears to be endothelial cells of this vessel that are all swollen and there is one cell in particular that has four or five small basophilic dots within the cytoplasm that may be a protozoan such as a sarcocyst, however there are no well formed protozoan cysts in this region of localized encephalitis. The amygdaloid nuclear complex is characterized by severe edema with neuronal necrosis. In certain areas the degree of neuronal necrosis is extensive in this area. The corpus callosum in this area shows evidence of intramyelinic edema. The habenular nucleus is

within normal limits, however the habenular tract does contain evidence of intramyelinic edema. There is mild edema of the ventral caudal lateral and ventral caudal medial nuclei of the thalamus and there is intramyelinic edema in this region and there are a noticeable number of necrotic neurons especially within the ventral caudal medial nucleus.

Slide 4: Thalamus/mamillary body: The cingulate gyrus is within normal limits in this region. The corpus callosum contains intramyelinic edema. The fornices of the hippocampus in this area is normal. The pulvinar of the thalamus in this region and lateral nuclear area of the thalamus are relatively normal. A moderate degree of edema and intramyelinic edema is present within the ventral caudal lateral and to some degree in the ventral caudal medial nucleus of the thalamus. There is also one small focus of hemorrhage in the ventral caudal lateral nucleus of the thalamus. Neuronal necrosis is not found in this section of the ventral caudal lateral and ventral caudal medial nuclei of the thalamus on this slide. However there does appear to be chromatolysis and loss of Nissl substance with some of the neurons in this region. A small section of the tail are probably C-4 of the hippocampus is present within this section. Numerous neurons have undergone acute necrosis within the pyramidal cell layer. There is also an extensive degree of edema within the stratum radiatum. The mamillary body is within normal limits.

Slide 5: This section contains cerebral cortex, piriform lobe and a cross section through the mid region of the hippocampus. The extension of the optic tract in this area is normal. There does appear to be extensive edema within the piriform lobe n this area. Cerebral cortex in this region is within normal limits. Cross section through the hippocampus in this region shows extensive of neurons within the pyramidal cell layer and extensive edema within the stratum radiatum. One small area within the molecular layer also shows extensive neuronal necrosis. There is also fairly moderate edema within the piriform layer of this section of hippocampus.

Slide 6: Brain stem/pons: This superior cuniculi in this region are relatively normal. The central gray substance in this area including the oculomotor nucleus are also considered within normal limits. There is a mild degree of intramyelinic edema throughout the reticular formation. A mild degree of edema can be found in some of the fibers of the pons however neuronal necrosis is not observed in this region.

Slide 7: Obex and cerebellum: This section of cerebellum is characterized by the molecular cell layer that is relatively normal. There is an occasional Purkinje cell that has an eosinophilic cytoplasm and there may be a mild degree of edema

at the Purkinje cell layer. The granular cell layer is within normal limits. A mild to moderate degree of edema/intramyelinic edema is present within the white matter in this region. Edema is present within the roof nuclei of the cerebellum but neuronal necrosis is not observed.

Obex: There is a mild degree of intramyelinic edema in the rafi in this region but all of the nuclei of the obex region are within normal limits. There is an occasional axon with intramyelinic edema but the degree of edema in this region is relatively minor.

Slide 8: Left papillary muscle of ventricle and atrium: The large coronary vessel on this slide between the atrium and the ventricle is within normal limits. The atrium is considered normal and the atrial ventricle valve in this region is normal. The right ventricle is considered normal. There is a mild to moderate degree of edema within the interstitial tissues of the left ventricle. There are a few areas in which there is early myocardial cell degeneration. Occasionally there are a few neutrophils associated with degenerated myocardial fibers.

Slide 9: Lung: This section of lung does contain a few alveolar spaces that contain macrophages and neutrophils. In some areas alveolar walls are slightly thickened and also contain neutrophils, macrophages. Interlobular septae are slightly edematous and contain a few inflammatory cells. Alveolar capillaries are diffusely congested.

Placenta: There appears to be several areas of early infarction within the placenta. In these areas the vessels contain erythrocytes that have lost all of their hemoglobin and are pale. However, there is no evidence of necrosis or inflammation in these areas. Another section of placenta that contains extensive hemosiderin contains a few focal areas of inflammatory cells. This is probably a normal finding.

Slide 10: Spleen: Lymphoid tissue is severely depleted and the red pulp is collapsed but of normal cellularity.

Liver: There are a few focal areas of necrosis with lymphocytic and macrophage infiltration within the liver. These are randomly distributed throughout the liver and are most likely associated with parasitic activity. There appears to be a slightly extensive amount of connective tissue around bile ducts in this region suggesting parasitic infection of the bile ducts most likely by bile duct flukes. The remaining hepatocytes are within normal limits.

Stomach: This particular section of stomach does contain one small erosion that is characterized by necrosis of the superficial mucosal epithelial cells associated with an extremely mild degree of inflammation. Numerous bacteria are present on the surface of this erosion. These are most likely stressed induced gastric erosions.

Lymph node, probably peripheral or axillary: This lymph node is moderately depleted of follicular lymphocytes.

Duodenum: The duodenum has undergone moderate autolysis of the mucosa. Numerous large lymphoid follicles are present within the Burners' glands.

Esophagus: No significant lesions.

Liver: This section of liver is similar to what has previously been described.

Slide 12: Esophagus: No significant lesions.

Large intestines: The mucosa has undergone autolysis but otherwise these sections are within normal limits.

Pancreas: The pancreas has undergone mild autolysis but are within normal limits.

Gall bladder: The mucosa of the gall bladder has undergone severe autolysis.

Adrenal gland: No significant lesions.

Tonsil: The tonsil is markedly congested but the lymphoid follicles are normal in size, shape and activity. There is an extensive degree of necrosis of the majority of the Peyer's patches. The marked congestion of the tonsils is the cause of the enlargement and red discoloration observed on the gross exam. Epithelium covering the tonsil is within normal limits.

Urinary bladder: No significant lesions.

Stomach/pylorus: This region of the pylorus does contain an extensive degree of inflammation characterized by lymphocytes and plasma cells and a few neutrophils that have infiltrated into the lamina propria. An ulcer is not present in this particular slide however this inflammation is probably associated with parasitic gastritis.

Lungs: This section of lungs are similar to the one previously described.

Kidneys: Section of kidneys does contain several small focal areas of lymphocytes and plasma cells within interstitial tissues just underneath the capsule, but otherwise the glomerular tubules are within normal limits.

Small intestines: The mucosa has undergone advanced autolysis and the Peyer's patches have undergone severe lymphoid depletion.

Pituitary gland: No significant lesions.

Lymph node: The lymphoid tissue of this node is severely depleted. The lymph node is markedly congested which probably gave the red appearance observed on the gross exam.

Slide 15: Uterus: The uterus is within normal limits.

Aorta: Vessels of the adventitia of the aorta are congested but otherwise this section is considered normal.

Pancreas: No significant lesions.

Ovary: This section of ovary contains numerous small developing follicles.

Stomach: This section of stomach is within normal limits.

Slide 16: Slide 16 is of the hippocampus and this section contains a section of C-1 and C-4. The lesions are similar in both in which there is extensive necrosis of neurons of the pyramidal cell layer and the molecular cell layer and there is extensive edema within the stratum radiatum. There is extensive intramyelinic edema within the white matter tracts around the edges of the hippocampus. There is a section of lateral geniculate body within this section. There is mild edema in the lateral geniculate body but no real good evidence of neuronal necrosis. However, there are a few of the neurons that have undergone central chromolysis.

Slide 17: Slide 17 is identical to slide 16 but shows more of the middle portion of the hippocampus. This region also shows extensive necrosis of the pyramidal cell layer with severe edema of the stratum radiatum and extensive necrosis of the molecular cell layer. The section of cerebellum on this slide also shows mild intramyelinic edema within the white matter but the molecular and Purkinje and granular cell layer are within normal limits.

Terry R. Spraker/DVM, PhD

Typed: 6/18/98 lm

PATHOLOGY BIOPSY
FINAL REPORT

CLINIC NO.:
SPECIES: OTHER SMALL ANIMAL
BREED: SEA LION
SEX: F **LIFESTAGE:** ADULT
TAG NO.: CSL #3758
CLINICIAN: No Doctor #
OWNER: MARINE MAMMAL CNTR ATTN: EILEEN ECONOMY
ADDRESS: Golden Gate Nat'l Rec Area Bldg 1044
Sausalito, CA 94965
COMMENT: WEIGHT: 84 KG.

PATHOLOGY NO.: 98B 1289
DATE REQUESTED: MAY 26, 1998
RESIDENT: L.J. LOWENSTINE, DVM,PhD

****

SPECIMEN: BIOPSY TISSUE **PRESERVATIVE:** FORMALIN **DATE REPORTED:** NOV 20, 1998

****

PATHOLOGIC DIAGNOSIS:

1) SEIZURES SECONDARY TO DOMOIC ACID INTOXICATION (CLINICAL DIAGNOSIS)
2) BRAIN: MARKED SYMMETRICAL VACUOLATION OF PYRAMIDAL CELL LAYER AND NEUROPIL (ESPECIALLY STRATUM RADIATUM) IN VENTRAL ANTERIOR HIPPOCAMPUS
3) BRAIN: NEURONAL DROP OUT, DENTATE GYRUS ON RIGHT SIDE
4) BRAIN: MILD, ACUTE NEURONAL NECROSIS OF HIPPOCAMPAL SECTORS CA3 AND CA1
5) LUNG: MULTIFOCAL GRANULOMATOUS BRONCHITIS WITH INTRALESIONAL FOREIGN MATERIAL
6) LUNG: MILD, MULTIFOCAL, LYMPHOCYTIC AND EOSINOPHILIC, INTERSTITIAL PNEUMONIA, PRESUMED PARASITIC
7) LUNG: MILD PULMONARY NEMATODIASIS, PARAFILAROIDES PRESUMPTIVE
8) LUNG: MARKED, DIFFUSE CONGESTION
9) INGUINAL LYMPH NODE: METASTATIC CARCINOMA
10) LIVER: MARKED HEPATIC TREMATODIASIS WITH MULTIFOCAL TO REGIONALLY EXTENSIVE PERIPORTAL TO BRIDGING FIBROSIS AND CHOLEDOCHITIS WITH INTRALESIONAL TREMATODE, ZALOPHATREMA HEPATICUM PRESUMPTIVE
11) LIVER: MILD, MULTIFOCAL, GRANULOMATOUS HEPATITIS, PARASITIC PRESUMPTIVE
12) STOMACH: MULTIFOCAL ULCERATIVE AND TRANSMURAL GASTRITIS WITH INTRALESIONAL PLEOMORPHIC BACTERIA AND LUMINAL ANISAKID NEMATODES
13) LYMPH NODES: REACTIVE HYPERPLASIA, PLASMACYTOSIS AND INTRALESIONAL PIGMENT (PRESUMED FLUKE PIGMENT - DRAINAGE REACTION IN HEPATIC LYMPH NODE)

CLINICAL ABSTRACT:

This adult female California Sea Lion was presented dead on arrival to the Marine Mammal Center on 5/23/98. She had been found stranded at Shell Beach in San Luis Obispo County earlier in that day. Postmortem exam was performed approximately 22 hours postmortem by Dr. Francis Gulland. The animal weighed 84 kg, had a standard length of 160 cm, axillary girth of 104 cm, umbilical girth of 88 cm and a blubber depth of 33 mm. She had a somatic index of 5/7. At gross postmortem, Dr. Gulland found that the stomach contained blood tinged mucus and

NOV 1998
DISTRIBUTED
TO
CLINICIAN

the rugae were swollen and ulcerated with multiple erosions 1-3 mm diameter. The intestines were empty with petechial hemorrhages on the mucosa. The colon and rectum contained hard dry feces. There were about ten Anisakids in the stomach. The gallbladder was empty and the spleen contracted. Bile ducts and liver contained multiple Zalophatrema. The uterus was small and the ovaries were smooth and mammary glands not developed. Inguinal lymph node was enlarged and abscessed. The mesenteric and gastric hepatic lymph nodes were enlarged, hemorrhagic and edematous with foci of necrosis. There were a few pinpoint ulcers and erosions in the oral mucosa of the palate. The lungs were red and serous fluid oozed from cut surface. The heart was pale on the epicardial and cut surface of the left ventricle.

GROSS DESCRIPTION:

The specimen consist of brain minus cerebellum, brainstem and left occipital hemisphere. One section of trachea, two spleen, three heart, one tongue, one pancreas, gallbladder, three liver one with fluke and bile duct, one spleen, nine lymph nodes some with thick nodular cortex, a section of diaphragm, two sections of kidney, one section of salivary gland, two sections of ovary, one section of uterus, two thyroids, one adrenal, one pituitary, two pieces of lung and fourteen pieces of hollow viscous.

HISTOPATHOLOGICAL SUMMARY:

The following tissues were examined microscopically: (T1) lung X2; (T2) kidney X2, spleen; (T3) heart X4; (T4) liver, gallbladder; (T5) thyroids, adrenal, pituitary; (T6) multiple sections of stomach; (T7) tongue, uterus, pancreas; (T8) liver; (T9) multiple lymph nodes; (T10) trachea, gallbladder, small intestine, colon, esophagus, bladder; (T11) right brain through hippocampus; (T12) left brain, ventral hippocampus.

COMMENT:

The postmortem interval of 24 hours makes it difficult to interpret vacuolar changes in the brain. However, the pattern of vacuolation particularly the microvesicular vacuolation present in the neuropil of the hippocampus and stratum radiatum is similar to that which has been seen in other animals dying during this unusual mortality event. There is minimal active neuronal necrosis in hippocampus but unilateral loss of neurons in the section from the right hippocampus. Limited sections of the brain were examined due to cost restraints.

msl

Linda J. Lowenstine

L.J. LOWENSTINE, DVM,PhD

COLORADO VETERINARY DIAGNOSTIC LABORATORY
College of Veterinary Medicine and Biomedical Sciences
Colorado State University, Fort Collins, CO 80523
Phone 970-491-1281 Fax 970-491-0320

DL#: 978-39396
Date: 6/98

Vet/Clinic: Francis Gulland/Marine Mammal Ctr
Owner: Marine Mammal Center
Animal ID: #3760 Oatmeal/#13125 **Date Specimen Taken:** 6-2-98
Species: CSL **Breed:** Sea Lion **Age:** A **Sex:** F

History: Seizuring.

DIAGNOSIS: 1/Mild necrosis of Purkinje cells, cerebellum.

2/Edema, mild, cuneate nucleus, brain stem.

3/Very mild necrosis with mild intramyelinic edema and mild gliosis, hippocampus, brain.

4/Myocardial degeneration, mild, multifocal, heart.

5/Pneumonia, minimal, multifocal, chronic active, lung, associated with parafilaroides.

6/Teratoma, of skin, located on surface of right kidney.

7/Ovarian cyst, ovary.

8/Scar with acanthosis, pseudoepitheliomatous hyperplasia and orthokeratotic hyperkeratosis, skin of back.

COMMENTS: There are only minimal lesions in the brain that suggest that this animal may have died from domoic acid toxicity. Only minimal lesions are found in the brain and the heart that are compatible with domoic acid toxicity. The other lesions found in this animal are relatively common, including the pneumonia and the mild multifocal hepatitis, both of these lesions are consistent with parasitic activity. The cystic mass lined by squamous epithelial cells with adnexea found within the abdominal cavity may be a teratoma composed primarily of epidermal components. The ovarian cyst is an incidental finding. The lesion on the back is most likely the result of an old scar and does not communicate at all with the mass found near the right kidney.

GROSS NECROPSY: This animal was found on 5-24-98 and was brought into the Marine Mammal Center for seizuring. The animal somewhat stabilized but then began to have more seizures and was euthanatized on 6-2-98. Therefore, was at least nine days post-exposure to a potential toxin.

Gross lesions include a 5x3cm area of alopecia on the back. This animal is pregnant and has a large term fetus. A large CL is present on the left ovary. There is a fluid-filled cyst on the right ovary. There is one small, 3-4cm white plaque on the chorionic surface. This bile duct flukes are present. The stomach has four large gastric ulcers.

HISTOPATHOLOGY: 1/Olfactory stria with rhinencephalon - There are a few holes in the nuclei of the olfactory stria but very few lesions are found. The rhinencephalon in this area is within normal limits. The head of the caudate nucleus on this slide is within normal limits. There is one small focus of gliosis within the posterior aspect of the olfactory stria. This is probably in the nucleus accumbens septi.

2/Caudate nucleus - The corpus callosum in this area has a few axons that have undergone intramyelinic edema. The septal nucleus is within normal limits. The anterior tip of a hypothalamus is normal. The optic chiasm is normal. A moderate number of vessels and a few holes suggesting neuronal dropout are found in the nucleus accumbens septi, but this lesion is relatively mild this region. Caudate nucleus and internal capsule are within normal limits.

3/Hypothalamus - This section is relatively normal. Thalamic adhesion in the mediodorsal nucleus of the thalamus in this region is within normal limits. Optic tract is normal. Basoganglia of this region is relatively normal. The most anterior section of the piriform lobe in this area does have a few vessels that are cuffed by lymphocytes and a few small focal areas of gliosis. Basal nuclei are within normal limits.

Posterior aspect of thalamus at the level of the ventral caudal lateral and ventral caudal medial nuclei of thalamus - This section is relatively normal. The nuclei of the ventral caudal lateral and ventral caudal medial nuclei are relatively intact and show little evidence of edema or of a typical lacy degeneration of the cytoplasm observed in other cases. Other nuclei of the thalamus are within normal limits. A small section of hippocampus, probably part of the tail, is found in this

slide. This also may be part of the dentate gyrus. There is a mild degree of gliosis within this region but there appears to be a normal number of large pyramidal cells, however, there are a few holes scattered throughout and these holes are probably associated with neuronal dropout. Eosinophilic neurons are not observed, however, a few areas of gliosis are found in this specific section. A slightly increased number of lymphocytes are found within the choroid plexus and an extremely mild degree of edema is found within the internal capsule. The basoganglia in this region are within normal limits.

5/Thalamus/level of the hippocampus/habenular nucleus - The nuclei of the habenular mamillary tract are within normal limits. Thalamic nuclei in this region are relatively normal. At this level of hippocampus, the parietal cell layer and molecular cell layer are easily definable, and contain numerous neurons, however, there is a mild degree of gliosis in this layer and a mild degree of edema in one segment. The adjacent amygdaloid area is relatively normal, except for a mild increased number of lymphocytes and plasma cells around vessels, both of the hippocampus and of the amygdaloid area.

6/Thalamus/level of the pineal body and intrapeduncular nucleus/ hippocampus - The pineal body and superior canaliculus are within normal limits. Central gray substance and ocular motor nucleus is within normal limits. Intrapeduncular nucleus is slightly congested but other than that, is within normal limits. The white matter tracts within this region are also within normal limits. In this region of hippocampus, which is probably within the middle of the organ, it appears to have a loss of parietal cells and cells within the molecular cell layer, however, there is only mild gliosis and very few holes. Eosinophilic neurons are not observed, however, there is a moderate degree of lymphocytic cuffing in the hippocampal parenchyma. There is also a mild degree of edema within the neuropil, especially within the dentate gyrus and within the neuropil of the parameter cell layer.

8/Hippocampus with the lateral geniculate body - The fornix of the hippocampus is within normal limits. There appears to be a loss of neurons and mild edema within the pyramidal cell layer, but these lesions are extremely mild. Molecular cell layer also appears to have loss of neurons but holes are not present and evidence of neuronal loss is not present. The structure appears to be organized but does appear to have an overall loss of neural elements. There is a moderate degree of lymphoplasmacytic

cuffing of vessels within the hippocampus. The white matter tracts adjacent to the hippocampus are within normal limits. There appears to be a mild degree of edema and central chromolysis of neurons of the lateral geniculate body but neuronal necrosis and neuronal dropout are not observed.

9/Cerebrum at level of parietal lobe - The corporus colosum and white matter in this region is within normal limits. The lateral geniculate body with optic radiations are within normal limits. There is a mild diffuse gliosis of the cerebellar gray matter in this region, but neuronal loss is not observed.

Brain stem/level of fascial nerve - The stipular nuclei in this region are within normal limits. The fascial nerve and other nerve fiber tracts in this region are within normal limits.

The anterior aspect of the pons is within normal limits.

10/Cerebellum - The molecular and granular cell layer and white matter tracts are within normal limits. A few Purkinje cells have undergone necrosis and occasionally intraneuronal vacuolation of the cytoplasm of Purkinje cells is observed. After further study, there is actually quite a few Purkinje cells that have undergone necrosis and a moderate number of them do have vacuolated cytoplasm.

Obex region - This section of obex is characterized by normal dorsal vagus nucleus and hypoglossal nucleus and olive nuclei. The nucleus of the spinus tract of the trigeminal nerve and the amygdala nucleus are all within normal limits. There are a few holes that appear to be small lakes of edema within the cuneate nucleus.

11/Heart - There are multifocal areas in which there is an increased number of lymphocytes within the interstitial tissues of the heart. There are also multifocal areas in which the myocardium appears to have undergone mild degeneration and edema. These areas appear to be small multifocal areas of myocardial degeneration with early attempts at regeneration or fibroplasia.

12/Lung - There are multifocal areas of the lung that are characterized by lymphocytes, plasma cells, macrophages, and a few neutrophils present, both within alveolar walls, alveolar spaces, and in terminal bronchioles. Occasionally, both larval stages and small mature nematodes compatible in size and shape with parafillaroides are found, both within terminal bronchioles

and alveolar ducts and spaces. The overall burden of parasites in this section is relatively low.

13/There are just a few small focal accumulations of lymphocytes within the interstitial tissues. This is probably close to being within normal limits.

Liver - There are a few small focal areas of necrosis associated with lymphocytes and plasma cells. These are random distributed and are probably associated with parasitic activity. The hepatocytes are slightly atrophied which is probably associated with fasting for the last week. Bile ducts within this section are relatively normal.

14/Thyroid gland - Follicles are relatively normal.

Ileum - Lymphoid follicles are normal and this section is considered to be within normal limits.

Cecum - No significant lesions (NSL).

Adrenal gland - A few extra holes are found throughout the zona glomerulosa, however, this is a relatively common finding in adrenal glands of California Sea Lions that have been stressed. This lesion has been seen on numerous occasions with many different conditions in various aged animals and is considered a non-specific change, but is probably associated with stress. There is one small focus of mineralization within one of the nerve roots adjacent to the adrenal gland.

Small intestine - This section is within normal limits.

15/Bladder - NSL.

Mesenteric lymph node - This lymph node is relatively active and considered to be within normal limits. One small nodule contains a few macrophages, one multinucleate giant cell that appears to have engulfed larval stage of a parasite. These types of small granuloma are relatively common in mesenteric lymph nodes and this node has at least two of these small nodules.

Tonsil - The lymphoid tissue of the tonsil is considered to be normal. There are a few cystic areas of the tonsil that are associated with small cystic areas of crypts. This is a relatively common finding.

Lymph node - This is a pancreatic lymph node. Lymphoid tissue is active and within normal limits. There is a small amount of black pigment that is most likely associated with hepatic flukes present within sinusoids.

Pancreas - NSL.

16/Spinal cord/probably at level of C1/C2 - This section of spinal cord is within normal limits. Spinal nerves are also normal.

Skeletal muscle - NSL.

Trigeminal ganglion - Both the ganglion and the trigeminal nerve are within normal limits.

17/This section is from the mass found adjacent to the kidney. This mass is filled with degenerated keratin and is lined by a thin layer of squamous epithelial cells that vary from four to eight cells in thickness. Just under this epidermal layer appears to be a collagen layer of which also contains an occasional hair follicle and sebaceous and sweat glands. There is a mild degree of inflammation within some of these areas. There is evidence of hemorrhage with infiltration of numerous macrophages filled with hemosiderin within one area of this mass. In one area, the hemosiderin-laden macrophages are present on the inner lining of this cystic area.

18/Ovary - This section contains a few active follicles and a large corporus albicans with a large ovarian cyst. The cyst is lined by an extremely thin layer of cuboidal epithelial cells surrounded by mild connective tissue.

19/Stomach - This section is within normal limits.

Placenta - No specific lesions.

Spleen - The lymphoid follicles of the spleen are relatively normal, however, some are undergoing mild lymphoid depletion. There is a splenic scar in this region with siderotic plaque formation.

20/This section of skin was taken from the back of this animal that had a large area of alopecia. These sections of skin are characterized by extensive pseudoepitheliomatous hyperplasia and orthokeratotic hyperkeratosis of the epidermis. There is

extensive scarring of fibroplasia of the superficial dermis. Within the scar region, there is a loss of sebaceous glands, sweat glands, and hair follicles. There is only mild inflammation found around the edge of this lesion that is characterized by an infiltration of lymphocytes and plasma cells around some of the adnexi. There is no evidence of fungal bacterial, or any other type of parasitic infection in this area of scarring. The unusual change here is the severe hyperkeratosis, acanthosis, and pseudoepitheliomatous hyperplasia associated with scarring.

Terry Spraker, DVM/PhD

Typed: 6-18-98 ml

COLORADO VETERINARY DIAGNOSTIC LABORATORY
College of Veterinary Medicine and Biomedical Sciences
Colorado State University, Fort Collins, CO 80523
Phone 970-491-1281
Fax 970-491-0320
REVISED

DL#: 978-38158
Date: 5-29-98

Vet/Clinic: Dr. Francis Gulland
Owner: The Marine Mammal Center
Animal ID: 3765 **Date Specimen Taken:** 5-25-98
Species: Z. californianus **Breed:** **Age:** Adult **Sex:** F

History: This is an adult female California sea lion #CSL3765. This animal was found stranding on the beach and was brought into the rehab center.

DIAGNOSIS:
1. Severe edema of the neuropil and intramyelinic edema of the brain, especially white matter with moderate neuronal necrosis in the pyramidal and molecular cellular layer of the hippocampus, brain with a few intranuclear and intracytoplasmic eosinophilic inclusion bodies.
2. Ulcerative gastritis associated with parasites.
3. Multifocal chronic active pneumonia, lung, most likely associated with parasitic activity.
4. Hepatitis, mild multifocal, liver, associated with parasitic activity.
5. Focal lymphadenitis, necrotizing pelvic lymph node associated with a nematode.
6. Lymphoid necrosis, moderate, tonsil.
7. Lymphoid depletion, moderate, lymph nodes and spleen.

REMARKS: The primary problem in this animal is neuronal necrosis especially of the hippocampus and relatively wide spread brain edema. There is a little difficulty in this case because of the degree of autolysis but it appears that these lesions, the intramyelinic edema, and the edema of the neuropil is real and not just associated with autolysis. This animal was unusual in that it also had irregularly shaped oval to round eosinophilic intracytoplasmic and intranuclear inclusions. The etiology of these inclusions was not determined. Considerations would be 1) degenerated cytoplasm accumulation both within the cytoplasm and within internuclear blebs or perhaps a type of virus, however, the lesions or the inclusions in my estimation are more likely small necrosis or coagulation of cytoplasmic organelles and not

viral, however, further work should be done to confirm this suspicion.

GROSS NECROPSY: This is an animal in fair body condition that has gastric ulcers and a mottling coloration to the mesenteric lymph nodes. The uterus is enlarged suggesting that this animal did have a pup.

HISTOPATHOLOGY: Slide 1/Caudate nucleus and septal nuclei - This slide does show mild intramyelinic edema of some of the fibers of the internal capsule but lesions are not found within the corpus colosum or the caudate nucleus.

Slide 2/Hypothalamus/thalamus - The hypothalamus is within normal limits. There are a few axons within the olfactory tract that have mild intramyelinic edema. There is mild intramyelinic edema scattered throughout the thalamus and the internal capsule on this slide. There is an extensive accumulation of lymphocytes within the choroid plexus. The fornix of the hippocampus is normal in this section and the corpus colosum is within normal limits in this region.

Brainstem - At the level of superior colliculus, pineal body and exit of ocular motor nerve pineal bodies are within normal limits. A few small hemorrhages are present within the reticular formation in this region and some of the white matter tracks appear to be fairly wholly suggesting intramyelinic edema. The myelin sheaths of the large ocular motor nucleus in this region is normal.

Slide 4/Cerebrum and hippocampus - The cerebellar cortex is within normal limits, however, there appears to be a moderate amount of intramyelinic edema of the white matter tracks within this section. This section of hippocampus is taken from the tail or the C-4 region. The amygdaloid nuclear complex in this region does show evidence of edema and a few necrotic neurons, but the neurons are not eosinophilic. A mild degree of edema is present within the stratum radiatum and there is a mild degree of edema and a moderate number of neurons that are undergoing necrosis in the pyramidal cell layer and a few neurons are necrotic within the molecular cellular layer. Lesions in this area of the hippocampus are compatible with domoic acid but they are relatively subtle.

Slide 5/Cerebellum with root nuclei - There is extensive intramyelinic edema within the white matter tracts within the cerebellar follia and a moderate degree of edema within the neuropil of the root nuclei. An occasional nucleus within the root nuclei have undergone necrosis. The molecular Purkinje cell layer and granular cell layer of the cerebellum appear to be within normal limits in this section.

Slide 6/Brainstem at the level of the tagmental nucleus and pons - Intramyelinic edema is present within many of the white matter tracts in this region, however, the branch of the facial nerve exiting in this region is within normal limits. A few nuclei within the facial nucleus does show evidence of necrosis. Intramyelinic edema is present throughout this entire section especially in the axonal and nerve tracts.

Obex - The hippoglossal, vagus cuneate nucleus and nucleus of the spinal tract of the trigeminal nerve are all within normal limits. Olive nuclei contain a small amount of edema but neurons are considered to be within normal limits.

Slide 16/Hippocampus, more of the anterior part are C1 portion - This section does show moderate edema within the pyramidal cell layer and moderate edema within the stratum radiatum. A moderate numbers of neurons have undergone acute necrosis within the pyramidal cell layer and within the molecular cell layer in this region. There are a moderate number of large eosinophilic intranuclear inclusion-like bodies within neurons in this section, however, these appear to be swollen nucleoli. Usually the inclusions are single but in several cells multiple inclusions are observed. These inclusions are eosinophilic and have sharp round borders. These inclusions are also primarily present in necrotic neurons. There are a few cells that have what appear to be intracytoplasmic inclusions also. These inclusions are round to oval, eosinophilic, and appear to have sharp borders. In some places they look like invagination of cytoplasm into the nucleus of which the cytoplasm has undergone necrosis and is eosinophilic. Some of the eosinophilic droplets may be rounding up of cellular organelles. There is an extremely mild degree of cuffing of lymphocytes around vessels within this region of the hippocampus. The lateral geniculate body in this region is within normal limits. The thalamus in this region has a few areas of intramyelinic edema but for the most part the neurons appear to be relatively normal. The cells that have the intracytoplasmic and intranuclear eosinophilic inclusion-like

bodies are primarily present within the pyramidal cell layer and not found within the molecular cell layer. The inclusions are also only found in neurons and no evidence of inclusions are found in the astrocytes.

Slide 17/This section contains two sections of hippocampus and are probably in the C4 region. A moderate number of neurons within the molecular cell layer are necrotic and have eosinophilic cytoplasm. There is also a moderate to mild degree of edema within this layer. Necrotic neurons are also found within the pyramidal cell layer and similar intracytoplasmic and intranuclear inclusions can be found within this layer. A moderate amount of edema is present within this nuclear layer and within the stratum radiatum as with other cases. There is also a mild degree of lymphocytic cuffing around some of the vessels within these two sections of hippocampus.

Slide 7/Heart - There is a mild degree of interstitial edema throughout this section of heart. This section of heart is taken from the left papillary muscle. A section of atrium also shows mild edema but also several vessels containing postmortem bacteria. Purkinje cells of the heart are unremarkable.

Slide 8/Alveolar capillaries are moderately congested. There are few focal areas of infiltration of lymphocytes, plasma cells, macrophages, and neutrophils within alveolar spaces. In some areas the predominant cell is the macrophage. These are most likely small focal areas of pneumonia associated with parasitic activity. A moderate number of alveolar spaces do contain edema.

Atrium - A section of atrium is within normal limits.

Adrenal gland - No significant lesions (NSL).

Large peripheral nerves - NSL.

Slide 9/Stomach - This section of stomach does contain a large volcanic ulcer that is characterized by an enlarged necrosis down to the submucosa. There is an extensive degree of fibroplasia and inflammation within this ulcer. Numerous cross sections of small nematodes are present within this ulcer.

Lymph node - This lymph node is a pelvic lymph node. Lymphoid follicles are relatively active and there is one large nodule in this node that is characterized by necrosis of cells. Three

cross sections of probably a single nematode parasite are found within this area of necrosis.

Slide 10/Gastric lymph node - This lymph node is relatively active but has numerous holes in it suggesting autolysis and air trapping. There are several focal areas of necrosis associated with bacteria. Some of these areas are actually large areas of autolysis.

Pancreas - NSL.

Spleen - The lymphoid tissue is somewhat depleted within the follicles. There is one large thick serotic plaque in this region. The red pulp is slightly congested but has a normal degree of cellularity.

Slide 11/Small intestines - This section of small intestines has undergone moderate autolysis but is otherwise within normal limits.

Colonic lymph node - This lymph node has a normal amount of perifollicular lymphoid tissue but the small lymphocytes of the follicles are depleted.

Tonsil - The tonsil is relatively active. A moderate number of the tonsilar follicles do have evidence of lymphoid necrosis.

Slide 12/Placenta - A section of placenta is relatively congested and has a few small areas of necrosis but these areas are presumed to be within normal limits.

Liver - There is mild degree of congestion throughout the liver and there are few small focal areas of necrosis associated with an infiltration of lymphocytes and plasma cells and a few neutrophils. These small focal areas of necrosis are most likely associated with parasitic activity.

Tracheal lymph node - This lymph node has undergone severe autolysis. The lymphoid tissue of this node is quiescent and the follicles appear to be depleted.

Slide 13/Pituitary gland - NSL.

Mesenteric lymph node - This lymph node is active but many of the follicles are somewhat depleted.

Kidney - The kidney is mildly congested especially in the renal areas but otherwise the kidney is considered to be normal.

Slide 14/Small intestines - Autolysis, NSL.

Skeletal muscle - This is probably a section of diaphragm. The muscle is within normal limits. Many vessels are filled with postmortem bacteria.

Spleen - This section of spleen does contain depleted lymphoid follicles but the red pulp is within normal limits.

Hilar lymph node - This lymph node is edematous and contains follicles that appear to be somewhat depleted.

Slide 15/Colon - This section of colon does have a relatively normal mucosa but lymphoid follicles of the submucosa are somewhat depleted.

Bladder - NSL.

Ovary - Two sections of ovary are present. One ovary does contain a few active and developing follicles whereas the other ovary contains a corpus luteum that appears to be undergoing early degeneration.

Terry R. Spraker, DVM/PhD

Typed: 06-18-98 em, 06-22-98 em

COLORADO VETERINARY DIAGNOSTIC LABORATORY
College of Veterinary Medicine and Biomedical Sciences
Colorado State University, Fort Collins, CO 80523
Phone 970-491-1281
Fax 970-491-0320

DL#: 978-40605
Date: 6-4-98

Vet/Clinic: Dr. Francis Gulland
Owner: The Marine Mammal Center
Animal ID: 3770, Joule **Date Specimen Taken:** 6-4-98
Species: Z. californias **Breed:** **Age:** Adult **Sex:** F

History: This is an adult female California sea lion #3770 names Joule with tag #13198. This animal was found seizuring on 5-24-98 and was taken to the Marine Mammal Center on that date. The animal was euthanized on 6-4-98 due to lack of improvement of clinical signs.

DIAGNOSIS:
1. Vacuolization, severe both astrocytic and neuronal, Rinencephalon, brain.
2. Mild neuronal necrosis, neuropil edema and lymphocytic cuffing and lipidosis, paraventricular nucleus, thalamus, brain.
3. Vacuolization, severe small focus, superoptic nucleus, hypothalamus, brain.
4. Mild to multifocal myocardial degeneration, subacute, heart.
5. Pneumonia, chronic active multifocal mild, lung associated parafilaroides.
6. Edema, severe with massive thrombosis, uterine wall associated with uterine torsion.
7. Gastritis, ulcerative, stomach associated with nematodes
8. Interstitial nephritis, minimal, multifocal, cortex kidney

REMARKS: The only lesions in this animal that are compatible with some type of toxicity would be the severe vacuolization of the neurons and probably astrocytes within the Rinencephalon and the encephalopathy of the paraventricular nucleus of the thalamus and the superoptic nucleus of the hypothalamus. These lesions have been commonly found in seals with domoic acid toxicity. The mild multifocal areas of myocardial degeneration has also been commonly found in animals with domoic acid poisoning. The pneumonia and mild interstitial nephritis are common findings. The gastritis is also extremely common in seals.

GROSS NECROPSY: The animal is in fair body condition. The animal is pregnant in the right horn of the uterus. There is a 360° torsion within the uterus and the fetus is autolytic and has probably been dead for 4-5 days. There is extensive hemorrhage and necrosis within the cervical region of the uterus and numerous large thrombosed vessels with extensive edema in this area. The fetus was an anterior presentation. The peritoneal cavity contains 3-4 liters of a red/brown fluid. The omental sling was also edematous and reddened. The left kidney is slightly larger than the right and both kidneys were slightly pale. There are 2 siderotic plaques on the surface of the spleen and 7 volcanic ulcers within the stomach.

HISTOPATHOLOGY: Slide 1: Rinencephalon: This section of rhinencephalon is characterized by extensive holes throughout the cortical region. Some of these holes are within neurons and is associated with astrocytic swelling and neuronal loss. Chronic red neurons are not observed within this region. There is a mild degree of gliosis and a few vessels that are cuffed with lymphoid cells within this area of cortex. The olfactory stria and olfactory nuclear tissue in this region is relatively normal. Caudate nucleus is normal.

Slide 2: Caudate nucleus: A corpus colosum in this region is within normal limits. There are few holes within the internal capsule and within the globus palates which may have been areas of earlier edema.

Slide 3: Anterior thalamus: The periventricular nucleus medial dorsal and anterior medial nuclei of the thalamus in this region are within normal limits. There are few holes in the ventral medial nucleus in this section but they are not significant. Cross section of ocular motor nerve is within normal limits. The colostrum and posterior of the putamen in this area are within normal limits. The posterior aspect of the rhinencephalon in this region are anterior part of pyriform lobe is normal.

Slide 4: Thalamus, mid-region: This section is similar to the one just examined except in this area there is malacia, lymphocytic cuffing, and neuronal loss in the periventricular nucleus of the thalamus. However, this lesion is unilateral. Choroid plexus is normal. The central medial nucleus and perhaps rhomboids nucleus essentially the nuclei was in the thalamic adhesion are normal. The majority of the hypothalamic nuclei are normal except there are numerous holes in the neuropil of the superoptic nucleus. Lesions here are identical to the ones observed in the

rinencephalon. This section also contains an areas of posterior hippocampus. The meninges covering this area and the amictaloid nuclear complex does contain an increased number of lymphocytes and plasma cells. There is a mild wholly appearance within the pyramidal cell layer which may suggest mild edema within this area. There is also just an occasional neurotic neurons within the pyramidal cell layer but the molecular cell layer in this region is not observed. The amygdaloid nuclear area is rather normal except for an increase of lymphocytes and plasma cells within the meninges covering this region. The choroid around the hippocampus is normal. Few axons within the internal capsule still show mild evidence of edema or separation of the myelin layers.

Anterior brain stem at the level of ocular motor nucleus and exit of ocular motor nerve - The central gray substance and ocular motor nucleus in this region are normal. The superior cuniculus is normal. A section of hippocampus and dente gyrus in this region are within normal limits. Amygdaloid nuclear complex is also normal. Both the pyramidal cell layer and molecular cell layer are well preserved in this particular section. The meninges covering the hippocampus and the amygdaloid body is heavily infiltrated with lymphocytes and plasma cells.

Slide 6: Mid-thalamus, corpus callosum, and parietal cortex: The cortical area is within normal limits. An occasional hole is found within the corpus callosum and the anterior thalamic nuclei in this region are within normal limits.

Thalamus at the level of the habenular nucleus: The habenular nucleus and habenulothalamic tract is within normal limits. Mamillary body is normal. The zona inserta is within normal limits. Posterior caudal lateral and posterior caudal medial nuclei of the thalamus (proprial section) are relatively normal except for just a few holes that may have represented intramyelinic edema. Another section of hippocampus in this area is within normal limits. The amygdaloid nuclear complex and dentate gyrus are within normal limits.

Brain stem level of the superior cuniculus, oculomotor nucleus, areas of superior cuniculus, central gray substance, red nucleus and olfactory nucleus and substantia nigra are all within normal limits.

Pineal body is normal.

Slide 10: Hippocampus middle region: The layers of the hippocampus are within normal limits in this animal. The lateral geniculate body in the surrounding optic radiations are within normal limits. The dentate gyrus is normal. There are a few holes within the matter in this region but they are minimal. The fornix of the hippocampus is normal. There is a mild increased infiltration of lymphocytes and plasma cells within the choroid plexus in this region.

Slide 11: Hippocampus: This section is more from the posterior aspect of the hippocampus and dentate gyrus. These structures are all within normal limits. The lateral geniculate is also normal.

Brains tem/pons at the level of the medullary velum: The tegmental nucleus is normal. Large white matter tracts in this region are also normal. The pontine nuclei and fibers are normal. Cerebellum is normal.

Cerebellum with roof nuclei: There are a few extra holes within the white matter of the cerebellum in this region but they are minimal.

Obex: The dorsal vagus nucleus, hypoglossal nucleus, nucleus of the spinal tract of the trigeminal nerve and the olivary nuclei are all within normal limits. There are several holes within the medial aspect of the cuneate nucleus. These holes appear to be separation of neuropil possibly associated with edema. Neuronal necrosis is not observed in any of these nuclei.

Slide 14: Tonsil: The lymphoid tissue is normal but the overall gland appears to be smaller or atrophied. Two of the crypts do contain lymphocytes and a few neutrophils.

Adrenal gland: No significant lesions.

Thyroid gland: No significant lesions.

Spinal cord and adjacent spinal nerves: NO significant lesions.

Slide 15: Myocardium: There are a few small areas of the myocardium where there appear to have been edema and now there is mild myocardial degeneration and early fibroplasia.

Slide 16: Lung: There are a few small areas of lymphocytes and plasma cells within the parenchyma and alveolar spaces of the lung. Immature parasites can be found scattered throughout this section. The majority of these parasites are immature due to their lack of uterus and production of microfilaria.

Slide 17: Liver: There are a few small focal areas of lymphocytes and plasma cells scattered throughout the liver. In some areas there is also increased inflammatory cells around hepatic portal triad regions. These lesions are most likely associated with parasitic activity. There is an increased amount of collagen on the tip of the liver of this section. This is not unusual in older animals to have an increased fibrosis of Gleason's capsule especially at the tip. There is one area where there are a few extra lymphocytes and plasma cells and neturophils underneath the liver capsule.

Pancreas: No significant lesions.

Mesenteric lymph node: This node is relatively active and there is a moderate number of lymphocytes within the adventitia of this node but otherwise this node is relatively normal. It is probably a mesenteric node.

Esophagus: No significant lesions.

Slide 18: Stomach: This section of stomach is from a large volcanic ulcer. The ulcer penetrates into the superficial submucosa and is surrounded by an extensive infiltration of macrophages, lymphocytes, plasma cells and occasional neutrophil. There is also extensive fibrosis within the bed of this ulcer. Numerous cross sections of parasites can be found throughout.

Slide 19: Ileum: Two sections are present. There is at least one cross section of an immature nematode present on the surface of the villi in one of the sections. Lymphoid depletion is present in both sections of ileum.

Cecum: There are at leas tone or two crypts that are dilated and contain cellular debris but otherwise the colon is within normal limits.

Mesenteric lymph node: This node is relatively active and within normal limits.

Slide 20: Urinary bladder: No significant lesions.

Spleen: The lymphoid tissue is somewhat depleted and the red pulp is collapsed. One large siderotic plaque is present on this slide.

Kidneys: There are a few small areas of infiltration of lymphocytes and plasma cells within the interstitial tissues. These lesions are relatively minor and they are primarily located within the cortex.

Slide 21: Mesenteric lymph node: This node is within normal limits.

Skeletal muscle: No significant lesions.

Uterus: This section does contain numerous large congested and thrombotic vessels. This section of uterus was taken near the area of torsion.

Slide 22: Fibrisy: No significant lesions. The large branches of the trigeminal nerve are all within normal limits.

Slide 23: Section of uterus and cervix is mildly edematous but otherwise within normal limits.

Slide 24: Uterus: These sections of uterus are form the area near the torsion. And from the wall of the uterus. Both of these sections show extensive edema and congestion with thrombosed vessels.

Slide 25: Same as 24.

Terry R. Spraker, DVM/PhD

Typed: 06-19-98 lm

COLORADO VETERINARY DIAGNOSTIC LABORATORY
College of Veterinary Medicine and Biomedical Sciences
Colorado State University, Fort Collins, CO 80523
Phone 970-491-1281
Fax 970-491-0320
REVISED

DL#: 978-38159
Date: 5-25-98

Vet/Clinic: Dr. Francis Gulland
Owner: The Marine Mammal Center
Animal ID: 3780 CSL **Date Specimen Taken:** 5-25-98
Species: Z. californianus **Breed:** **Age:** Adult **Sex:** F

History: This is an adult female California sea lion #CSL3780 that was found seizuring on the beach and brought in for necropsy.

DIAGNOSIS:
1. Severe neuronal necrosis of nuclei of hippocampus with mild neuronal necrosis of thalamus and Purkinje cell layer, amygdaloid nuclear complex, brain.
2. Edema of neuropil and intramyelinic edema, diffuse, brain, severe.
3. Necrosis multifocal gastric lymph nodes associated with parasites.
4. Edema mild interstitial, heart, with multifocal areas of myocardial necrosis subacute.
5. Multifocal chronic active pneumonia mild lung associated with parafilaroides.
6. Mild necrosis, acute, with myocyte swelling, skeletal muscle.

REMARKS: The primary lesions in this animal were found in the brain and included severe neuronal necrosis especially of the hippocampus but also within the thalamus and amygdaloid nuclear complex with severe neuropil edema within these areas and throughout the brainstem. Intramyelinic edema was found throughout the whole brain especially in the large white matter tracts of the cerebrum, brainstem, and cerebellum. The other findings are considered to be incidental except perhaps the myocardial edema and necrosis. The myocyte necrosis may be associated with capture and handling and perhaps the chronic convulsions.

GROSS NECROPSY: This animal was in late term gestation and did have a fetus. The stomach and intestines were empty except for a small amount of blood tinged mucus. Gastric and mesenteric lymph nodes are enlarged and edematous. Lungs and congested and tonsils are enlarged. Myocardium does appear to be pale especially in the right atrium.

HISTOPATHOLOGY: Slide 1/Caudate nucleus/basal ganglia - The caudate nucleus is within normal limits. There is an extremely mild degree of edema within the globus pallides in this region and within the internal capsule. Corpus callosum does contain a few axons that have undergone intramyelinic edema.

Slide 2/Hypothalamus, interior thalamus - Intramyelinic edema is found within the internal capsule in this region. The nuclei within the hypothalamus are all within normal limits. Extremely mild degree of edema and an occasional eosinophilic neuron is found within these anterior thalamic nuclei. Intramyelinic edema is also found within the corpus colosum but the fornix is without lesions.

Slide 3/Brainstem at the level of the pineal body - This section of pineal body is relatively normal. The superior caniculus is also within normal limits. The brachium of the superior caniculus contains a few axons that have intramyelinic edema but it is very mild. There is a moderate degree of edema within the central gray substance in this region and within the ocular motor nucleus but neuronal necrosis is not observed in this area. Fairly severe edema of the myelin is found within the reticular formation in this area of brain. Axons of the ocular motor nucleus and ocular motor nerve appear to be normal.

Slide 4/Lateral geniculate body and hippocampus - White matter tracts covering the lateral geniculate body have undergone severe intramyelinic edema. There is a moderate degree of edema within the lateral geniculate body and a mild degree of intramyelinic edema. Some of the neurons have undergone severe chromatolysis but neuronal necrosis is not evident in this large of nucleus. There is extensive necrosis and edema within the pyramidal cell layer and within the molecular cell layer in this section of hippocampus. There is also moderate edema of the stratum radiatum. A number of neurons that have undergone necrosis within the granular cell layer is probably at least 95%. Potentially all of these neurons appear to be necrotic whereas about half of the neurons in the parietal cell layer are

necrotic. A moderate degree of intramyelinic edema is also found within the white tract covering the hippocampus. More anterior portion of hippocampus at least in this section is affected similarly as the tail portion but the degree of severity is much less in the head region. Severe intramyelinic edema is found within the corpus colosum in this region and within the white matter tracts adjacent to the cerebral white tracts adjacent to the hippocampus.

Slide 5/Brainstem at the level of the pons - Mild neuropil edema is present throughout the pontine nuclear mass. Mild central chromatolysis is present within some of the neurons but neuronal necrosis is not observed in this region. There is a fairly severe intramyelinic edema within the large white matter tracts all throughout this region of brainstem.

Slide 6/Cerebellum root nuclei and obex - The molecular Purkinje and granular cell layer are relatively normal. An occasional Purkinje cell is found that is undergoing necrosis but it is difficult to tell the significance of this finding since the number of Purkinje cells that have undergone necrosis are so few. There is a moderate degree of intramyelinic edema, however, within the white matter of the cerebellum. Edema is also present within the root nuclei but neuronal necrosis is not observed. The hypoglossal and dorsal vagus nucleus and cuniate nucleus and nucleus of the spinal tract of the trigeminal nerve all appear to be relatively normal. However, the large reticularis nucleus does contain some edema with a few axons coursing through it that have undergone intramyelinic edema. The white matter tracts from the hypoglossal nucleus have also undergone relatively severe intramyelinic edema. A mild degree of edema is present within the olive nuclei but neuronal necrosis is not observed in this nucleus.

Slide 16/Cerebrum, cerebellum, and hippocampus - This section of cerebellum is from the parietal lobe and all layers are normal within this section. There are just a few axons within the white matter that have intramyelinic edema. This section of cerebellum taken from more of a peripheral location does contain a few more necrotic Purkinje cells as the other section. There is also a moderate degree of intramyelinic edema of the white matter tracts. The granular and molecular layers appear to be normal. The hippocampus in this region is similar to what is previously been described. The majority of the neurons within both the pyramidal cell layer and the molecular cell layer have undergone

acute necrosis. These necrotic cells are surrounded by severe edema of the neuropil.

Slide 17/Mid-thalamus with hypothalamus - Intramyelinic edema is present within the internal capsule. The anterior aspect of the amygdaloid nuclear complex does contain a moderate degree of edema and a few necrotic neurons. The optic nerve in this region does contain a few axons with edema but otherwise is relatively normal. The hypothalamic nuclei are within normal limits.

Slide 7/Gastric lymph node - This gastric lymph node does contain several areas of necrosis associated with cross sections of large nematodes. These nematodes are most likely these gastric nematodes that have invaded lymphatic vessels. There is a moderate lymphoid hyperplasia around these necrotic foci.

Mammary gland - This mammary gland is totally inactive and there is a moderate amount of adipose tissue around glands.

Myocardium - There is a mild degree of interstitial edema within the myocardium in this slide. Occasionally small areas of necrosis associated with an infiltration of neutrophils can be found.

Slide 8/Spleen - Lymphoid follicles are present but only few are found and they are slightly depleted. The remaining pulp is extremely congested.

Adrenal gland - Vessels of the cortex are moderately congested but otherwise the gland is considered normal.

Mesenteric lymph nodes - These lymph nodes have a moderate amount of depletion of small lymphocytes within follicles but the perifollicular tissue is within normal limits. The nodes are also congested.

Pancreas - No significant lesions (NSL).

Lungs - Alveolar capillaries are moderately congested. There are a few alveolar spaces and adjacent alveolar walls that do contain a moderate number of macrophages, neutrophils, plasma cells, lymphocytes, and multinucleated giant cells. Occasionally eosinophils can also be found. In some areas there are small larval stages of nematode. These small nematodes appear to be a fourth stage or perhaps an early 5th stage larvae. This is

recognized by lack of or immaturity of the reproductive system and size. There is very little reaction around most of these parasites. Some of the larger parasites which are adult parafilaroides are within alveolar spaces and terminal bronchioles and these parasites are often surrounded by a moderate amount of inflammation primarily lymphocytes, plasma cells, macrophages, and a few neutrophils.

Tracheal, bronchial lymph node - These lymph nodes are relatively hyperplastic and congested but some of the follicles are undergoing early depletion.

Slide 10/Hepatic lymph node - This lymph node has a moderate degree of lymphoid hyperplasia and numerous active follicles.

Lung - Lung is similar to what has been previously been described.

Thyroid gland - The gland has normal active follicles.

Slide 11/Submandibular salivary tissue - This tissue is relatively normal.

Lymph node, probably mesenteric - This lymph node is markedly congested and has active follicles.

Large intestines - This section is within normal limits. The surface mucosal has undergone severe autolysis.

Placenta - Numerous hemorrhages and accumulation of hemosiderin are present within this section of placenta. A small degree of inflammation is associated with this hemorrhage. This is probably within normal limits, however.

Small intestines - This section is within normal limits. Mesenteric plexus appears to be somewhat edematous but no evidence of neuronal necrosis is observed.

Slide 12/Adrenal gland - The cortex is congested but is otherwise normal.

Mammary gland - This section of mammary gland is inactive and the surrounding skeletal muscle is within normal limits.

Lymph node - This lymph node has a small area of lymphoid tissue but the majority of the sinusoids are filled with blood.

Heart - This section of heart is similar to the one previously described. There appears to be a mild degree of interstitial edema throughout and an occasional foci composed of degenerated myocardial cells associated with a mild infiltration of inflammatory cells.

Slide 13/Urinary bladder - NSL.

Kidney - NSL.

Stomach - Several small sections of stomach are present and these do have small areas of erosion on the surface. These areas of erosion only go about 1/3 to 1/2 of the way through the mucosa and are often covered with bacteria. These could be early areas of autolysis associated with a bacteria but these would appear as white plaques on the gross exam.

Small intestines - This section of small intestines is within normal.

Slide 14/Heart - This section of heart is probably a right ventricle. Purkinje fibers are normal within this section. No lesions are found within the myocardium in this particular area.

Skeletal muscle - The origin of this skeletal muscle is not determined but usually skeletal muscle is taken from the pectoral region. This section of skeletal muscle does contain numerous necrotic myocytes. These myocytes are swollen and have extensive fragmentation and cleavage of myofibrils. There is also edema around these necrotic myocytes.

Kidney - This section of kidney is congested but otherwise within normal limits.

Diaphragm - This section appears to be of diaphragm and it is within normal limits.

Slide 15/Aorta - NSL.

Small intestines - NSL.

Skeletal muscle - This section of skeletal muscle is normal.

Salivary tissue - NSL.

Small intestines - NSL.

Stomach - A small amount of inflammation is present on one edge of this of stomach. This lesion is probably associated with parasites.

Tonsil - There is an extensive degree of lymphofollicular necrosis throughout this section of tonsil. Several of the crypts are filled with neutrophils and cellular debris.

Terry R. Spraker, DVM/PhD

Typed: 06-18-98 em, 6-22-98 em

COLORADO VETERINARY DIAGNOSTIC LABORATORY
College of Veterinary Medicine and Biomedical Sciences
Colorado State University, Fort Collins, CO 80523
Phone 970-491-1281
Fax 970-491-0320

DL#: 978-38160
Date:

Vet/Clinic: Francis Gulland
Owner: The Marine Mammal Center
Animal ID: Thirty Two - 3783 **Date Specimen Taken:**
Species: Z. californias **Breed:** **Age:** Adult **Sex:** F

History: : This is an adult female that is lactating and has a strong ammonia order. Multiple hemorrhages are found in the right flank. A 1 mm diameter ulcer is found over the hard palate. The animal has enlarged tonsils. Blood tinged mucus is present in the esophagus. Stomach and intestines are empty. Three volcanic ulcers are found within the stomach. Mesenteric and gastric lymph nodes are enlarged. The uterine horn is not enlarged and the ovaries are small suggesting this animal did not have a pup this year.

DIAGNOSIS:
1. Severe neuronal necrosis with edema of neuropil and intramyelinic edema brain.
2. Lymphoid hyperplasia with early follicular depletion, lymph nodes, myentery and gastric.
3. Pneumonia, multifocal, chronic active, lung associated with parasites.
4. Hepatitis, mild, multifocal, chronic active liver associated with parasite activity.

REMARKS: The most important lesions found in this animal is severe neuronal necrosis of the cerebellum and moderate neuronal necrosis of the migdaloid nuclear complex with severe neuronal and intramyelinic edema throughout the brain. Lymphocytic cuffing is not a feature in this animal. The other lesions including the multifocal areas of pneumonia, hepatitis and lymphoid hyperplasia with follicular depletion are commonly found and are usually associated with a parasitic activity. The cause of the lymphoid follicular necrosis of the tonsil is probably associated with the acute stress in this animal.

HISTOPATHOLOGY: Slide 1: This section is of the caudate nucleus and basal ganglia. This section is characterized by extensive intramyelinic edema of the corpus callosum. The caudate nucleus and basal ganglia specifically the globus pallidus are within

normal limits. The septal nuclei also appear to be normal. There is extensive intramyelinic edema of the internal capsule. There is a mild degree of edema of the nuclei of the olfactory stria and there is mild edema in the neuropil in this region.

Slide 2: Thalamus/hypothalamus: Moderate intramyelinic edema is present within the corpus callosum. The choroid plexus is relatively normal. A mild degree of edema is present throughout the nuclei of the thalamus and occasionally neuronal necrosis can be found within the thalamus. Nuclei of the hypothalamus are within normal limits. Intramyelinic edema can be found within the internal capsule in this region. A moderate intramyelinic edema is also found within the optic tracts. Extensive edema and neuronal necrosis is found within the amygdaloid nuclear complex.

Slide 3: Hippocampus: This section contains thalamus and part of the hippocampus and crus cerebelli. There is a mild degree of edema within the crus cerebelli but it's not extensive, however thee is moderate edema with an occasional necrotic neuron within the zona and certa of the thalamus. here is extensive edema within the dentate gyrus. Also a mild degree of neuronal necrosis is present within this gyrus also. There is extensive necrosis and edema of the pyramidal layer of the hippocampus and extensive edema within the stratum radiatum and severe edema and neuronal necrosis within the molecular layer of the hippocampus in this region. This area of the hippocampus is mostly in the middle probably C-2 and C-3 region. A mild degree of lymphocytic cuffing is found within vessels of the white matter between the hippocampus and the dentate gyrus.

Slide 4: Thalamus/habendular nucleus and mamillary body: There is moderate intramyelinic edema in the corpus collosum in this region. Hepindular nucleus is normal however three is evidence of edema of the neuropil especially of the ventral caudal layer and ventral caudal medial nuclei of the thalamus. A few neurons are also necrotic in this region. A few of the vessels have a mild degree of lymphoid cuffing in this area. A moderate degree of intramyelinic edema is found within the distal end of the optic tract in this region and a mild degree of edema is found in the crus cerebelli. Lesions are not found within the mamillary body.

Slide 5: Brain stem level of pineal body and red nucleus: Corpus callosum in this area has extensive intramyelinic edema. The pineal body appears to be within normal limits. Intramyelinic edema can be found within fibers of the commissure of the rostral colliculus. Central gray matter in this region is considered normal. There is extensive edema within the central tegmental tracts medial liminiscus and the medial longitudinal fasciculus. There is extensive intramyelinic edema

within all the white matter tracts throughout this area. Neuronal necrosis is not observed within the red nucleus or the substantia nigra.

Slide 6: Cerebrum, parietal lobe: Extensive intramyelinic edema is found within the large white matter tracts of this area of cerebrum. There appears to be mild edema of the cerebral cortex in this region but only an occasional neuron has undergone necrosis. VR spaces are slightly widened in this region.

Brain stem at the level of the interpeduncular nucleus: The interpedencular nucleus the red nucleus and the central gray substance and the reticular formation in this region all are relatively normal except for axons that are passing through these areas of which some of them do show intramyelinic edema. There is edema in the neuropil of the reticular formation and extensive intramyelinic edema in the large white matter tracts especially the medial longitudinal fasciculus. Mild edema of the neuropil is found within the pons and an occasional neuron is necrotic within the pontine nuclear area but the number of neurons necrotic are extremely low. The primary lesion within the pons is the edema.

Slide 8: Cerebellar/roof nuclei and obex: The molecular layer is relatively normal. There is a mild degree of edema within the Purkinje cell layer and a noticeable number of Purkinje cells that have eosinophilic cytoplasm. In some areas early neuronal degeneration and necrosis can be found within the Purkinje cell layer. The granular cell layer is relatively normal. Moderate intramyelinic edema is found within the white matter tracts of the cerebellum. Edema of the neuropil is found within the roof nuclei but neuronal necrosis is not observed in this specific section.

Obex: The hypoglossal and dorsal vagus nucleus, cuneate nucleus, nucleus of the spinus, spinal tract of the trigeminal nerve and olivary nuclei do not show nay evidence of neuronal necrosis. White matter tracts throughout this entire section of brain is characterized by mild to moderate intramyelinic edema.
Slide 9: Spinal cord C-1: There is mild edema of the white matter in this region but the gray matter may be slightly edematous but neuronal necrosis is not observed. Spinal nerves in this region are within normal limits. Pars nervosa does show extensive edema in several areas but the anterior pituitary gland is congested but within normal limits.

Kidney: The vessels throughout the cortex are congested but the glomeruli and tubules are all within normal limits.

Slide 10: Gastric lymph node: This lymph node has undergone lymphoid hyperplasia and there is at least one cross section of a large nematode within this area and several other areas of necrosis. There are also several holes in this lymph node that is probably air due to perhaps autolysis.

Slide 11: Stomach and mesenteric lymph node: This section of stomach does contain a large volcanic ulcer that is characterized by extensive ulceration of the mucosa. A large pocket of nematodes are also found deep within this submucosa. These parasites are lined by necrosis, numerous bacterial colonies and extensive infiltration of inflammatory cells and primarily lymphocytes, plasma cells, macrophages and neutrophils.

Mesenteric lymph node: There is a moderate degree of lymphoid depletion in this node and autolysis. A few inflammatory cells can be found within sinusoids. These are typical nodes that are draining areas of parasitic infection.

Slide 12: Heart and hilar lymph node: The hilar lymph node has advanced autolysis.

Spleen: The lymphoid tissue of the spleen is severely depleted and the red pulp is collapsed.

Heart: There is a moderate amount of interstitial edema throughout this heart, however numerous post mortem bacteria are also present throughout this section also. However there are a few small multifocal areas of acute myocardial necrosis associated with extremely mild accumulation of inflammatory cells. Therefore the edema and the necrosis is probably a real lesion. In other areas there are a few extra neutrophils associated with small areas of necrosis within the left ventricle.

Slide 13: Hepatic lymph node and liver: This hepatic lymph node has undergone lymphoid hyperplasia but the small lymphocytes are undergoing early depletion. An extensive amount of edema can be found throughout this lymph node. A few inflammatory cells can be found within sinusoids.

Liver: This liver has undergone moderate autolysis. However a few small focal areas of necrosis and infiltration of inflammatory cells can be found. These are usually associated with parasitic migration and activity. Numerous bacteria are found within hepatic vessels especially under the liver capsule.

Slide 14: Lung: There are a few areas of infiltration of lymphocytes, plasma cells and a few macrophages and neutrophils within the walls of alveolar spaces and within the adventitial

tissues of some vessels and bronchi and bronchioles. These small areas of pneumonia are all associated with parasitic activity. Alveolar capillaries are markedly congested. Within a few areas small nematodes, probably larval stages of parafilaroides, can be found. These are identified by size, shape and lack of reproductive system.

Small intestines: This sections of small intestines does contain a section or two of parasites but otherwise is within normal limits.

Pancreas: Moderate autolysis, no significant lesions.

Stomach: this section of stomach has undergone moderate autolysis but is otherwise normal.

Slide 15: Esophagus: The epithelium of the esophagus has undergone sloughing and is considered to be an autolytic change.

Kidneys: Vessels are congested but otherwise the glomeruli and tubules are within normal limits. However, this section has undergone mild autolysis.

Urinary bladder: No significant lesions.

Heart: This section of heart has undergone advanced autolysis.

Liver: Similar as described earlier.

Pancreas: No significant lesions. Moderate autolysis throughout.

Slide 17: Esophagus: No significant lesions.

Submandibular salivary gland: No significant lesions.

Adrenal gland: No significant lesions.

Skeletal muscle: No significant lesions.

Large peripheral nerves adjacent to the adrenal gland are within normal limits.

Gasserian ganglion: Within normal limits in this region.

Slide 18: Esophagus: The epithelium has undergone moderate autolysis but otherwise the esophagus is normal.

Tonsil: Lymphoid follicles are large but undergoing early depletion and are characterized by extensive lymphoid necrosis.

Hard palate: This section of hard palate was noted to have had an ulcer except on histo the epithelium is gone but it has undergone severe autolysis and there is no evidence of inflammation in this area. Therefore an ulcer of the hard palate cannot be confirmed on histo in this animal.

Slide 19: Stomach: No significant lesions.

Gall bladder and gall bladder ducts: These have undergone extensive autolysis and are surrounded by a mild degree of fibrosis. No evidence of inflammation is observed in these structures.

Lymph nodes: Mesenteric lymph nodes: These lymph nodes are all somewhat hyperplastic but are beginning to have mild follicular depletion. These lymph nodes are also mildly congested.

Slide 20: Skeletal muscle: There are a few linear areas of fibroplasia probably old scar tissue within the section of skeletal muscle. Inflammation is not present.

Lung: This section of lung is severely congested and hemorrhagic and contains a few cross sections of parasites.

Cerebrum: This section of cerebrum is the same as described earlier.

Slide 21 and 22: Both of these slides are of brain tissue specifically hippocampus area. These areas were taken from the mid region. The lesions found in these hippocampi are extremely minimal as compared to the other slide of hippocampus from this animal. However, a moderate degree of intramyelinic edema and neuropil edema of the lateral geniculate body is present within this slide. This is especially prevalent on slide 22.

Terry R. Spraker/DVM, PhD

Typed: 6/17/98 lm

COLORADO VETERINARY DIAGNOSTIC LABORATORY
College of Veterinary Medicine and Biomedical Sciences
Colorado State University, Fort Collins, CO 80523
Phone 970-491-1281
Fax 970-491-0320

REVISED

DL#: 978-39395
Date: 6-2-98

Vet/Clinic: Dr. Francis Gulland
Owner: The Marine Mammal Center
Animal ID: 3791, Neville **Date Specimen Taken:** 5-24-98
Species: Z. californianus **Breed:** **Age:** Adult **Sex:** F

History: This is CSL#3791, Neville. This is an adult female that was found convulsing and brought into the Marine Mammal Center on 5/24/98. The animal was euthanized 10 days later on June 2nd.

DIAGNOSIS:

1. Severe neuronal loss, hippocampus and amygdaloid nuclear complex with extensive malacia and lymphocytic cuffing and gliosis, brain.
2. Neuronal degeneration with intramyelinic edema and edema of the neuropil of the ventral caudal lateral and ventral caudal medial nucleus of the thalamus and the cuniate nucleus, brain.
3. Myocardial fibrosis, mild, multifocal, heart.
4. Interstitial nephritis, mild, dilated loops of Henle, kidney.
5. Multifocal pneumonia, mild, lung, associated with parasitism.
6. Pedunculated lipoma, uterus.

REMARKS: Primary lesions in this animal include the severe loss of neurons and malacia and lymphocytic cuffing in gliosis of the hippocampus and amygdaloid nuclear complex. These are probably parative processes going on in these areas. Myocardial lesions are also probably associated with the toxic process going on in this animal. The ulcerated gastritis and multifocal pneumonia are common findings in adult California sea lions. The interstitial nephritis may suggest that this animal at one time had a mild bacterial infection of the kidney such as leptospirosis. The pedunculated lipoma is an incidental finding and has been observed in California sea lions.

GROSS NECROPSY: Gross findings include a glistening firm lobulated mass 4x3.5 cm on a 2 mm stock on the left uterus. Serosal surface of the stomach contain multiple large thickened plaques. Three ulcers are present within the stomach. A moderate amount of gray exudate is present within the laryngeal pouch. One small focal area of thinning of the retina is observed. The common bile duct is markedly dilated but there is a communication between the bile duct to the duodenum but the communication at the papillary structure in the duodenum is extremely small. The right lobes of the liver are markedly atrophied and the bile ducts within these areas are markedly atelactatic.

HISTOPATHOLOGY: Slide 1/This section is of the rhinencephalon and olfactory stria and nuclei. The caudate nucleus in this region is within normal limits. A few holes are found in the nuclei of the olfactory stria but the lesions are considered minimal. The rhinencephalon in this area is normal.

Slide 2 at the level of the caudate nucleus - The corpus callosum, septal nuclei, caudate nucleus, basal ganglia, and internal capsule are within normal limits in this section.

Slide 3/Thalamus/hypothalamus - There is an occasional hole scattered throughout the thalamus and its region but the number or relatively few and not extra ordinary like was observed in other cases. There are also a few holes in the internal capsule which may be the result of previous edema but again they are not out of the ordinary. One unusual finding in the ventral aspect of the internal capsule are a group of 9 or so vessels that are surrounded by concentric rings of what appear to be collagen. These are extremely unusual and I have never observed this in a brain section. There is no inflammation around these areas. All of these foci appear to be within the VR spaces and appear to be collagen encircling small vessels.

Thalamus at the level of the habendular nucleus - This section contains mid- to posterior aspect of hypothalamus which is within normal limits. The lamic nuclei in this area also are relatively normal except for the ventral caudal lateral and ventral caudal medial nucleus of the thalamus. In this area there appears to be edema of the neuropil and a lacy appearance to the cytoplasm of many of the neurons. Many of the neurons also appear to be undergoing degeneration. There are also a few areas of gliosis within this region. There is also a mild infiltration of

lymphocytes within the choroid plexus. There is a mild degree of intramyelinic edema within the ventral caudal lateral and ventral caudal medial nucleus of the thalamus. The optic tract in this region is normal. The habendular nucleus and other nuclei of the thalamus are within normal limits. The anterior section of the amygdaloid complex at this level does show lymphocytic cuffing and gliosis within the cortical gray of this area. There is also a slightly increased numbers of lymphocytes and plasma cells within the meninges of this area.

Slide 5/Thalamus at level of pineal body and posterior area of hypothalamus - The anterior pituitary gland in this region is normal. Hypothalamic nuclei are within normal limits. Posterior caudal lateral and posterior caudal medial nuclei of the thalamus are similarly affected in this slide as previously described. A nucleus probably the lateral posterior nucleus of the thalamus does contain an area of mild neovascularization gliosis and lymphocytic cuffing and there is only a mild degree of loss of neurons in this region. Corpus colosum in this region is within normal limits. Pineal body also is relatively normal.

Slide 6/Thalamus posterior aspect and ventral caudal lateral and ventral caudal medial nucleus of the thalamus is similarly involved in this section as in other areas. The lateral posterior nucleus of the thalamus is characterized by extensive gliosis and lymphocytic cuffing with mild neuronal loss. There is also a few holes scattered throughout the rest of the thalamus and there is evidence of an intramyelinic edema in the internal capsule in this region. The lesions of the posterior caudal lateral and posterior caudal medial nuclei of the thalamus (nuclei appropria septum) are severely affected in this region with intramyelinic edema and neuronal loss. There is even one relatively large area of malacia in this area. The area of malacia is characterized by loss of neural tissue with separation of fibers and extensive infiltration of glial cells and lymphocytes. Jitter cells are not found in this focus. Many of the neurons that still have an intact nucleus in this area have undergone severe central chromolysis. There is also an occasional neuron that has an intracytoplasmic vacuole. A cross section of ocular motor nucleus in this region is normal. The amygdaloid nuclear complex in this region is characterized by extensive lymphoid cuffing with diffuse gliosis and neuronal loss. There is extensive neovascularization in these regions and the endothelial cells are markedly hypertrophied. The meninges covering this region has a mild increased numbers of lymphocytes

and plasma cells.

Slide 7/Posterior thalamus/amygdaloid nuclear area - This section is similar to Slide 6 except there is extensively more severe lesions within the amygdaloid nuclear area. There is extensive neovascularization with hypertrophy of endothelial cells, numerous dead neurons scattered throughout. These neurons are not associated with neurophagia. Vessels are cuffed with lymphocytes and plasma cells and there is large areas of malacia with jitter cell accumulation. There is one section of hippocampus on this slide and it is characterized by extensive loss of parametal cells associated with extensive diffuse and focal gliosis with lymphocytic cuffing. A molecular layer is not found on this slide. Perhaps this area has totally disappeared but remnants of the layer are not observed in this particular area. This section also contains a posterior aspect of the hippocampus and the majority of the parietal cells are gone and the molecular cell layer is not found. There is extensive perivascular cuffing and diffuse gliosis throughout. There are numerous eosinophilic droplets in the parietal cell layer which are remnants of parietal cell neurons. Remnants of the molecular cell layer are difficult to discern but can be found in several areas. In summary in this area probably 95% of the neurons of the parametal cell and molecular cell layer of the hippocampus are gone.

Slide 9/This section is of amygdaloid complex and it is similar as described earlier with extensive malacia, lymphocytic cuffing, and diffuse gliosis. The hippocampus on this slide is similar as described earlier with nearly total loss of parametal and molecularly layered neurons with extensive gliosis. In this particular slide there is extensive malacia with the accumulation of jitter cells and perhaps gamesticytic astrocytes.

Slide 10/Amygdaloid nuclear complex and posterior hippocampo region - The lesions in this slide are similar to the ones described, the only addition is that there is extensive malacia with jitter cell accumulation within the hippocampus. The majority of the neurons of the parametal cell layer and the molecular cell layer are gone.

Slide 11/Brainstem/superior colliculus - The cerebellum in this region has normal molecular and granular cell layer. The white matter tracts are normal. Many of the Purkinje cells have undergone central chromatolysis. The superior colliculus is

within normal limits. The tegmental nuclei are also normal. The anterior portion of the pons in this region is within normal limits. The interpeduncular nucleus is normal.

Brainstem at level of olive nuclei and dorsal vagus nucleus - The dorsal vagus nucleus, hypoglossal nucleus, and olive nuclei all are within normal limits in this region. Numerous large holes are present within the cuniate nucleus This lesion in the cuniate nucleus would correlate with extensive number of lesions within the ventral caudal lateral nucleus of the thalamus. This section of cerebellum is similar to what is previously described. The root nuclei are within normal limits in this area.

Slide 13/Pituitary gland - There does appear to be separation perhaps edema within the stalk of the pars nervosa. The anterior pituitary is within normal limits.

Spinal cord - No significant lesions (NSL).

Obex - This section of obex is similar to the one described in slide 12. There is extensive edema or large holes throughout the cuniate nucleus but the dorsal vagus nucleus hypoglossal nucleus and nucleus of the spinal tract of the trigeminal nerve and olive nuclei are all within normal limits.

Slide 14/Cerebrum at level of pyriform lobe - This section is within normal limits.

Slide 15/Pancreas - NSL.

Pancreatic lymph node - This lymph node contains an extensive amount of black granular pigment that is probably associated with a bile duct fluke infection. The lymphoid activity of this node is within normal limits.

Lungs - There are few focal areas of infiltration of lymphocytes and plasma cells, macrophages, and a few neutrophils scattered throughout the lung parenchyma both within alveolar walls and within alveolar spaces. These lesions are most likely associated with parasitic infections. There are few cross sections of parasites on this slide that are compatible with parafilaroides. The overall inflammation within the lung is minimal. Bronchi and bronchioles are all open and clean.

Slide 16/Heart - There are several areas of myocardial degeneration with early interstitial fibrosis throughout the heart. These lesions are characterized by characterized by early fibroplasia of the interstitial tissues of the heart with a mild infiltration of inflammatory cells.

Slide 17/Kidney - There are few areas of mineralization within the renal pelvis and a moderate number of Henle's loop in this region are dilated and filled with a protein-rich fluid and mineralization. In the areas of mineralization there is a moderate degree of interstitial edema. There are few areas in which lymphocytes and plasma cells found within the interstitial tissues of the cortex. In some areas the areas are relatively large.

Small intestines - This section is relatively normal. A few small focal areas of lymphocytes are present within the submucosa and within the serosal and muscular layers of this section.

Urinary bladder - NSL.

Adrenal gland - A few holes are present within the zona glomerulosa of the adrenal gland. These are probably cells that have undergone extensive hydropic degeneration but they are confined to the zona glomerulosa. The zona reticularis and fasciculata are within normal limits, but appears to be slightly thickened. There is a moderate degree of fibroplasia at the cortical medullary junction.

Thyroid gland - Follicles are relatively normal throughout.

Small intestines - This section is relatively normal. There are a few focal areas of lymphoid accumulation within the deeper layers of the submucosa that are probably associated with parasitic activity.

Mesenteric lymph node - This lymph node is active but considered to be normal. Large mesenteric nerves and vessels are all within normal limits.

Slide 19/Mesenteric lymph node probably a colonic lymph node - This lymph node is active and within normal limits.

Ileum - NSL.

Large intestines - This is a section of cecum and it is considered to be within normal limits.

Mesenteric lymph node - This is a large mesenteric node that has normal active follicles and is considered to be within normal limits.

Spleen - This spleen has a normal number of follicles some of which are active and others are quiescent. A large splenic scar associated with hemosiderosis is present on this section. The red pulp is collapsed and of normal cellularity.

Slide 21/Ovary - This section of ovary contains small degenerated corpus luteum. The uterus has a normal thickness to the endometrium and is considered a normal inactive uterus. The stalk of the nodule found on the uterus is examined and this stalk appears to be made up of large fascicles of smooth muscle. Cells fusiform in shape have elongated and truncated nuclei and are surrounded by an extensive amount of eosinophilic somewhat fibrillar cytoplasm. Small packets of these cells are surrounded by a collagen. The mass is composed of teats of fusiform shaped cells with truncated nuclei that are surrounded by a moderate amount of finely fibrillar cytoplasm. These neoplastic cells are forming wide interweaving bundles. In some areas there appears to be extensive ground substance and perhaps edema between these cells forming large areas of hypocellular and areas filled with eosinophilic ground substance.

Slide 23/Stomach - This section of stomach contains a large ulcer that progresses down into the submucosa. An extensive infiltration of inflammatory cells is surrounding this ulcer. Several cross sections of extremely nematodes are present within this ulcerated area.

Slide 24/Gallbladder - This section of gallbladder has an extensive infiltration of lymphocytes and a few plasma cells within the lamina propria. There is destruction of the villi and loss of epithelial cells. The wall of the gallbladder is thickened due to fibrosis and mild infiltration of lymphocytes.

Hepatic lymph node - This lymph node is relatively active and has numerous germinal centers.

Pancreas - NSL.

Small intestines - NSL.

Skin - This section of skin was from the back of this seal. There is a large ulcerated area of the dermis and an extensive infiltration of inflammatory cells around this break in the epidermis and within the underlining subcutaneous tissues. There is also a moderate degree of fibrosis scattered throughout. This lesion may be associated with a bite wound or some other type of laceration to the skin. Bacteria or other organisms are not found within the deeper layers in this lesion, however, numerous bacteria are found on the surface of the ulcer.

Terry R. Spraker, DVM/PhD

Typed: 06-19-98 em

COLORADO VETERINARY DIAGNOSTIC LABORATORY
College of Veterinary Medicine and Biomedical Sciences
Colorado State University, Fort Collins, CO 80523
Phone 970-491-1281
Fax 970-491-0320

DL#: 978-40604
Date:

Vet/Clinic: Francis Gulland
Owner: The Marine Mammal Center
Animal ID: Roller CSL3793 **Date Specimen Taken:**
Species: Z. californias **Breed:** **Age:** Adult **Sex:** F

History: This is an adult California sea lion female number CSL3793, name is Roller, tag number 13197. This animal was admitted on 5/25/98 and was euthanized on 6/4/98. She did deliver a stillborn fetus several days prior to death.

DIAGNOSIS:
1. Severe neuronal necrosis, hippocampus.
2. Neuronal necrosis, edema and malacia, the amygdaloid nuclear complex, brain.
3. Glial scar, caudate nucleus, brain.
4. Pharyngeal cyst, pineal body, brain.
5. Acute to subacute necrosis, mild, multifocal, heart.
6. Interstitial nephritis, mild, kidney.
7. Laryngitis, chronic active laryngeal pouches.
8.

REMARKS: This animal does contain the typical lesions of animals that have been exposed to dumoic acid toxicity. These lesions are primarily located within the brain and the heart. The pharyngeal cyst at the pineal body is most likely an incidental finding. The mild interstitial nephritis may be associated with a previous lepto infection, however the degree of inflammation is extremely mild and did not compromise the animal. The cause of the mild laryngitis has been identified to b ea streptococcus. The importance of this lesion is not known but it is a relatively common finding.

GROSS NECROPSY: This animal is in fair body condition. The right uterine horn is distended and contains a small amount of mucoid material. This is the site of previous placental attachment.

HISTOPATHOLOGY: Slide 1: Rinencephalon: This section contains olfactory bulb which does contain vessel that is cuffed by lymphocytes. The olfactory stria and nuclear layer are normal.

The rinencephalic cortex is normal. The anterior aspect of the caudate nucleus is within normal limits.

Slide 2: Caudate nucleus: This section of caudate nucleus and septal nucleus is within normal limits. The internal capsule is also normal. Putamem in this region is normal. There is one unusual area within the caudate nucleus adjacent to the lateral ventricle. This area is somewhat of a cystic area that is surrounded by a few lymphocytes and plasma cells and there is an adjacent area that has a relatively heavy concentration of glial cells and only an occasional lymphocyte. This is suggestive of a relatively large glial scar within the caudate nucleus. Edema and neuronal necrosis is not present around this old glial scar.

Slide 3: Thalamus/hypothalamus: There is a moderate degree of neovascularization gliosis and mild perivascular cuffing within the paraventricular nucleus of the thalamus. The medial dorsal nucleus and anterior medial nucleus are relatively normal. A few remnants of dead neurons can be found within this region. Corpus callosum and fornices of the hippocampus are normal. Hypothalamic nuclei are within normal limits and inner thalamic adhesion is normal. Amygdaloid nuclear complex at this level is normal. Internal capsule is normal. Posterior aspect of caudate nucleus is normal.

Thalamus/hypothalamus: This section of mid thalamus and hypothalamus are within normal limits.

Optic tract is normal. There is a mild degree of lymphoplasmacytic cuffing and gliosis throughout the amygdaloid nuclear complex. There is a relatively large area of early malacia and edema within this area with neuronal dropout and necrotic neuronal remnants.

Mid thalamus and adjacent cerebrum, parietal lobe: There is an increased number of nuclei in a linear pattern within the corpus callosum. Some of these appear to be around degenerated axons. This is suggestive of an increased number of oligodentrogolcytes and this increase of cellularity may be associated with a healing process from this intramyelinic edema. There are a few axons that do show edema and degeneration. Some of these cells may also be astrocytes. The thalamic nuclei in this area are normal.

Slide 6: Mid thalamus at level of the pituitary stalk: There is a mild degree of lymphocytic cuffing and gliosis within the medial dorsal nucleus of the thalamus. This also may be part of the paraventricular nucleus of the thalamus also. This area is characterized by lymphocytic, plasmacytic cuffing with gliosis and neovascularization. Neuronal necrosis is still evident in this area. Choroid is normal except for some what of an unusual

plaque of large foamy like cells that could be like extremely early cholesteoma but it is extremely small and probably insignificant. Hypothalamic nuclei are normal in this region.

Slide 7: Thalamus level of the habenular nucleus: The habenular nucleus and remaining thalamic nuclei at this level are within normal limits. The crus cerebellae and optic tract are normal. The internal capsule is normal. The clostrum and putamem are normal in this area. There is extensive malacia with neovascularization and perivascular cuffing within the amygdaloid nuclear process. The section of posterior hippocampus is present. The molecular and parietal nuclear cell layers is just about devoid of neurons and there is a mild degree of gliosis and perivascular cuffing in this area.

Slide 8: Cerebrum at the level of the parietal lobe: Both the gray and white matter are within normal limits in this area. The fornix is normal. There is a mild accumulation of lymphoid cells within the choroid at this level.

Slide 9: Thalamus at the level of the pineal body and exit of the oculomotor nerve: Pineal body is considered to be normal. Corpus callosum is similar to what has previously been described. Pulvinar is within normal limits. The posterior commissure, central gray matter, oculomotor nucleus and nerve are all within normal limits. Meninges in this area are normal. There is a large cystic area within the pineal body. This cyst is lined by columnar cells. This is probably a genetic anomaly but is most likely not an important lesion. In several areas these cells are ciliated suggesting that this is some type of pharyngeal cyst again confirming that this is most likely a congenital anomaly of little significance. However, this cyst does take up about half the gland.

Slide 10: Brain stem/superior colliculus: The superior cuniculus and central gray substance in this region is normal. The inner peduncular nucleus is within normal limits. The most anterior surface or origin of what is probably the dentate gyrus contains numerous eosinophilic neurons and moderate gliosis. This area is suggestive of the molecular layer of the hippocampus and is probably the origin of the anterior origin of the hippocampus. The parietal cell layer in this region is also affected but not as severely. There is mild gliosis throughout this entire area.

Slide 11: Posterior thalamus: This section contains the anterior aspect of the lateral geniculate body and mid region of hippocampus. Many of the neurons of the pyramidal cell layer and molecular cell layer are missing and there is a mild gliosis throughout. Numerous degenerate neurons can be found within this area of hippocampus. Neuronal phagia is not evident. The

extensive changes of edema of the stratum radiatum that is found in the acute cases is not found in these more chronic cases.

Slide 12: Hippocampus mid region: The lesions of the hippocampus are identical as was previously been described. There is extensive lymphocytic cuffing and early malacia in the amygdaloid nuclear complex in this region. The lateral geniculate body is within normal limits.

Brain stem/pons: The tegmental nucleus is normal and vestibular nuclei are normal. Nuclei and fibers of the pons are within normal limits. All layers of cerebellum are normal.

Slide 14: Cerebrum and roof nuclei: No significant lesions.

Obex: All of the nuclei of this section of obex are within normal limits.

Slide 15: Heart: There are a few extremely small focal areas of myocardial degeneration with increased accumulation of inflammatory cells. These lesions are scattered throughout the heart especially within the papillary muscle of the left ventricle. There are at least two vessels in this region that appear to be partially occluded by fibromuscular intimal thickening. There are also a few small areas of acute necrosis within the myocardium. Several small focal areas of mineralization can also be found within the myocardium.

Slide 16: Lungs: There are multifocal areas of accumulation of lymphocytes, plasma cells a few macrophages and neutrophils scattered throughout the lung parenchyma. Several of these focal areas are associated with mature and immature parafilaroides.

Slide 17: Pancreas: No significant lesions.

Mesenteric lymph node: No significant lesions.

Kidney: There are a few small focal areas of lymphoplasmacytic infiltration within the interstitial tissues of the kidney. There is also extremely mild congestion at the corticomedullary junction. The degree of inflammation is considered minimal.

Slide 18: Trigeminal nerve with ganglia: No significant lesions.

Pituitary gland: No significant lesions.

Spinal cord: No significant lesions.

Spinal nerves: No significant lesions.

Mammary gland: There are just a few lobules of the mammary gland that contain a small amount of inspissated basophilic material that is probably milk. The remaining gland is inactive.

Slide 19: Liver: The hepatocytes are slightly atrophied and there is a mild to moderate infiltration of lymphocytes and plasma cells within the adventitia of hepatic portal triads. There is also a slightly increased degree of fibroplasia around bile ducts.

Skeletal muscle: No significant lesions.

Small intestines: No significant lesions.

Mesenteric lymph node: This lymph node is fairly active and is within normal limits.

Stomach: This section of stomach contains a large ulcerated area that extends midway in the submucosa. Numerous cross sections of parasites are found in the surface of this ulcer. Macrophages, plasma cells, lymphocytes and neutrophils have infiltrated into this area underneath the ulcer. Cross sections of parasites are also found adjacent to the ulcer within the more normal mucosal areas.

Slide 21: Pancreas: No significant lesions.

Cecum: There is one large granuloma containing what appears to be degenerated cuticular material probably from a parasite. This material is surrounded by multinucleated giant cells, plasma cells, macrophages and a few lymphocytes and an occasional neutrophil.

Lymph node, probably peripheral: This lymph node is active and considered to be within normal limits.

There are two more sections of small intestines, one is normal and other one does have one small focus of scarring within the mucosa that is associated with previous parasitic activity.

Slide 22: Small intestines: No significant lesions.

Bile duct and gall bladder: These structures have a marked infiltration of lymphocytes and plasma cells within the lamina propria of the mucosal layer and there is disorganization of the mucosal layer of these structures. These lesions are associated with hepatic flukes.

Spleen: The lymphoid tissue of the spleen is considered to be normal. The red pulp is severely congested and there is some siderotic plaque on the surface.

Slide 23: Adrenal gland: There are a few holes in the zona glomerulosa. This is a relatively common finding in California sea lions.

Pharyngeal pouch: This section of pharyngeal pouch does contain a marked infiltration of lymphocytes and a few plasma cells underneath the squamous epithelial layer. Some of the sebaceous like glands are filled with a basophilic inspissated in appearance material. This structure is of the pharyngeal pouch that was noted to be inflamed.

Tonsil: The tonsil has normal active lymphoid follicles and is considered to be somewhat small but within normal limits.

Slide 24: Mesenteric lymph nodes: These lymph nodes are active and considered to be within normal limits.

Peripheral lymph node: This node is considered to be normal.

Thymus: The thymus has undergone severe atrophy but is within normal limits.

Esophagus: No significant lesions.

Slide 25: Vagina, cervix: There is extensive hemorrhage in the cervix and an extremely mild degree of inflammation.

Ovary: One ovary contains active follicles and a large corpus albecans. The other ovary contains a large corpus luteum.

Terry R. Spraker/DVM, PhD

Typed: 6/19/98 lm

erinary Medical Teaching Hospital
versity of California, Davis

17Dec98 at 3:51pm.

PATHOLOGY BIOPSY
FINAL REPORT

INIC NO.:
ECIES: OTHER SMALL ANIMAL
EED: SEA LION
X: F LIFESTAGE: ADULT
G NO.: CSL 3794 MUDDY TAG #13111
INICIAN: No Doctor #
NER: MARINE MAMMAL CNTR ATTN: EILEEN ECONOMY
DRESS: Golden Gate Nat'l Rec Area Bldg 1044
Sausalito, CA 94965
MMENT: WEIGHT: 100 KG

PATHOLOGY NO.: 98B 1483
DATE REQUESTED: JUNE 15, 1998
RESIDENT: L.J. LOWENSTINE, DVM,PhD

****

ECIMEN: BIOPSY TISSUE PRESERVATIVE: FORMALIN DATE REPORTED: DEC 16, 1998

****

THOLOGIC DIAGNOSIS:

1) SEIZURES ASSOCIATED WITH DOMOIC ACID INTOXICATION (CLINICAL DIAGNOSIS)
2) BRAIN: MODERATE, NONSUPPURATIVE MENINGITIS
3) PLACENTA: PLACENTITIS, CHARACTERIZED BY MULTIFOCAL, ACUTE NECROSIS, THROMBOSIS, AND MARKED SUPPURATIVE INFLAMMATION
4) BLADDER/URETHRA: ACUTE TO SUBACUTE CYSTITIS/URETHRITIS WITH FOCALLY EXTENSIVE CONGESTION AND INTRAEPITHELIAL PUSTULES
5) TRACHEA: MODERATE LYMPHOCYTIC AND PLASMACYTIC TRACHEITIS
6) LUNG: DIFFUSE CONGESTION, EDEMA AND ATELECTASIS
7) KIDNEY: MILD LYMPHOCYTIC INTERSTITIAL NEPHRITIS WITH MULTIFOCAL MINERALIZATION
8) LIVER: CHRONIC PERIPORTAL HEPATITIS, ETIOLOGY: PRESUMED PARASITIC (FLUKES)
9) LIVER: ACUTE PASSIVE CONGESTION
10) HEART: MODERATE ENDOCARDIAL FIBROSIS
11) BODY AS A WHOLE: MICROVASCULAR FIBRIN AND NEUTROPHILIC THROMBI SUGGESTIVE OF ACUTE SEPSIS

NICAL ABSTRACT:

This adult, female, California Sea Lion was stranded at Moss Landing in terey County on 5/25/98 and was admitted to the Marine Mammal Center on the e day. She had had repeated seizures and was stranded at the time of a mful algae bloom. She died on 5/31/98 and a postmortem was performed about 16 rs after death. She had a standard length of a 165 cm, axillary girth 98 cm, ilical girth a 105 cm, and blubber depth 15 mm. Her weight was a 100 kg and was given a 4/7 somatic index scale. A laryngeal swab revealed Strep. idans and Corynebacterium sp. Postmortem was performed by Dr. T. Spraker who nd an adult female in good condition. She had four small, 1-4 mm, gray, sed plaques on the wall and valve of the left atrium. There were a few flukes the liver and mild biliary fibrosis throughout. The tonsils were slightly arged but remaining lymphoid tissue was OK. 4-10 small nematodes were found the stomach, but no ulceration. A few Acanthocephalids and tapes were present the small intestine and ileum. The female was pregnant with a large male us - DMD approximately 12 hours. No gross lesions in the fetus. There was ut 400 cc of dark yellow-brown (? hemoglobin) urine in the bladder and all er organs were grossly normal. This animal's fetus is 98B1363.

DEC 19
DISTRIBUTED
TO

GROSS DESCRIPTION:

The specimen consists of a bucket marked "CSL 3794-5/31/98" containing formalin and tissue samples. The samples are recognized as six pieces of brain, two eyes, two pieces of skin, one piece of pancreas, one piece of tongue, two tonsils, one piece of salivary gland, two pieces of spleen, one heart, one lung one trachea, four GI tract, one diaphragm, two muscle, two kidney, two nerves, one adrenal, one urinary bladder, one ovary, three pieces of ovary, four pieces of liver, eight lymph nodes for a total of 53 samples. Portions of the brain were sectioned sagittally instead of horizontally by accident by Hendrick Nollens, veterinary prosector, who trimmed the tissues. The tissues were trimmed 7/13/98, but the brain was not submitted until 8/3/98.

HISTOPATHOLOGICAL SUMMARY:

The following tissues were examined microscopically: (T1) lung, spleen, pancreas, kidney; (T2) esophagus, stomach, small intestine; (T3) adrenal, ovary heart; (T4) skin, trachea; (T5) salivary gland, bladder, (?) vagina, tongue; (T6) liver, lymph node X2; (T7) heart, bladder, vagina; (T8) mammary gland, liver, placenta; (T11) pineal, cervical cord, medulla; (T12) cerebellum, pons; (T13) thalamus, hypothalamus.

COMMENT:

The cause of death may have been related to fetal death, placentitis and acute sepsis, however, the fetus was estimated to have died at the time of maternal death. No brain lesions were seen in sections examined, however, additional sections are needed. The important sections of ventral anterior hippocampus were not present in samples submitted.

la

Linda J. Lowenstine

L.J. LOWENSTINE, DVM, PhD

Veterinary Medical Teaching Hospital
University of California, Davis

17Dec98 at 3:52pm.

PATHOLOGY BIOPSY
FINAL REPORT

CLINIC NO.:
SPECIES: OTHER SMALL ANIMAL
BREED: SEA LION
SEX: F LIFESTAGE: ADULT
TAG NO.: CSL #3796 KRISTIN TAG #13188
CLINICIAN: No Doctor #
OWNER: MARINE MAMMAL CNTR ATTN: EILEEN ECONOMY
ADDRESS: Golden Gate Nat'l Rec Area Bldg 1044
Sausalito, CA 94965
COMMENT: WEIGHT: 105 KG

PATHOLOGY NO.: 98B 1468
DATE REQUESTED: JUNE 12, 1998
RESIDENT: L.J. LOWENSTINE, DVM,PhD

****
SPECIMEN: BIOPSY TISSUE PRESERVATIVE: FORMALIN DATE REPORTED: DEC 16, 1998
****

PATHOLOGIC DIAGNOSIS:

1) SEIZURES ASSOCIATED WITH DOMOIC ACID INTOXICATION (CLINICAL DIAGNOSIS)
2) UTERUS: UTERINE TORSION WITH FETAL DEATH (GROSS DIAGNOSIS)
3) BRAIN, ANTERIOR HIPPOCAMPUS: LOCALLY EXTENSIVE, SUBACUTE NEURONAL NECROSIS WITH SPHEROIDS AND VACUOLATION IN DENTATE GYRUS AND PYRAMIDAL CELL LAYERS OF THE HIPPOCAMPUS
4) BRAIN, HIPPOCAMPUS AND PIRIFORM LOBE: FOCAL LAMINAR MALACIA WITH GITTER CELLS AND NEOVASCULARIZATION
5) BRAIN, RHINENCEPHALON: ACUTE TO SUBACUTE, LAMINAR CORTICAL NECROSIS WITH CAPILLARY HYPERPLASIA
6) PLACENTA: ACUTE, MODERATE, MULTIFOCAL PLACENTITIS
7) BODY AS A WHOLE: FIBRINOUS AND CELLULAR (NEUTROPHILIC) MICROVASCULAR THROMBI SUGGESTIVE OF ACUTE SEPSIS
8) LIVER: MULTIFOCAL TO SUBACUTE HEPATITIS WITH INTRALESIONAL BACTERIA
9) LYMPH NODE: LYMPHADENITIS WITH EOSINOPHILS AND FOCAL GRANULOMA, PRESUMED PARASITIC
10) COLON: MILD, SUPERFICIAL, NECROTIZING COLITIS WITH CRYPT ABSCESSATION AND GLAND ECTASIA WITH ADHERENT FILAMENTOUS BACTERIA
11) LUNG: MILD, ACUTE TO SUBACUTE, INTERSTITIAL PNEUMONIA WITH SEPTAL AND ALVEOLAR LEUKOCYTOSIS
12) NASOPHARYNX: MODERATE LYMPHOCYTIC AND PLASMACYTIC PHARYNGITIS ASSOCIATED WITH ACARIASIS (ORTHOHALARACHNE PRESUMPTIVE)
13) TRACHEA: MODERATE LYMPHOCYTIC TRACHEITIS
14) EYE: CHRONIC ULCERATIVE KERATITIS WITH MARKED PHAKOLYSIS AND ACUTE RETINAL DETACHMENT, PROBABLE TRAUMATIC ETIOLOGY
15) EYE: ACUTE CORNEAL EDEMA AND ULCERATION WITH PROTEIN LEAKAGE INTO ANTERIOR CHAMBER
16) LUNG: PULMONARY NEMATODIASIS (PARAFILAROIDES PRESUMPTIVE)
17) ADRENAL: DIFFUSE CORTICAL HYPERPLASIA
18) CLITORIS/VULVA: FOCAL ENCAPSULATED NEMATODE LARVAE
19) SPLEEN: DIFFUSE, SEVERE CONGESTION WITH CAPSULAR

DEC 1998
DISTRIBUTED

AND TRABECULAR SIDEROFIBROSIS
20) PANCREAS: MILD, MULTIFOCAL, CHRONIC, NEUTROPHILI PANCREATITIS

CLINICAL ABSTRACT:

This adult, female, California Sea Lion was a victim of the unusual mortality event characterized by seizures in California Sea Lions off the Central California coast. She was stranded at Pismo Pier in San Luis Obispo County on 5/23/98 and was admitted to the Marine Mammal Center the same day. She died on 6/1/98 and a postmortem was performed the same day at 9:30 in the morning. She was an adult female with a standard length of 176 cm, axillary girth 115 cm, umbilical girth 116 cm, blubber depth 21 mm, weight 105 kg and a somatic index scale of 4/7. Postmortem was performed by Dr. T. Spraker. Main findings were fibrin in the anterior chamber of the right eye. A counter clockwise 180 degree uterine torsion with fetal death, and severe hemorrhage and congestion of the placenta. The fetus was estimated to be dead 2-3 days. A few nematodes were present in the stomach and a few tapeworms in the ileum. Lymph nodes were within normal limits.

GROSS DESCRIPTION:

The specimen was trimmed by Dr. Hendrick Nollens, a veterinary prosector. The specimen consist of a bag with formalin and tissue samples marked "CSL 3796 Kristin 6-1/98". Tissues are recognized as the brain, two eyes, one piece of glottis, two pieces of heart, uterus, kidney, spleen, liver, lung, one piece o skin, trachea, pancreas, tongue, tonsil, fascia and vessel, salivary gland, two lymph nodes, two pieces of adrenal and stomach, two thyroids, two pieces of intestines for a total of 35 samples. The tissues were trimmed 7/13/98 and bra was missing. Extra brain was submitted 11/21/98.

HISTOPATHOLOGICAL SUMMARY:

The following tissues were examined microscopically: (T1) tongue, kidney, liver, heart, lung; (T2) stomach, skin, vagina with clitoris, trachea, muscle, diaphragm; (T3) thyroid, lymph node X2, heart, thyroid; (T4) salivary gland, placenta, spleen; (T5) colon/cecum, colon, nasal, oropharynx; (T6) adrenal, tonsil, pancreas, lymph node X2; (T7) eye; (T8) eye; (T9) brain, frontal corte (T10) ventral anterior tip of hippocampus, thalamus; (T11) ventral piriform at infundibulum right side and portion of hippocampus; (T12) pons, cerebellum; (T13) ventral cortex; (T14) midbrain; (T15) cerebellum, medulla.

COMMENT:

Uterine torsion with in utero fetal death has led to placentitis and acute sepsis which is reflected in the hepatic and pulmonary lesions. Colitis may ha also contributed. The brain lesions are impressive and focally very severe. The distribution supports the clinical diagnosis of domoic acid intoxication. The chronicity of the lesions is compatible with a 7-8 day interval between stranding and death.

la

Linda J. Lowenstine
L.J. LOWENSTINE, DVM, PhD

Veterinary Medical Teaching Hospital
University of California, Davis

05Aug98 at 4:36pm.

PATHOLOGY BIOPSY
FINAL REPORT

CLINIC NO.:
SPECIES: OTHER SMALL ANIMAL
BREED: SEA LION
SEX: F **LIFESTAGE:** ADULT
TAG NO.: CSL#3800, LADYBUG
CLINICIAN: No Doctor #
OWNER: MARINE MAMMAL CNTR ATTN: EILEEN ECONOMY
ADDRESS: Golden Gate Nat'l Rec Area Bldg 1044
Sausalito, CA 94965

PATHOLOGY NO.: 98B 1366
DATE REQUESTED: JUNE 4, 1998
RESIDENT: P. SILVAGNI, DVM
PATHOLOGIST: L.J. LOWENSTINE, DVM,PhD

****

SPECIMEN: CARCASS **PRESERVATIVE:** REFRIG. **DATE REPORTED:** AUG 5, 1998

****

PATHOLOGIC DIAGNOSIS:

1) BRAIN, HIPPOCAMPUS: SEVERE, SUBACUTE, ZONAL TO MULTIFOCAL ISCHEMIC NECROSIS
2) BRAIN: SEVERE, CHRONIC, MULTIFOCAL, LYMPHOCYTIC AND RARELY NEUTROPHILIC MENINGOENCEPHALITIS, THICK LYMPHOCYTIC PERIVASCULAR CUFFING, AND MULTIFOCAL NODULAR GLIOSIS
3) LUNG: MILD, ACUTE, MULTIFOCAL, SUPPURATIVE BRONCHOPNEUMONIA
4) COLON: MODERATE, ACUTE, DIFFUSE MUCOSAL NECROSIS
5) PLACENTA: MODERATE, ACUTE, MULTIFOCAL, NECROTIZING AND SUPPURATIVE PLACENTITIS
6) UTERUS: MODERATE, ACUTE, MULTIFOCAL NEUTROPHILIC METRITIS AND SUBMUCOSAL HEMORRHAGE
7) LIVER: MODERATE, SUBACUTE, MULTIFOCAL, LYMPHOCYTIC AND NEUTROPHILIC PERIPORTAL HEPATITIS
8) LIVER: MILD, MULTIFOCAL, GRANULOMATOUS HEPATITIS CONSISTENT WITH PARASITIC MIGRATION
9) EYE: MODERATE, ACUTE, MULTIFOCAL, SUPPURATIVE ULCERATIVE KERATITIS
10) LUNG: MILD, CHRONIC, HISTIOCYTIC AND PLASMACYTIC INTERSTITIAL PNEUMONIA
11) LUNG: PULMONARY NEMATODIASIS
12) LYMPH NODE: MILD, ACUTE, MULTIFOCAL LYMPHADENITIS WITH INTRALESIONAL PARASITES
13) STOMACH: ASCARIDIASIS

CLINICAL ABSTRACT:

This is a California Sea Lion #3800 named Ladybug. This adult female sea lion stranded at Moss Landing PE & E plant on 5/26/98 in Monterey County. She was admitted to the Marine Mammal Center on 5/26/98 and she died the next day at 5:00 p.m.. A postmortem was performed that same day by Dr. Frances Gulland. Her standard length was 168cm, blubber depth was 14mm, axillary girth was 95cm, umbilical girth was not performed, and she weighed 86kg. Her somatic index was rated 6 out of 7. Clinical symptoms included seizures and a purulent discharge from both eyes. She was not given any treatment before death.

GROSS NECROPSY:

The gross necropsy revealed included a 67cm standard length fetus which had a 42cm axillary girth. The fetus was female and the amniotic fluid was opaque and green. There were fibrin tags on the corneal surface and the brain was congested and hot to the touch. There was purulent fluid exuding from the

AUG 1998
DISTRIBUTED
TO
CLINICIAN

conjunctiva. Two volcanic ulcers were seen on the gastric mucosa and the rest of the GI tract was empty. The colon and rectum contained dry hard feces. The urinary bladder was distended and contained approximately 200cc of pale yellow urine. The bladder mucosa was deep purple. There was blood tinged mucus in the trachea and bronchi.

GROSS DESCRIPTION:

Submitted is a single large formalin bucket which contains the entire brain minus the left frontal cortex, both eyes, liver, kidney, several sections of gastrointestinal tract, heart, ovary, adrenal and other unidentified sections. Representative samples were placed in blue biopsy cassettes labelled "98B1366".

HISTOPATHOLOGICAL SUMMARY:

The following tissues were examined microscopically: (T1) left anterior hippocampus and geniculate body; (T2) brain; (T3) left caudal hippocampus; (T4) right anterior hippocampus; (T5) right caudal hippocampus; (T6) lymph node, bladder, adrenal; (T7) esophagus, duodenum, gallbladder, colon, pancreas; (T8) brain-medulla; (T9) spleen, liver, kidney; (T10) lung; (T11) cerebellum; (T12) spinal cord, caudal brainstem; (T13) hippocampus; (T14) stomach, peripheral nerve, lymph node, colon; (T15) eye; (T16) stomach, jejunum, uterus; (T17) bladder, jejunum, pancreas, lymph node; (T18) ovary, placenta, heart; (T19) lymph node, adrenal, pancreas.

COMMENT:

The severe neuronal necrosis is most severe in dentate gyri and CA3 but other CA sectors and ventral rostral gyri (pyriform lobe) are also affected. This distribution is compatible with excitotoxin damage. CA1 (the area most sensitive to hypoxia) is affected but much less so and is compatible with hypoxia secondary to seizures. There was some small vessel congestion and endothelial swelling in areas of acute necrosis. The generally non-suppurative meningoencephalitis is most severe in anterioventral portions of the brain. The severe cuffing and nodular multifocal gliosis appears to be of longer duration than the acute changes and may have been pre-existing. No etiologic agent was recognized but likely candidates are protozoal or viral. The pulmonary lesion may be secondary to aspiration pneumonia. The colonic lesions are associated with filamentous bacteria and may be a reflection of GI stasis. There is one foci of deeper necrosis. The placentitis and endometritis may have been secondary to fetal death. The lesions in liver and lymph node are related to parasitic migration.

la

P. SILVAGNI, DVM

Veterinary Medical Teaching Hospital
University of California, Davis

06Aug98 at 11:33am.

PATHOLOGY BIOPSY
FINAL REPORT

CLINIC NO.:
SPECIES: OTHER SMALL ANIMAL
BREED: SEA LION
SEX: F **LIFESTAGE:** ADULT
TAG NO.: CSL#3801, WHISPER, TAG#13185
CLINICIAN: No Doctor #
OWNER: MARINE MAMMAL CNTR ATTN: EILEEN ECONOMY
ADDRESS: Golden Gate Nat'l Rec Area Bldg 1044
Sausalito, CA 94965
COMMENT: WEIGHT: 83 KG.

PATHOLOGY NO.: 98B 1364
DATE REQUESTED: JUNE 4, 1998
RESIDENT: P. SILVAGNI, DVM
PATHOLOGIST: L.J. LOWENSTINE, DVM,PhD

****

SPECIMEN: CARCASS **PRESERVATIVE:** REFRIG. **DATE REPORTED:** AUG 5, 1998

****

PATHOLOGIC DIAGNOSIS:
1) BRAIN, VENTRAL HIPPOCAMPUS: MODERATE, SUBACUTE, MULTIFOCAL GLIOSIS, CA4 NEURONAL DROP-OUT, AND NEOVASCULARIZATION
2) BRAIN: MODERATE, CHRONIC, MULTIFOCAL LYMPHOCYTIC MENINGITIS AND CHOROIDITIS

CLINICAL ABSTRACT:

This adult, female, California Sea Lion stranded at Oceanic Dunes in San Luis Obispo on 5/25/98. She was admitted to the Marine Mammal Center that same day and was euthanzied six days later. Postmortem was performed that same day by Terry Spraker. Her standard length was 164 cm, blubber depth was 21 mm, axillary girth was 102 cm and the umbilical girth was 81 cm. She weighed 83 kg and was given a somatic index of 5/7. Her clinical signs were repeated seizures and opisthotonos. The gross necropsy revealed slightly reddened tonsils. There was excessive gray mucoid material in the esophagus. The stomach contained 10-11 large ulcers and small numbers of parasites. There were a few Acanthocephalids and tapeworms. Within the uterus was a small amount of brown fluid in the left horn. There was a 1.5 cm ulcer on the ventral aspect of the left fore flipper. There were a few small yellow plaques on the splenic capsule. There was a small amount of exudate in the dorsal pharyngeal pouch. All other organs were within normal limits.

GROSS DESCRIPTION:

Submitted is a single large formalin bucket containing multiple representative tissue samples, the entire genitourinary tract, one cerebellar hemisphere, the cerebellum, and the medulla. Trimmed tissue samples are placed in cassettes labelled "98B1364EX".

HISTOPATHOLOGICAL SUMMARY:

The following tissues were examined microscopically: (T1) pineal gland; (T2) ventral hippocampus; (T3) brain; (T4) pituitary; (T5) hippocampus; (T6) bladder, uterus; (T7,T8) brain; (T9) hippocampus; (T10) brain, cortex.

COMMENT:

Lesions are consistent with the healing phase of hippocampal necrosis. The most severe gliosis is in the neuropil and not in the pyramidal cell layer. The dentate gyri remain well-populated while CA4 is discontinuous, presumably due to pyramidal cell loss. Sections of caudal hippocampi were unaffected.

a

P. SILVAGNI, DVM

DEPARTMENT OF DEFENSE
ARMED FORCES INSTITUTE OF PATHOLOGY
WASHINGTON DC 20306-6000

REPLY TO ATTENTION OF

August 11, 1998

2637697-0 00
ANIMAL, PINNIPEDIA SEA LION
CSL 3802 T "NONAME"
TPL/ELS/mab

Dr. Frances Gulland
The Marine Mammal Center
Marin Headlands, GGNRA
Sausalito, CA 984965

AFIP DIAGNOSIS:

CSL 3802 1. Cerebrum, hippocampus: Neuronal loss, segmental, moderate, with gliosis and mild lymphoplasmacytic encephalitis and choriomeningitis, California sea lion (*Zalophus californianus*), pinniped.
2. Cerebellum; brain stem; pituitary gland, pars nervosa: Encephalitis and choriomeningitis, lymphoplasmacytic, multifocal, minimal to mild.
3. Heart, right and left ventricles: Myocarditis, lymphohistiocytic, multifocal, mild, with rowing of myofiber nuclei and mild fibrosis.
4. Skeletal muscle and fibrous connective tissue: Abscesses, chronic, multiple.
5. Uterus: Pyometra, chronic, moderate.
6. Lung: Pneumonia, chronic, multifocal, mild with adult metastrongylids, etiology consistent with *Parafilaroides decorus*.
7. Stomach, fundus: Erosions, multifocal, with few adult nematodes.
8. Stomach, pylorus, submucosa: Microgranuloma, focal, with foreign material.
9. Lymph nodes, multiple, sites unspecified: Lymphoid depletion, diffuse, mild to moderate, with lymphocytolysis.
10. Adipose tissue, multiple sites: Atrophy, diffuse, moderate to severe.
11. Cecum: Cestode, intramucosal, focal.
12. Kidneys: Nephritis, interstitial and perivascular, plasmacytic and lymphocytic, multifocal, mild.
13. Aorta; haired skin; pancreas; tongue; esophagus; tonsil; colon; thyroid gland; spleen; salivary gland; adrenal glands; uterus; ovary; eye: No significant lesions.

Department of Veterinary Pathology,Building 54,Room G-117,14th St. and Alaska Ave NW,Washington, D.C. 20306-6000
Phone: 202-782-2600 DSN: 662-2600 fax: 202-782-9150 Email: afipvet@email.afip.osd.mil

Printed on Recycled Paper

2-
2637697

COMMENT: Histopathologic findings in the hippocampus, heart and lymph nodes are suspected to be chronic changes caused by domoic acid toxicosis. Causative agents were not observed in the abscesses or pyometra, but bacterial infection is likely in both cases. The atrophy of adipose tissue in multiple sites indicates that this animal was in poor nutritional condition.

Thomas P. Lipscomb, DVM, DACVP
LTC, VC, USA
Chief, Division of Veterinary
Pathology

Department of Veterinary Pathology, Building 54, Room G-117, 14th St. and Alaska Ave NW, Washington, D.C. 20306-6000
Phone: 202-782-2600 DSN: 662-2600 fax: 202-782-9150 Email: afipvet@email.afip.osd.mil

Veterinary Medical Teaching Hospital
University of California, Davis

06Aug98 at 11:22am.

PATHOLOGY BIOPSY
FINAL REPORT

CLINIC NO.:
SPECIES: OTHER SMALL ANIMAL
BREED: SEA LION
SEX: F **LIFESTAGE:** ADULT
TAG NO.: CSL#3803, OUCH
CLINICIAN: No Doctor #
OWNER: MARINE MAMMAL CNTR ATTN: EILEEN ECONOMY
ADDRESS: Golden Gate Nat'l Rec Area Bldg 1044
Sausalito, CA 94965
COMMENT: WEIGHT: 59KG

PATHOLOGY NO.: 98B 1367
DATE REQUESTED: JUNE 4, 1998
RESIDENT: P. SILVAGNI, DVM
PATHOLOGIST: L.J. LOWENSTINE, DVM,PhD

****

SPECIMEN: CARCASS **PRESERVATIVE:** REFRIG. **DATE REPORTED:** AUG 6, 1998

****

PATHOLOGIC DIAGNOSIS:

1) UTERUS: SEVERE, SUBACUTE, DIFFUSE, TRANSMURAL FIBRINONECROTIC AND SUPPURATIVE METRITIS WITH INTRALESIONAL BACTERIA AND INFARCTION
2) PERITONEUM, BLADDER: MODERATE, CHRONIC, DIFFUSE, LYMPHOCYTIC SEROSITIS
3) BRAIN: MILD, CHRONIC, MULTIFOCAL AND COALESCING, LYMPHOCYTIC MENINGOENCEPHALITIS AND CHOROIDITIS WITH MULTIFOCAL, LYMPHOCYTIC PERIVASCULAR CUFFING
4) LIVER: MILD, SUBACUTE, MULTIFOCAL, LYMPHOCYTIC PERIPORTAL HEPATITIS
5) LIVER: MULTIPLE GRANULOMAS CONSISTENT WITH PARASITIC MIGRATION
6) COLON: CESTODIASIS
7) STOMACH: NEMATODIASIS WITH MILD, MULTIFOCAL MUCOSAL EROSIVE GASTRITIS
8) KIDNEY: MILD, CHRONIC, MULTIFOCAL, LYMPHOPLASMACYTIC INTERSTITIAL NEPHRITIS
9) TONSIL: LYMPHOID HYPERPLASIA
10) THYROID: NODULAR HYPERPLASIA

CLINICAL ABSTRACT:

This is a California Sea Lion #3803 named Ouch. This adult female sea lion stranded at 635 Ocean View on 5/25/98 in Monterey County. She was admitted to the Marine Mammal Center on 5/26/98 and died the next day at 11:00 a.m.. A postmortem was performed that same day by Gene Herman. Her standard length was 154cm, blubber depth was 16mm, axillary girth was 89cm, umbilical girth was 71cm, and she weighed 59kg. Her somatic index was rated 4 out of 7. Her presenting signs were prolapsed uterus. No treatment was given.

GROSS NECROPSY:

The gross necropsy revealed a 3mm cyst on the cranial right thyroid gland, there was 500ml of blood-tinged fluid in the peritoneal cavity. The spleen was congested. The gastric mucosa was thickened and red with moderate erosion of the mucosa. There were approximately 20 ascarids in the lumen. The intestine was empty. The mesenteric lymph nodes were gelatinous and large. The urinary bladder was empty. There was a uterine prolapse with thickened necrotic tissue containing pus and necrotic mucosa.

GROSS DESCRIPTION:

Received is a single large formalin-filled jar containing and entire brain

AUG 1998
DISTRIBUTED
TO
CLINICIAN

nus the left frontal cortex, and approximately 30 sections of tissue presenting abdominal and thoracic organs. Representative samples of tissue re placed in cassettes labelled "98B1367".

STOPATHOLOGICAL SUMMARY:

The following tissues were examined microscopically: (T1) ovary; (T2) terior hippocampus; (T3) caudal hippocampus; (T4) mesenteric lymph node; (T5) ppocampus; (T6) liver, spleen, kidney; (T7) uterus; (T8) thyroid, lung, mach; (T9) stomach, jejunum (T10) uterus; (T11) cerebral cortex; (T12) dder, heart; (T13) spinal cord; (T14) pineal gland; (T15) medulla oblongata; 6) brain; (T17) hippocampus; (T18) esophagus, tonsil.

MENT:

The primary lesion is a transmural metritis which extended to include caudal ominal peritoneum. There is no evidence of excitotoxin neuronal lesions. All er lesions were incidental.

P. Silvagni DVM

P. SILVAGNI, DVM

COLORADO VETERINARY DIAGNOSTIC LABORATORY
College of Veterinary Medicine and Biomedical Sciences
Colorado State University, Fort Collins, CO 80523
Phone 970-491-1281 Fax 970-491-0320

DL#: 978-39399
Date: 6/98

Vet/Clinic: Francis Gulland/Marine Mammal Ctr
Owner: Marine Mammal Center
Animal ID: CSL 3804/Kitty #13157 **Date Specimen Taken:** 6-3-98
Species: Zalophus californianus **Breed:** Sea Lion **Age:** A **Sex:** F

History: This is an adult female Sea Lion that was found seizuring on the beach on 5-26-98, brought into the Marine Mammal Center that same day, and was euthanatized on 6-3-98.

DIAGNOSIS: 1/Neuronal necrosis and loss, severe, hippocampus and amygdaloid nuclear complex, with extensive malacia of the amygdaloid nuclear complex, brain.

2/Mild myocardial degeneration and fibrosis, heart.

3/Cyst, lymphatic, serosa, stomach.

4/Pneumonia, multifocal, chronic active, lungs, associated with parafillaroides.

5/Microfilaria, single organism observed, capillaries of myocardium, heart.

COMMENTS: The lesions in this animal are compatible with the healing phase of a severe insult to the brain resulting in extensive necrosis and malacia of structures of the limbic system. These lesions are compatible with demoic acid toxicity. The mild lesions of the heart are probably also associated with a demoic acid toxicity. The other lesions found are most likely incidental findings and are of little importance.

GROSS NECROPSY: The animal is in poor body condition. There are several healing ulcers in the stomach. Two siderotic plaques are present on the spleen. The bile duct has a moderate number of flukes and nematodes are present within the stomach. There are two small cyst-like structures on the surface of the uterus. The

animal is not pregnant but the degree of vascularity indicates this animal probably was pregnant in the past. A few tapeworms are present in the ileocecal colic junction area.

HISTOPATHOLOGY: 1/Rhinocephalon - The olfactory stria and cortical tissue is within normal limits. The rhinocephalic cortex is also normal. The caudate nucleus is normal.

2/Caudate nucleus - This section of corporis colosum contains a few holes and the axons are gone within these holes, suggesting axonal loss. Section of internal capsule in this region also shows just a few holes with loss of axons. Caudal nucleus/septal nucleus are normal. Olfactory stria in this region is normal but a small part of the rhinocephalon does contain a few extra holes at this level, and there is evidence of neuronal necrosis and mild lymphoplasmacytic cuffing with mild neuropil edema. Globus palatus is normal.

3/Thalamus/mid-region - This section contains optic chiasm which is normal. The hypothalamic nuclei are within normal limits. The paraventricular nucleus of the thalamus is characterized by neovascularization with diffuse gliosis and mild lymphoplasmacytic cuffing with neuronal degeneration and dropout. There is also a moderate number of lymphocytes and plasma cells located within the neuropil in this specific nucleus. The next nucleus is the medial dorsal nucleus which does contain a mild degree of gliosis but does not have severe lesions as the paraventricular nucleus. The next nucleus in line is the anterior medial and it is normal. A few holes are scattered throughout the internal capsule. The interior commissure is normal. Hypothalamic nuclei are normal. Corporus colosum has just an occasional hole. The fornix of the hippocampus is normal within this region. There are a moderate number of small mineralized foci within the choroid plexus and only a slightly increased number of lymphocytes and plasma cells within the choroid plexus at this level.

4/Mid-thalamus - The optic chiasm is normal. Hypothalamic nuclei are normal. There is a mild degree of gliosis and a few extra holes and neuronal necrosis and dropout within the medial dorsal nucleus of the thalamus. This lesion is also present in the tailend of the paraventriculus nucleus also. The other nuclei of the thalamus in this region are all within normal limits. The anterior portion of the amygdaloid nuclear complex is present on this slide and there is a mild degree of lymphocytic cuffing of the vessels in this region.

Thalamus at level of pituitary stalk - The posterior aspect of the hypothalamus is relatively normal and the neural hypothesis and stalk of the pituitary gland is normal. There are a few holes and several necrotic neurons in the dorsal medial and ventral medial hypothalamic nuclei. There is also a mild edema in this area and mild gliosis. The remaining nuclei of the thalamus in this region are within normal limits. Optic tract is normal. A few holes are still found within the internal capsule. There is extensive neovascularization and malacia with neuronal necrosis and dropout, and lymphoplasmacytic cuffing of vessels within the amygdaloid nuclear complex. A mild increased number of lymphocytes and plasma cells are also found within the meninges in these areas. Within the area of malacia, there are numerous gitter cells associated with this relatively large area of malacia. Eosinophilic neurons can still be observed in this section but they are not numerous.

6/This is the dorsal half of the thalamus from Slide 5. The stria medullaris thalami is normal. A few axons have undergone degeneration and are associated with edema within the corporus collosum in this region. The cortical gray in this area is normal.

7/Thalamus/level of habenular nucleus - There is an interesting lesion, both within the medial and lateral mamillaris nucleus. In both of these nuclei, there is an extensive degree of paraneuronal edema with moderate central chromolysis of the neurons. Neuronal necrosis is not observed. Gliosis and lymphocytic plasmacytic infiltration is also not present. Cross-section of optic nerve in this region is normal. Section of pituitary gland, both pars anterior and pars nervosa, is within normal limits. A moderate number of neurons in the ventral caudal lateral and ventral caudal medial nuclei of the thalamus have a lacy appearance to the cytoplasm. This section has an area of amygdaloid nuclear complex and this lesion contains extensive malacia as previously described. This section of posterior caudal aspect of hypothalamus is characterized by extensive loss of neurons within the parietal cell layer and molecular cell layer. There is also gliosis throughout this region and numerous eosinophilic droplets which are degenerated neurons. Neuronophagia is not a prominent feature in this area. Lymphocytic plasmacytic cuffing is also not prominent in the hippocampus in this region. A few small areas of acute hemorrhage are present but this is probably an artifact.

9/Hippocampus in the mid-region - The hippocampus is identical to that previously described, but in this area, there are several

vessels that are cuffed with a few lymphocytes and plasma cells. The lateral geniculate body is on this slide and it is within normal limits. An area of malacia is found within the amygdaloid nuclear area.

10/Same as Slide 9/hippocampal nuclear loss.

11/Brain stem/pons/superior canaliculus - The superior canaliculus is normal. A small cyst near the edge of the central gray substance in this region is present. A few basophilic bodies in this cyst are observed. This is probably a degenerated neuron and not a protozoan cyst, but it is somewhat difficult to tell. If it is a protozoan cyst, it is a protozoan cyst that is undergoing degeneration. The nuclear area and fibers of the pontine area are within normal limits. The intrapeduncular nucleus is also normal. This section of hippocampus contains numerous holes in a few areas of the molecular layer. These areas are suggestive of edema. There also appears to be a loss of Purkinje cells in this area but the molecular layer is normal.

Section of obex - Nuclei in this region and large white matter tracts are considered normal. There are one or two holes in the cuneate nucleus but it is difficult to tell the significance of these holes.

Section of cerebellum is normal.

13/Spinal cord/C1 - The spinal cord, adjacent spinal nerves and dorsal root ganglia are all within normal limits.

Trigeminal nerve - No significant lesions (NSL).

Cerebrum - This section is taken from the parietal lobe and it is considered to be within normal limits.

Lungs - There are several areas in which alveolar spaces are partially filled with lymphocytes, macrophages, plasma cells, and a few neutrophils. These areas of inflammation are also present within alveolar walls and terminal bronchioles. A few sections of immature and mature nematodes are found throughout this section of lung.

15/Heart - There are a few areas in which there is an extremely mild degree of edema, probably within the T-system of the heart and there are a few areas in which there is real early fibrosis with plasmacytic infiltration associated with degenerated

myocardial cells. There is one longitudinal section of a microfilaria in a capillary. The Purkinje fibers of the heart are normal.

Liver - There are a few areas of infiltration of inflammatory cells within the liver and lymphoid follicles, and these are most likely associated with parasitism.

Skeletal muscle - NSL.

Kidneys - There are a few small focal areas of lymphoid infiltration within the interstitial tissues of the kidney, but these lesions are relatively minor.

Urinary bladder - NSL.

Stomach - This section contains two cysts that are lined by extremely thin endothelial cells. These are probably just small isolated lymphatic cysts. The mucosa of the stomach is normal in this region.

18/Mesenteric lymph nodes - These lymph nodes are relatively active. There are a few areas of scarring in these nodes which are probably old abscesses or granulomas associated with parasites. Mesenteric vessels are considered to be within normal limits.

Small intestines - Lymphoid follicles are relatively active and the mucosa of these sections are normal.

Colon - NSL. Myenteric plexus, both of the small intestines and colon, are normal.

Thyroid gland - NSL.

Adrenal gland - There are a few areas in the zona glomerulosa that contains numerous holes. The cause of this specific lesion is not known but is relatively common.

Vibrissi - NSL.

Uterus - This section is inactive and considered normal.

Ovary - This section is relatively inactive. Another section of ovary has a large corporus albicans.

Mesenteric lymph node - This lymph node is relatively active and considered to be normal.

Terry Spraker, DVM/PhD

Typed: 6-19-98 ml

COLORADO VETERINARY DIAGNOSTIC LABORATORY
College of Veterinary Medicine and Biomedical Sciences
Colorado State University, Fort Collins, CO 80523
Phone 970-491-1281
Fax 970-491-0320

DL#: 978-39400
Date:

Vet/Clinic: Francis Gulland
Owner: The Marine Mammal Center
Animal ID: Flower CSL3806 **Date Specimen Taken:**
Species: Z. californias **Breed:** **Age:** Adult **Sex:** F

History: This is an adult California sea lion number CSL3806 name is Flower, tag number is 13155. This female was found to be in convulsions and brought into the marine mammal center on 5/27/98. The animal not improved and was euthanized on 6/1/98.

DIAGNOSIS:
1. Interstitial nephritis, mild, lymphoplasmacytic with tubular atrophy and dilatation, kidney.
2. Thymic atrophy, moderate, lymphoid tissue, thymus.

REMARKS: The histological lesions typically seen in the adult females with dumoic acid toxicity were not found in this animal either in the acute phase or in the more chronic recovery phase. This animal did have a pup probably several weeks ago. There was really no evidence of a pyometra or any type of infection within the uterus. The mild inflammation of the kidney may be associated with lepto, however the overall severity was considered mild and would not have lead to the death of this animal.

GROSS NECROPSY: Small degree of fibrin present on the pericardial surface. A few adhesions are found between the mesentery and the liver. The gall bladder wall is thickened. The bile ducts are filled with flukes. There is a 3mm cyst cranial to the pole of the right kidney, heavy infection of small nematodes are present within the stomach and several ulcers ranging from .75 to 1.5 cm in diameter are present in the mucosa. The stomach and small intestines are fairly empty except for a small amount of mucoid material. A placental attachment is present in the right uterine horn but this animal probably gave birth at least a week ago.

HISTOPATHOLOGY: Slide 1: Olfactory bulb and stria and mesencephalon: No lesions are found on this slide.

Slide 2: Caudate nucleus: The cingulate gyrus, corpus callosum, septal nucleus, caudate nucleus, and globus palates are all within normal limits. There are a few holes in the internal capsule but very few. The olfactory stria and olfactory cortex at this level are normal.

Slide 3: Thymus, anterior region: This region contains several of the anterior medial and anterior dorsal nuclei of the thalamus. All of these nuclei are within normal limits including the paraventricular nucleus. The posterior aspect of the optic chiasm and internal capsule are normal in this region.

Thalamus, mid region: The thalamic nuclei in this area are normal. A section of hypothalamic nuclei specifically superoptic are all within normal limits. Optic tracts in this region are normal. The amygdaloid nuclear complex in this region is normal. The putamem or at least base of nuclei which it looks like the globus palates and clostrum are all within normal limits.

Slide 5: Thalamus, mid region, internal capsule and optic tracts are normal.

Putamem: There are a few vessels cuffed within the putamem but the clostrum is normal. The internal capsule is within normal limits. Nuclei of the caudal lateral and caudal medial nuclei are relatively normal. This section contains an area of posterior hippocampus and amygdaloid nuclear complex. Both of these structures are within normal limits.

Slide 6: This section contains mid thalamic nuclei and hippocampus. All of these areas are within normal limits. There are a few holes in the internal capsule without axons but they are minimal. There is one vessel within the stratum radiatum that is cuffed with a few lymphocytes but the molecular layer and granular cell layer are relatively normal.

Slide 7: This section is of a thalamus and cortex including cingulate gyrus and corpus callosum. All of these structures are within normal limits. The fornices of the hippocampus is also normal.

Slide 8: Hippocampus: This section is taken from the mid to slightly posterior aspect of the hippocampus. No lesions are found within hippocampus or dentate gyrus.

Slide 9: Hippocampus: This section of hippocampus is taken in the middle of the organ. There may be a mild degree of edema of the neuropil in this region and an extremely mild increased glial cells throughout but there is really no evidence of neuronal necrosis.

Slide 10: Brain stem level of the pineal body and oculomotor nucleus: The oculomotor nerve is normal in this region. The pineal body and superior cuniculus is normal. The gray matter, oculomotor nucleus, red nucleus and substantia nigra are within normal limits.

Slide 11: Brain stem level of tegmental nucleus and pons: All structures from this slide are within normal limits.

Cerebellum in this region does contain a few Purkinje cells that show mild to moderate central chromolysis but the molecular layer and granular layer and white matter are all within normal limits.

Slide 12: Cerebellum and obex: This section of cerebellum and roof nuclei are within normal limits. The hypoglossal nucleus, dorsal nucleus of vagus nerve, nucleus of spinal tract, trigeminal nerve and olivary nuclei are all within normal limits. There are a moderate number of holes within the cuneate nucleus that appear to be perhaps areas of neuropil edema.

Slide 13: Adrenal gland: No significant lesions.

Thyroid gland: No significant lesions.

Spinal cord and spinal nerves: No significant lesions.

Pancreas: No significant lesions.

Tonsil: The lymphoid tissue is severely atrophied throughout the tonsil.

Lungs: This section of lungs does contain a few areas of lymphocytes and plasma cells and macrophages, both around terminal bronchioles and within alveolar spaces. The degree of inflammation is extremely small. Cross sections of parasites are not observed in these two sections of lungs but the small areas of inflammation are probably associated with parasitic activity. There is one large area of air trapping.

Heart: There is a moderate amount of fibrin admixed with a few neutrophils on the surface of the epicardium around the large coronary vessels. There is an extremely mild degree of separation between some of the myocardial cells but is hard to distinguish if this is edema or not. There is an occasional area where there does appear to be edema and very early or mild myocardial degeneration.

Slide 16: Small intestines: No significant lesions.

Myentery plexus: No significant lesions.

Liver: There are a few focal areas of lymphocytes and plasma cells scattered throughout the liver parenchyma. These are usually associated with parasitic activity. The hepatocytes are slightly atrophied.

Large intestines: No significant lesions.

Gall bladder: The gall bladder is slightly thickened due to mild fibrosis. There is an extensive infiltration of lymphocytes and plasma cells within the lamina propria of the gall bladder.

Slide 17: Mesenteric lymph node: This lymph node is active and considered to be within normal limits.

Adrenal gland: No significant lesions.

Kidneys: This section of kidneys does contain a few areas in which there is an infiltration of lymphocytes and plasma cells. Associated with these areas are dilated tubules. In a few other areas there is slightly more inflammation and the inflammation is often surrounding atrophied tubules that contain eosinophilic proteinaceous fluid. The degree of inflammation in the kidneys is considered minimal.

Stomach: This section of stomach contains a large ulcer that progresses down into the mid region of the submucosa. Numerous parasites are present in the bed of this ulcer. Extensive infiltration of lymphocytes, plasma cells with a few macrophages and neutrophils are present within the bed of the ulcer. These are typical parasitic volcanic ulcers of the stomachs of California sea lions.

Slide 19: Lymph nodes: Multiple lymph nodes are examined, both peripheral and mesenteric. All are within normal limits.

Pancreas: No significant lesions.

Slide 20: Ovaries and uterus: One section of ovary contains a large degenerated corpus luteum and the other ovary is relatively inactive. One section of uterus is also inactive but the other section does contain extensive hemorrhage and proliferation of endometrial cells. There is one area that is suggestive of a retained portion of placenta. This animal probably had a pup several weeks prior to its death.

Terry R. Spraker/DVM, PhD

Typed: 6/19/98 lm

Veterinary Medical Teaching Hospital
University of California, Davis

24Nov98 at 8:45am.

PATHOLOGY BIOPSY
FINAL REPORT

CLINIC NO.:
SPECIES: OTHER SMALL ANIMAL
BREED: SEA LION
SEX: F **LIFESTAGE:** ADULT
TAG NO.: CSL #3824 (SADY) (TAG 13107)
CLINICIAN: No Doctor #
OWNER: MARINE MAMMAL CNTR ATTN: EILEEN ECONOMY
ADDRESS: Golden Gate Nat'l Rec Area Bldg 1044
Sausalito, CA 94965
COMMENT: WEIGHT: 63.5 KG.

PATHOLOGY NO.: 98B 1415
DATE REQUESTED: JUNE 9, 1998
RESIDENT: L.J. LOWENSTINE, DVM,PhD

****

SPECIMEN: BIOPSY TISSUE **PRESERVATIVE:** FORMALIN **DATE REPORTED:** NOV 23, 1998

****

PATHOLOGIC DIAGNOSIS:

1) SEIZURES ASSOCIATED WITH DOMOIC ACID TOXICITY (CLINICAL DIAGNOSIS)
2) BRAIN, VENTRAL ANTERIOR HIPPOCAMPUS: MILD GLIOSIS AND INCREASE IN CAPILLARIES IN CA3 AND CA4
3) BRAIN: MILD, NONSUPPURATIVE MENINGOENCEPHALITIS AND CHOROIDITIS
4) BRAIN, MEDULLA: MARKED SYMMETRICAL VACUOLATION OF DORSAL NUCLEI (DORSAL MOTOR NUCLEUS OF THE VAGUS OR CUNEATUS ?)
5) VAGINA: MARKED, DIFFUSE EPITHELIAL HYPERPLASIA WITH MILD DYSPLASIA AND MILD, MULTIFOCAL, LYMPHOPLASMACYTIC AND SUPPURATIVE VAGINITIS
6) SUBLUMBAR LYMPH NODES: METASTATIC CARCINOMA WITH EXTENSIVE ACUTE NECROSIS AND SUPPURATIVE LYMPHADENITIS
7) ADRENAL: CORTICAL HYPERPLASIA OF ZONA GLOMERULOSA AND FASCICULATA WITH MILD TO MODERATE VACUOLATION
8) LIVER: MODERATE CENTRILOBULAR LIPIDOSIS AND MILD, DIFFUSE PIGMENTARY HEPATOPATHY (HEMOSIDEROSIS, PRESUMPTIVE)
9) GALLBLADDER: CHRONIC, LYMPHOCYTIC CHOLECYSTITIS AND CHOLEDOCHITIS ASSOCIATED WITH LUMINAL TREMATODES (SEE GROSSLY), ZALOPHATREMA HEPATICUM PRESUMPTIVE
10) SMALL INTESTINE: LYMPHOID HYPERPLASIA WITH FOCAL MURAL PARASITIC GRANULOMA
11) COLON: MILD, MULTIFOCAL COLITIS WITH CRYPT ABSCESSATION ASSOCIATED WITH MILD CESTODIASIS (CESTODE LARVAE IN CRYPTS)
12) LUNG: MILD, MONONUCLEAR INTERSTITIAL PNEUMONIA AND MILD PULMONARY NEMATODIASIS, PARAFILAROIDES, PRESUMPTIVE
13) RIGHT UTERINE HORN: CYSTIC ENDOMETRIAL HYPERPLASIA WITH MODERATE HEMORRHAGE, POST-PARTURIENT

LINICAL ABSTRACT:

This adult female California Sea Lion was stranded at Cochran Lagoon in anta Cruz on 5/29/98 and was admitted to the Marine Mammal Center the same day. he had seizures and delivered a stillborn fetus. Based on continued seizures n poor response to therapy, the animal was euthanized on 6/3/98 and posted

NOV 1998
DISTRIBUTED
TO
CLINICIAN

mmediately post-euthanasia by Dr. Terry Spraker. The animal had a standard ength of 171 cm, axillary girth of 96 cm, umbilical girth of 90.5 cm and a eight of 63.5 kg. No somatic index score was given. On gross postmortem, Dr. praker noted that the right uterine horn was enlarged and thickened with an dematous mucosa and hemorrhage in the lumen of the uterus and vagina. Three mall, 3-6 mm, pale white masses were present on the endothelium of the vaginal ornix. Two firm lumpy masses, presumably sublumbar lymph nodes, were found. Th ne on the left measured 6 x 4 x 3 cm and was white and firm with purulent aterial on cut section. On the right side, the mass was 4 x 3 x 3 cm with no ovious pus. Four shallow healing gastric ulcers were seen along with some ematodes (small and large) and flukes, were present in the gallbladder. Gross issues were examined and trimmed by Hendrick Nollen who did not describe the ross specimen.

ISTOPATHOLOGICAL SUMMARY:

The following tissues were examined microscopically: (T1) spleen, lung, ver, ovaries, salivary gland; (T2) heart, muscle, pancreas, lymph node, ngue; (T3) brain to the ventral hippocampus, central thalamus, hypothalamus; 4) pineal gland, midbrain; (T5) bladder or vagina; (T6) adrenal, lymph nodes, rvical spinal cord; (T7) hippocampus, ventral thalamus, pyriform lobe; (T8) ur lymph nodes; (T9) medulla, C1 medullary junction, pineal, choroid plexus; 10) vagina, uterus; (T11) cerebellum, pons; (T12) vagina; (T13) brain; (T14) gina, cervix; (T15) small intestine, ileum, left uterine horn; (T16) llbladder, bladder, right uterine horn; (T17) colon, esophagus; (T18) eye.

MMENT:

Although seizures were apparent clinically, there are minimal lesions in the ain of this post-parturient female California Sea Lion. Diagnosis of domoic id intoxication is made on clinical signs and epidemiologic considerations. e epithelial hyperplasia in the vagina is very interesting. Although three all nodules were seen grossly, this process appears to be fairly diffuse. ere is minimal dysplasia within this hyperplastic process and no herpetic clusions are seen to account for this change. The cells in the vagina resemble ose in the sublumbar lymph nodes except that those in the nodes have more atures of transform cells such as nuclear pleomorphism and a higher mitotic dex.

Linda J. Lowenstine

L.J. LOWENSTINE, DVM, PhD

DEPARTMENT OF DEFENSE
ARMED FORCES INSTITUTE OF PATHOLOGY
WASHINGTON DC 20306-6000

REPLY TO
ATTENTION OF

February 8, 1999

2637699-6 00
ANIMAL, PINNIPED SEA LION
CSL 3901 T "PALM"
TPL/DPS/VLM/tab

Dr. Frances Gulland
The Marine Mammal Center
Marin Headlands, GGNRA
Sausalito, CA 94965

AFIP DIAGNOSES:

CSL 3901 1. Kidney: Nephritis, interstitial, lymphoplasmacytic, chronic, multifocal, moderate, California sea lion (*Zalophus californianus*), pinniped.
2. Lung: Bronchopneumonia, granulomatous and eosinophilic, focal, moderate, with numerous intra-bronchiolar adult metastrongyles, etiology consistent with *Parafilaroides decorus.*
3. Skeletal muscle and associated adipose tissue, site unspecified: Myositis and steatitis, granulomatous, chronic, diffuse, severe, with intrahistiocytic amphophilic foreign material.
4. Liver: Fibrosis, subcapsular and portal, diffuse, moderate, with mild multifocal lymphoplasmacytic and eosinophilic hepatitis.
5. Gallbladder: Hyperplasia, cystic-mucinous, multifocal, mild with lymphoplasmacytic cholecystitis.
6. Cerebrum: Choriomeningitis and encephalitis, lymphoplasmacytic, multifocal, mild.
7. Pituitary, pars nervosa: Hypophysitis, lymphoplasmacytic, multifocal, mild.
8. Colon: Numerous luminal nematode larva and few trematode eggs.
9. Heart, atrioventricular valve: Degeneration, fibromyxomatous, focal, mild, with multifocal lymphoplasmacytic endocarditis.
10. Lymph nodes: Draining hemorrhage and edema, multifocal, mild with erythrophagocytosis.
11. Artery; vein; spleen; lymph nodes; tonsil; salivary gland; pancreas; thyroid; nasal turbinates; esophagus; stomach; small intestine; uterus, ovary, urinary bladder; haired skin; cerebellum; spinal cord; eye: No significant lesions.

Department of Veterinary Pathology,Building 54,Room G-117,14th St. and Alaska Ave NW,Washington, D.C. 20306-6000
Phone: 202-782-2600 DSN: 662-2600 fax: 202-782-9150 Email: afipvet@email.afip.osd.mil

Printed on Recycled Paper

Comment: The renal changes noted at necropsy were caused by chronic interstitial nephritis, the cause of which is not evident histologically. The bronchopneumonia was associated with numerous metastrongyle lungworms. We suspect that the intrahistiocytic foreign material in skeletal muscle and adipose tissue is an injected medication, possibly penicillin. Hepatic portal fibrosis with lymphoplasmacytic and eosinophilic hepatitis was probably caused by parasitism. Trematode eggs were observed in the lumen of the colon. The thickening of the gallbladder noted at necropsy was caused by cystic-mucinous hyperplasia. The remaining lesions are incidental findings and are considered to be clinically insignificant.

Thomas P. Lipscomb, DVM, DACVP
LTC, VC, USA
Chief, Division of Veterinary
Pathology

Dana P. Scott, DVM, DACVP
MAJ, VC, USA
Division of Veterinary Pathology

DEPARTMENT OF DEFENSE
ARMED FORCES INSTITUTE OF PATHOLOGY
WASHINGTON DC 20306-6000

REPLY TO ATTENTION OF

September 25, 1998

2637691-3
ANIMAL, PINNIPEDIA SEA LION
CSL 3931 T "WHITELIGHT"
TPL/DPS/TWB/mab

Dr. Frances Gulland
The Marine Mammal Center
Marin Headlands, GGNRA
Sausalito, CA 94965

AFIP DIAGNOSES:

CSL 3931 1. Hippocampus and meninges, multiple sites: Meningoencephalitis, lymphoplasmacytic, multifocal, moderate, with neuronal eosinophilic intracytoplasmic inclusion bodies, California sea lion, pinniped.
2. Stomach, fundus: Ulcer, focally extensive, with moderate chronic-active gastritis and numerous parasite remnants.
3. Haired skin and subcutis: Steatitis, neutrophilic and histiocytic, focally extensive, moderate.
4. Lung: Pneumonia, granulomatous, multifocal, mild, with adult nematodes, etiology consistent with *Parafilaroides decorus*.
5. Liver: Hepatitis, subacute, multifocal, mild.
6. Heart; fibroelastic artery; tongue; esophagus; small intestine; large intestine; kidney; urinary bladder; gallbladder; spleen; thyroid gland; adrenal gland; lymph nodes; pancreas; skeletal muscle; pituitary gland; eye: No significant lesions.

COMMENT: The cause of the meningoencephalitis and its relationship to the seizures observed clinically are not evident. The nature of the intracytoplasmic inclusions in neurons of the hippocampus is unclear. We will examine the affected neurons by electron microscopy and forward an addendum report when results are available. Histopathologic findings in the stomach are consistent with your necropsy diagnosis of anasakiasis. A panel of special stains did not demonstrate the cause of the subcutaneous steatitis. The pulmonary and hepatic lesions are incidental findings and are not considered to be clinically insignificant.

Thomas P. Lipscomb, DVM, DACVP
LTC, VC, USA
Chief, Division of Veterinary Pathology

Dana P. Scott, DVM, DACVP
MAJ, VC, USA
Division of Veterinary Pathology

Department of Veterinary Pathology, Building 54, Room G-117, 14th St. and Alaska Ave NW, Washington, D.C. 20306-6000
Phone: 202-782-2600 DSN: 662-2600 fax: 202-782-9150 Email: afipvet@email.afip.osd.mil

Printed on Recycled Paper

DEPARTMENT OF DEFENSE
ARMED FORCES INSTITUTE OF PATHOLOGY
WASHINGTON DC 20306-6000

REPLY TO
ATTENTION OF

February 4, 1999

2654523-6 00
ANIMAL, PINNIPEDIA SEA LION
CSL4209 T "ALICE"
TPL/DGD/ELS/mab

Dr. Frances Gulland
The Marine Mammal Center
Marin Headlands, GGNRA
Sausalito, CA 94965

AFIP DIAGNOSES:

CSL 4209 1. Mediastinum; lung; and lymph node, sublumbar: Mesothelioma, malignant, California sea lion (*Zalophus californianus*), pinniped.
2. Cervix: Intraepithelial neoplasia.
3. Lymph node, sublumbar: Adenocarcinoma, genital, metastatic.
4. Lung: Bronchopneumonia, pyogranulomatous, diffuse, severe, with numerous intra-alveolar and intrabronchiolar adult and larval nematodes, etiology consistent with *Parafilaroides decorus*.
5. Heart, myocardium, multiple sites: Degeneration and necrosis, multifocal, mild, with mineralization.
6. Heart, right ventricle: Edema, interstitial and perivascular, multifocal, mild to moderate.
7. Heart, cardiomyocytes: Karyomegaly and nuclear rowing, multifocal, mild.
8. Heart, atrium: Fibrosis, focal, mild.
9. Brain: Choriomeningitis, lymphoplasmacytic and histiocytic, multifocal, minimal, with hemosiderosis.
10. Liver: Necrosis, coagulative, centrilobular and midzonal, acute, multifocal.
11. Kidney, right (per contributor): Cystic pelvis and Bowman's spaces, diffuse, moderate, with marked interstitial fibrosis, tubule loss, and multifocal lymphoplasmacytic nephritis.
12. Small intestine; and uterus, left horn, serosa: Serositis, lymphoplasmacytic and histiocytic, multifocal, mild.
13. Adipose tissue, multiple sites: Atrophy, diffuse, mild to moderate.
14. Trachea: Tracheitis, neutrophilic and lymphoplasmacytic, diffuse, mild.
15. Liver: Hepatitis, portal, lymphoplasmacytic and histiocytic, multifocal, mild.
16. Tongue: Glossitis, lymphoplasmacytic, diffuse, mild, with epithelial hyperplasia and hyperkeratosis, and low numbers of superificial nematode larvae.
17. Adrenal gland: Adrenalitis, cortical, lymphoplasmacytic, multifocal, mild.
18. Stomach: Gastritis, chronic, multifocal, mild to moderate, with intraluminal adult nematode, etiology consistent with Anisakid nematodes.
19. Small intestine: Nematode adult, nematode larvae, and parasite eggs (two types), intraluminal, multifocal.
20. Large intestine: Cestode, intraluminal.
21. Pancreas; salivary gland; tonsil; spleen; skeletal muscle; thyroid gland; pituitary gland; lymph node, mesenteric; ovaries; and eye: No significant lesions.

Department of Veterinary Pathology,Building 54,Room G-117,14th St. and Alaska Ave NW,Washington, D.C. 20306-6000
Phone: 202-782-2600 DSN: 662-2600 fax: 202-782-9150 Email: afipvet@email.afip.osd.mil

Printed on Recycled Paper

COMMENT: This animal died of multiple organ system failure resulting from disseminated neoplasia and severe verminous pneumonia. Mesothelioma is present in the lungs and sublumbar lymph node. Intraepithelial neoplasia is present in the cervix. Interestingly, metastatic genital adenocarcinoma is present within the same lymph node as mesothelioma. The exact cause of the observed seizures is not evident histologically. Meningeal inflammation is minimal and not likely the cause. Neuronal necrosis is not evident in the examined sections of hippocampus. Myocardial degeneration and necrosis might have been caused by domoic acid toxicosis, but the lesion is nonspecific. The changes in the kidney are consistent with hydronephrosis, most likely caused by obstruction of the ureter by the sublumbar mass. Inflammation of the uterine and intestinal serosa is likely secondary to neoplasia. Fat atrophy reflects negative energy balance. Cardiac edema is an agonal change. The tracheitis is secondary to the pneumonia. Portal hepatitis is likely the result of hepatic endoparasitism described grossly. Glossitis with larval nematodes on the tongue surface is an unusual finding in our experience. There is no inflammatory response directly associated with the larvae. Their morphology closely resembles that of the intestinal nematode larvae, suggesting their location on the tongue could be an aberration. The remaining lesions are considered to be incidental findings.

Thomas P. Lipscomb, DVM, DACVP
LTC, VC, USA
Chief, Division of Veterinary
Pathology

Dale G. Dunn, DVM, DACVP
LTC, VC, USA
Division of Veterinary Pathology

8/98

DEPARTMENT OF DEFENSE
ARMED FORCES INSTITUTE OF PATHOLOGY
WASHINGTON DC 20306-6000

REPLY TO
ATTENTION OF

January 20, 1999

2649842-8 00
ANIMAL, PINNIPED SEA LION
CSL 4162 T GULLAND OWNER
WI/DPS/TJA/tab

Dr. Frances Gulland
The Marine Mammal Center
Marin Headlands, GGNRA
Sausalito, CA 94965

AFIP DIAGNOSES:

CSL 4162 1. Kidney, glomeruli and interstitium: Amyloidosis, multifocal, moderate to severe, with mild lymphoplasmacytic nephritis, California sea lion (*Zalophus californianus*), pinniped.
2. Lung: Congestion and edema, acute, diffuse, mild to moderate.
3. Liver: Fibrosis, centrilobular, multifocal, moderate, with mild lymphoplasmacytic inflammation.
4. Omentum: Inflammation, lymphoplasmacytic, chronic, diffuse, mild, with villous proliferation.
5. Fibrocartilaginous nodule (site not specified): Consistent with fetal remnant.
6. Lung, bronchioles: Adult metastrongyles, numerous, etiology consistent with *Parafilaroides decorus.*
7. Cervix: Cervicitis, lymphoplasmacytic, multifocal, mild.
8. Adrenal gland, cortex: Extramedullary hematopoiesis, multifocal, mild.
9. Lymph node: Edema, diffuse, mild.
10. Heart; and uterus: No significant lesions.

COMMENT: The most likely cause of death in this sea lion is renal failure secondary to glomerular and interstitial amyloidosis. Pulmonary edema may have contributed to death. Centrilobular hepatic fibrosis usually reflects some degree of right-sided heart insufficiency. The chronic omental inflammation is due to the fetal remains you noted in the abdomen at necropsy. An unidentified nodule consisting of fibrocartilaginous tissue is consistent with a skeletal portion of that fetus. The remaining lesions are incidental findings and are not considered to be clinically significant.

Thank you for submitting this case; it will be maintained in the archives of the Registry of Veterinary Pathology.

William Inskeep II

William Inskeep II, DVM, DACVP
COL, VC, USA
Chairman, Department of Veterinary Pathology

Dana P. Scott

Dana P. Scott, DVM, DACVP
MAJ, VC, USA
Division of Veterinary Pathology

Department of Veterinary Pathology, Building 54, Room G-117, 14th St. and Alaska Ave NW, Washington, D.C. 20306-6000
Phone: 202-782-2600 DSN: 662-2600 fax: 202-782-9150 Email: afipvet@email.afip.osd.mil

Printed on Recycled Paper

1/95

DEPARTMENT OF DEFENSE
ARMED FORCES INSTITUTE OF PATHOLOGY
WASHINGTON DC 20306-6000

REPLY TO
ATTENTION OF

January 11, 1999

2654890-9 00
ANIMAL, PINNIPED SEA LION
CSL4214 T GULLAND
TPL/BHS/tab

Dr. Frances Gulland
The Marine Mammal Center
Marin Headlands, GGNRA
Sausalito, CA 94695

AFIP DIAGNOSES:

CSL4214 1. Brain, hippocampus: Neuronal necrosis and loss, diffuse, with numerous spheroids and mild multifocal gliosis, California sea lion (*Zalophus californianus),* pinniped.
2. Heart, myocardium: Myocarditis, subacute to chronic, neutrophilic and histiocytic, multifocal, moderate, with cardiomyocyte loss and regenerative changes.
3. Brain, cerebral cortex: Neuronal necrosis, with acute inflammation.
4. Brain, meninges: Meningitis, lymphoplasmacytic, multifocal, mild.
5. Brain; spleen: Bacillary emboli, few, gram-negative in brain.
6. Liver: Hepatitis, portal, lymphoplasmacytic, diffuse, mild.
7. Liver: Hepatitis, histiocytic and neutrophilic, multifocal, mild.
8. Small intestine, crypt epithelium: Necrosis, multifocal, occasional.
9. Adipose tissue, multiple sites: Atrophy, diffuse, moderate.
10. Lung: Intrabronchiolar nematodes, multifocal, few, consistent with *Parafilaroides decorus*.
11. Stomach: Ulcers, chronic, multifocal, with nematode parasites, etiology consistent with *Anisakis* sp.
12. Mammary gland: Hyperplasia, glandular, diffuse, with secretory product.
13. Aorta; skeletal muscle; trachea; tongue; salivary gland; pancreas; tonsil; esophagus; large intestine; gallbladder; kidney; thyroid; adrenal; haired skin; spleen; lymph node; pituitary: No significant lesions.

Comment: The likely cause of death is domoic acid poisoning. The lesions in the hippocampus are similar to those observed in other sea lions believed to have been affected by this toxin. The heart lesions are generally similar to those seen in other affected sea lions, but they are more chronic. The bacillary emboli in brain and spleen indicate terminal septicemia. The cause of the meningitis is not evident; it may be secondary to the necrosis. The causes of the hepatitis and small intestinal crypt epithelial necrosis are not apparent. Fat atrophy indicates this animal was in poor nutritional condition. The other lesions are considered incidental.

TP Lipscomb

Thomas P. Lipscomb, DVM, DACVP
LTC, VC, USA
Chief, Division of Veterinary
Pathology

Department of Veterinary Pathology,Building 54,Room G-117,14th St. and Alaska Ave NW,Washington, D.C. 20306-6000
Phone: 202-782-2600 DSN: 662-2600 fax: 202-782-9150 Email: afipvet@email.afip.osd.mil

Printed on Recycled Paper

DEPARTMENT OF DEFENSE
ARMED FORCES INSTITUTE OF PATHOLOGY
WASHINGTON DC 20306-6000

REPLY TO
ATTENTION OF

January 26, 1999

2654894-1 00
ANIMAL, PINNIPED SEA LION
CSL4218 T GULLAND
TPL/TJA/tab

Dr. Frances Gulland
The Marine Mammal Center
Marin Headlands, GGNRA
Sausalito, CA 94965

AFIP DIAGNOSES:

CSL4218 1. Cerebrum: Neuronal necrosis, focally extensive, with mild multifocal lymphoplasmacytic choriomeningitis and encephalitis, California sea lion (*Zalophus californianus*), pinniped.
2. Cervix and uterus: Intraepithelial neoplasia.
3. Vagina: Vaginitis, lymphoplasmacytic, diffuse, mild.
4. Cervix: Cervicitis, lymphoplasmacytic, multifocal, mild
5. Stomach, fundus: Gastritis, lymphoplasmacytic, histiocytic, and eosinophilic, chronic, diffuse, moderate.
6. Small intestine: Enteritis, lymphoplasmacytic and eosinophilic, transmural, multifocal, mild to moderate.
7. Liver: Hepatitis, lymphoplasmacytic and eosinophilic, portal and random, multifocal, mild.
8. Lymph node, site unspecified: Edema, diffuse, mild.
9. Lymph node, site unspecified: Sinus erythrocytes, diffuse, numerous, with erythrophagocytosis.
10. Lung: Congestion, acute, diffuse, mild, with mild edema.
11. Lung: Pneumonia, interstitial, lymphoplasmacytic and eosinophilic, multifocal, mild, with few metastrongyle adults and larvae, etiology consistent with *Parafilaroides decorus*.
12. Lung and meninges: Intravascular microfilaria, multifocal, few.
13. Tongue; heart; aorta; esophagus; salivary gland; large intestine; pancreas; spleen; kidney; urinary bladder; thyroid gland; adrenal gland; diaphragm; ovary: No significant lesions.

COMMENT: The brain lesions are suggestive of domoic acid poisoning, although the examined section of hippocampus was not affected. There is intraepithelial neoplasia in both the uterus and cervix. The lymphoplasmacytic and eosinophilic inflammation in the stomach, intestine and liver is most likely due to parasitism. Pulmonary congestion and edema are nonspecific terminal changes. The remaining lesions are considered incidental findings.

Thomas P. Lipscomb, DVM, DACVP
LTC, VC, USA
Chief, Division of Veterinary
Pathology

Department of Veterinary Pathology,Building 54,Room G-117,14th St. and Alaska Ave NW,Washington, D.C. 20306-6000
Phone: 202-782-2600 DSN: 662-2600 fax: 202-782-9150 Email: afipvet@email.afip.osd.mil

Printed on Recycled Paper

10/91

DEPARTMENT OF DEFENSE
ARMED FORCES INSTITUTE OF PATHOLOGY
WASHINGTON DC 20306-6000

REPLY TO
ATTENTION OF

January 8, 1999

2654897-4 00
ANIMAL, PINNIPEDIA SEA LION
CSL4220 T
TPL/ELS/mab

Dr. Frances Gulland
The Marine Mammal Center
Marin Headlands, GGNRA
Sausalito, CA 94965

AFIP DIAGNOSES:

CSL 4220 1. Lung: Bronchopneumonia, suppurative and granulomatous, multifocal to coalescing, severe, with numerous, intra-alveolar and intra-bronchiolar, adult and larval nematodes, California sea lion (*Zalophus californianus*), pinniped, etiology consistent with *Parafilaroides decorus*.
2. Lymph nodes, sublumbar: Carcinoma, genital, adenosquamous, metastatic.
3. Vagina; cervix; uterus: Intraepithelial neoplasia, with glandular and squamous differentiation.
4. Cerebrum; cerebellum: Choriomeningitis, lymphoplasmacytic, multifocal, minimal to mild.
5. Pituitary gland, pars nervosa: Neuritis, perivascular, lymphoplasmacytic, multifocal, minimal.
6. Heart: Epicarditis, lymphoplasmacytic and histiocytic, multifocal, mild.
7. Adipose tissue, multiple sites: Atrophy, moderate.
8. Small intestine: Trematodes, intramucosal few, etiology consistent with *Pricetrema* sp.
9. Small intestine: Cestodes, intraluminal, few.
10. Spleen; pancreas; diaphragm; urinary bladder; liver; thyroid gland; adrenal gland; arteries, fibroelastic; kidneys; ovary; lymph nodes, unspecified: No significant lesions.

COMMENT: Severe verminous pneumonia is the cause of death. The cause of the seizures is not evident; hypoxia associated with respiratory compromise is likely to have been the cause. The cause of the minimal to mild lymphoplasmacytic inflammation in the meninges and pituitary gland is not apparent. No necrosis of hippocampal neurons was observed; thus, domoic acid toxicosis is unlikely. Your suspicion of neoplasia is confirmed. Widespread intraepithelial neoplasia is present in the vagina, cervix, and one uterine horn; metastatic adenosquamous genital carcinoma is present in the sublumbar area lymph nodes. Fat atrophy reflects negative energy balance. The other lesions are incidental findings.

TP Lipscomb

Thomas P. Lipscomb, DVM, DACVP
LTC, VC, USA
Chief, Division of Veterinary
Pathology

Department of Veterinary Pathology,Building 54,Room G-117,14th St. and Alaska Ave NW,Washington, D.C. 20306-6000
Phone: 202-782-2600 DSN: 662-2600 fax: 202-782-9150 Email: afipvet@email.afip.osd.mil

Printed on Recycled Paper

APPENDIX 7: LOCATION OF FROZEN SAMPLES

LOCATION OF FROZEN SAMPLES COLLECTED FROM SEA LION EVENT

ACC #	DOMOIC ACID +	FECES									URINE						BLOOD						STOMACH (contents/wash)					
		TMMC	Fran Van Dolah		Vera Trainer		Kathy Lefebvre		TMMC	Fran Van Dolah		Vera Trainer		Kathy Lefebvre		TMMC	Fran Van Dolah		Vera Trainer		Kathy Lefebvre		TMMC	Fran Van Dolah		Vera Trainer		Kathy Lefebvre	
			shipped	results	shipped	results	shipped	results		shipped	results	shipped	results	shipped	results		shipped	results	shipped	results	shipped	results		shipped	results	shipped	results	shipped	results
DECEASED:																													
NFS 123	U	x							x	x	+						x	0											
CSL 3690																			x	0			x						
CSL 3691																							x	x					
CSL 3692																							x	x					
CSL 3699																x							x	x					
CSL 3700	S															x	x	0	x	0				x					
CSL 3707	U								x	x	+					x	x	0	x	0			x	x					
CSL 3709	F	x					x	0	x								x	0					x	x					
CSL 3721																x							x	x					
CSL 3724	S															x							x			x			
CSL 3725																	x	+					x	x		x			
CSL 3726	U								x	x	+												x	x		x			
CSL 3729		x					x	0								x													
CSL 3732	S															x													
CSL 3734	F		x	+			x	+								x	x	0											
CSL 3736																	x	+					x	x		x			
CSL 3741	U	x	x	0			x	0	x	x	+												x	x		x			
CSL 3742									x	x	0					x							x	x		x			
CSL 3743																x													
CSL 3744			x																				x	x					
CSL 3745									x								x	0					x	x					
CSL 3746									x							x													
CSL 3747			x	0												x	x	0	x	0			x						
CSL 3748			x													x	x	0	x	0									
CSL 3749	U	x	x						x	x	+						x	0					x	x					
CSL 3757		x															x	0					x	x					
CSL 3758	F	x	x	+			x	+									x	0					x	x					
CSL 3760																							x	x					
CSL 3765	F	x					x	0								x													
CSL 3768																							x	x					
CSL 3770	F	x					x	0								x													
CSL 3780	F	x					x	0								x													
CSL 3783	F	x	x	+			x	+															x	x					
CSL 3791	S																						x	x					
CSL 3793		x														x			x	0									
CSL 3794	U	x					x	0	x	x	+	x	+			x			x	0									
CSL 3796	U															x							x			x			
CSL 3800		x							x	x	+					x			x	0			x						
CSL 3801												x	0										x	x					
CSL 3802																x								x					
CSL 3803																x													
CSL 3804																							x	x		x			
CSL 3806	F, S	x	x	0			x	0								x													
CSL 3807	U	x	x	0					x			x	+			x			x	+									
CSL 3824									x														x			x			
CSL 3901									x							x					x	0							
CSL 3931																													
CSL 3950									x																				
CSL 3969																x													
CSL 4024																													
CSL 4162																x													
CSL 4209		x					x																						
CSL 4210	U						x			x		x	+			x	x		x	0									
CSL 4214		x					x			x		x	0				x		x	0									
CSL 4218							x		x	x		x	0				x		x										
CSL 4220										x						x	x		x										

LOCATION OF FROZEN SAMPLES COLLECTED FROM SEA LION EVENT

ACC #	DOMOIC ACID +	FECES							URINE							BLOOD							STOMACH						
		TMMC	Fran Van Dolah		Vera Trainer		Kathy Lefebvre		TMMC	Fran Van Dolah		Vera Trainer		Kathy Lefebvre		TMMC	Fran Van Dolah		Vera Trainer		Kathy Lefebvre		TMMC	Fran Van Dolah		Vera Trainer		Kathy Lefebvre	
			shipped	results	shipped	results	shipped	results		shipped	results	shipped	results	shipped	results		shipped	results	shipped	results	shipped	results		shipped	results	shipped	results	shipped	results
FETUS:																													
CSL 3699F																x	x		x	0			x						
CSL 3731F																													
CSL 3769F																													
CSL 3802F																													
CSL 3805																													
CSL 3809																													
CSL 3835F																													
LIVE:																													
CSL 3708																x	x	0						x	0				
CSL 3717																x													
CSL 3719																x	x	0											
CSL 3720																x			x	0									
CSL 3727																x			x	0									
CSL 3731																x	x	0											
CSL 3733																x	x	0											
CSL 3735																x			x	0									
CSL 3752																x	x	0											
CSL 3754																x													
CSL 3755																x	x	0											
CSL 3767																x	x	0	x	0									
CSL 3769																x													
CSL 3775																x			x	0									
CSL 3776																0													
CSL 3777																x													
CSL 3792																x													
CSL 3795																x			x	0									
CSL 3812																x													
CSL 3815																x													
CSL 3822																x													
CSL 3835																x													
CSL 4202			x													x	x		x	0									
CSL 4208	U	x					x		x	x		x	+			x	x		x	0									
CSL 4211		x					x		x							x	x		x	0									
CSL 4215	U						x		x	x		x	+			x	x		x										

ACC #	LIVER							KIDNEY						BRAIN				OTHER	CSF	TOOTH
	TMMC	Fran Van Dolah		Vera Trainer		Kathy Lefebvre		TMMC	Fran Van Dolah		Vera Trainer		Kathy Lefebvre	TMMC	Fran Van Dolah		Vera Trainer		Kathy Lefebvre			TMMC	AGE (years)
		shipped	results	shipped	results	shipped	results		shipped	results	shipped	results			shipped	results	shipped	results	shipped	results			
DECEASED:																							
NFS 123	x					x		x					x										
CSL 3690	x	x						x	x														13
CSL 3691	x	x						x	x	0													7
CSL 3692	x	x						x	x	0				x									9
CSL 3699																							9
CSL 3700	x	x				x		x	x				x										13
CSL 3707	x	x				x		x	x	0			x										6
CSL 3709	x	x				x		x	x				x										3.5
CSL 3721	x							x						x									11
CSL 3724	x	x						x	x	0												x	
CSL 3725	x					x		x					x										10
CSL 3726	x					x		x					x										8
CSL 3729						x							x									x	
CSL 3732																						x	11
CSL 3734	x							x															
CSL 3736	x					x		x															4
CSL 3741	x							x															0.5
CSL 3742																							7
CSL 3743						x		x					x		x								
CSL 3744	x							x															6
CSL 3746	x							x															
CSL 3747	x							x							x								12
CSL 3748	x							x														x	
CSL 3749	x							x															11
CSL 3757																							
CSL 3758								x							x								8
CSL 3760	x							x							x							x	
CSL 3765	x					x	0	x					x	0					x	0	muscle=0 (KL)		4
CSL 3768	x							x															
CSL 3770	x							x							x							x	7
CSL 3780	x							x															
CSL 3783															x								13
CSL 3791	x							x							x							x	12
CSL 3793	x							x							x							x	8
CSL 3794	x							x							x								10
CSL 3796	x							x							x								7
CSL 3800	x					x		x					x										6
CSL 3801	x							x															9
CSL 3802															x							x	
CSL 3803	x							x															9
CSL 3804	x							x							x								
CSL 3806						x	0															x	8
CSL 3807	x							x							x								9
CSL 3824	x							x							x				CSF	0		x	11
CSL 3901																					lg. int.=0 (KL)		
CSL 3931																							
CSL 3950	x							x															
CSL 3969																							
CSL 4024																							
CSL 4162	x														x								
CSL 4209	x							x							x							x	
CSL 4210	x							x							x							x	
CSL 4214	x							x							x							x	
CSL 4218	x							x							x						CSF=0 (VT)		
CSL 4220	x														x								

LOCATION OF FROZEN SAMPLES COLLECTED FROM SEA LION EVENT

ACC #	LIVER							KIDNEY							BRAIN					CSF
	TMMC	Fran Van Dolah		Vera Trainer		Kathy Lefebvre		TMMC	Fran Van Dolah		Vera Trainer		Kathy Lefebvre	TMMC	Fran Van Dolah		Vera Trainer		Kathy Lefebvre	TMMC
		shipped	results	shipped	results	shipped	results		shipped	results	shipped	results	shipped		shipped	results	shipped	results	shipped	
FETUS:																				
CSL 3699F	x	x						x	x											
CSL 3731F																				
CSL 3769F																				
CSL 3802F																				
CSL 3805																				
CSL 3809																				
CSL 3835F																				
LIVE:																				
CSL 3708																				
CSL 3717																				
CSL 3719																				
CSL 3720																				
CSL 3727																				
CSL 3731																				
CSL 3733																				
CSL 3735																				
CSL 3752																				
CSL 3754																				
CSL 3755																				
CSL 3767																				
CSL 3769																				
CSL 3775																				
CSL 3776																				
CSL 3777																				
CSL 3792																				
CSL 3795																				
CSL 3812																				
CSL 3815																				
CSL 3822																				
CSL 3835																				
CSL 4202																				
CSL 4208																				
CSL 4211																				
CSL 4215																				

CSF=0 (VT)